

Case Report

Hypopigmented Mycosis Fungoides: A Rare Variant

Anuj Sharma¹, Vinay Shanker², Gita Ram Tegta³, Renu Rattan⁴

¹Consultant Dermatologist, Dept of Dermatology, Regional Hospital Bilaspur, Himachal Pradesh-174001.

²Professor, Dept of Dermatology, MM Medical College and Hospital, Kumarhatti-Solan, Himachal Pradesh.

³Professor, Dept of Dermatology, Indira Gandhi Medical College, Shimla, Himachal Pradesh-171001.

⁴Consultant Dermatologist, Dept of Dermatology, Deen Dyal Upadhyay Hospital, Shimla.

Corresponding Author: Anuj Sharma

Received: 13/12/2016

Revised: 23/12/2016

Accepted: 27/12/2016

ABSTRACT

Mycosis fungoides (MF) is a cutaneous lymphoma of the T-cell lineage. Hypopigmented MF is a rare clinical variant of MF, described mainly in the dark skinned individuals. We, hereby illustrate a case of Hypopigmented MF in a 33 year old male, which was confirmed histologically and treated successfully with PUVA (Psoralen+UVA) therapy.

Key words: Mycosis fungoides, Hypopigmented, Lymphoma, Phototherapy.

INTRODUCTION

Mycosis fungoides (MF), the most common primary cutaneous T-cell lymphoma, is a neoplastic disease characterized by classical non-infiltrated lesions (patches), plaques, and tumor and erythrodermic stages. Several unusual clinicomorphologic variants have been observed, including pustular, bullous, hyperpigmented, purpuric, follicular, verrucous, and hypo pigmented forms. ^[1] Hypo pigmented MF is an under-recognized variant of MF, characterized by hypo pigmented patches, described mainly in the dark skinned individuals and children, especially Asians. It may clinically resemble other hypo pigmented dermatoses like early vitiligo, post inflammatory hypo pigmentation and patches of borderline leprosy. Diagnosis of early stage of MF is usually based on clinicopathologic correlation. ^[2] Both phototherapy and photo chemotherapy have been used effectively for the treatment of Hypopigmented MF. ^[3] The present report illustrates a case of hypo

pigmented MF in a 33-year old male, who was successfully treated with photochemotherapy.

CASE REPORT

A 33 year old male presented with 10 months history of creamish coloured lesions over his left leg and buttocks. There were no systemic complaints. Examination revealed, a few well defined, hypopigmented, plaques, varying in size from 2x3 cm to 5x3 cm over the gluteal region, lower back on the left side and right thigh (Figure1). The lesions were minimally indurated and subtle atrophy could be seen. Overlying sensations were normal. General physical and systemic examination was unremarkable. The clinical possibilities of borderline hansen's disease and hypo pigmented MF were kept.

The patient was subjected to baseline investigations (which were found to be normal), and biopsy for histopathology was done. Histopathology revealed moderately dense superficial perivascular,

patchy, lichenoid infiltrate of lymphocytes with mild epidermal spongiosis. The epidermis showed mild psoriasiform hyperplasia and infiltration by numerous small and large lymphocytes, several of which were aligned along the basal layer in a toy soldier pattern (Figure 2). There was no granuloma or any infiltrate around arrector pilorum muscles and nerves. Immunohistochemistry could not be done due to financial constraints. The final

diagnosis of Hypopigmented MF was made on the basis of clinicopathologic correlation.

The patient was started on photochemotherapy with Psoralen-UVA (PUVA), with three sessions per week. There was gradual decrease in induration and atrophy, and improvement in the colour of the lesion over next 3 months (Figure 3). The Patient was off PUVA after 6 months of treatment. The follow up till next 18 months after treatment didn't show any clinicopathologic evidence of relapse.

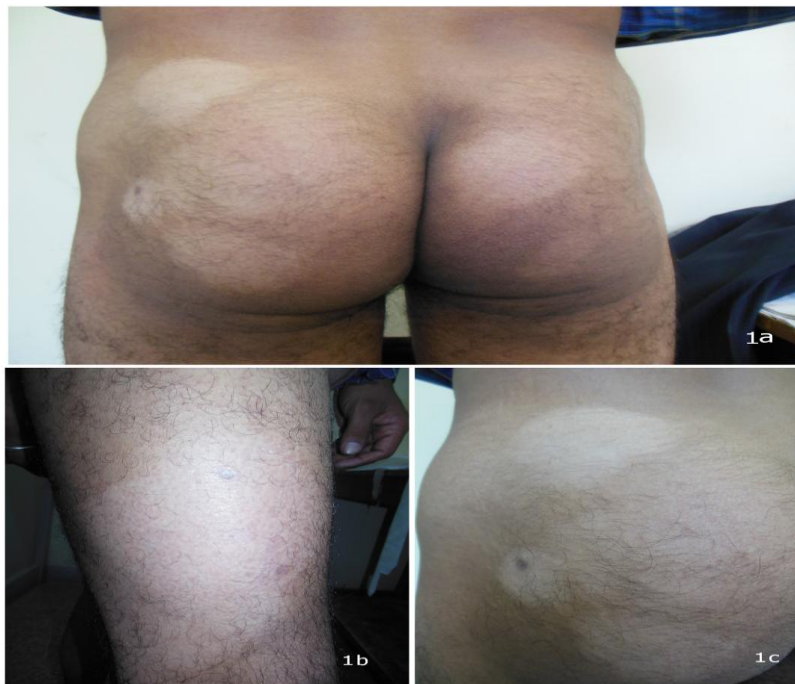

Figure 1: (1a)- Multiple hypopigmented patches over lower back and gluteal region variable in size, (1b)- hypopigmented patch on right thigh, (1c)- hypopigmented patches showing subtle atrophy and minimal induration.

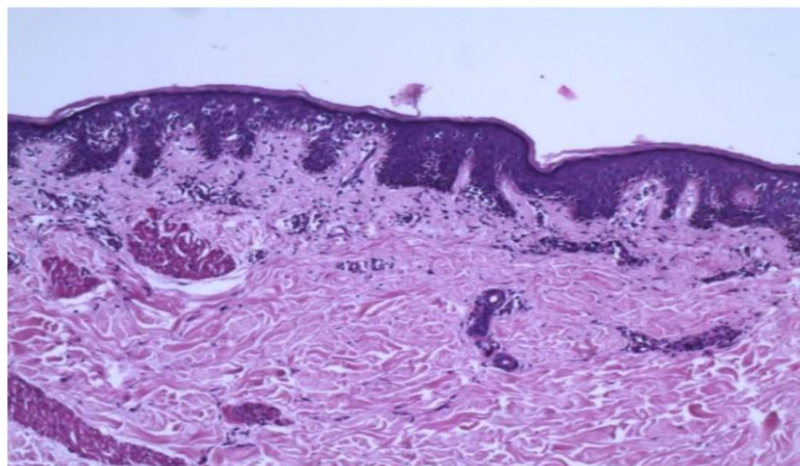


Figure 2:(H&E 100) Superficial perivascular, patchy, lichenoid infiltrate of lymphocytes with mild epidermal spongiosis and infiltration by numerous small and large lymphocytes, several of which were aligned along the basal layer in a toy soldier pattern.

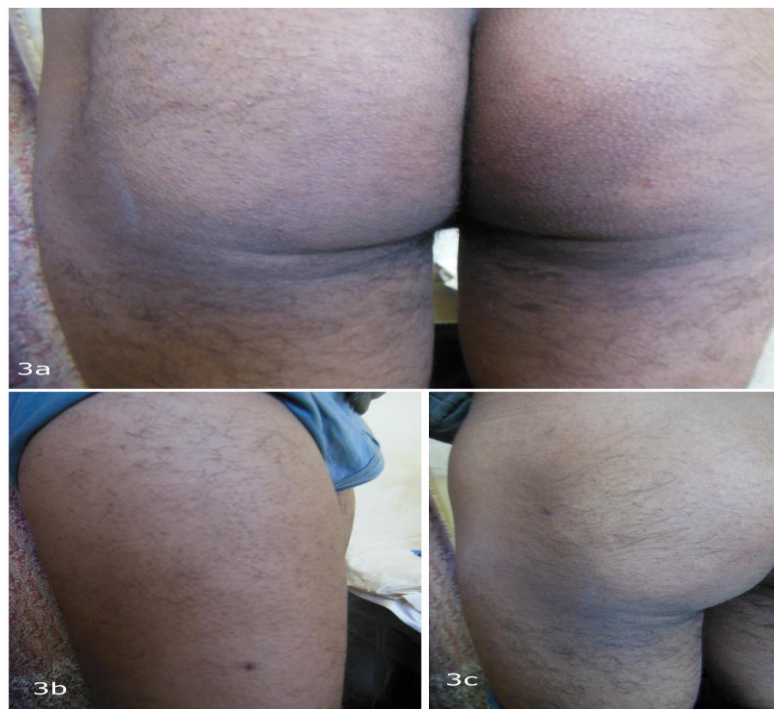

Figure 3: (3a) Significant improvement in hypopigmentation and atrophy over the lesions after 3 months of PUVA therapy, (3b) lesion on the right leg getting skin colored after the treatment, (3c) clearing of the lesions on left gluteal area.

DISCUSSION

The cutaneous T-cell lymphomas (CTCL) consist of a spectrum of non-Hodgkin's lymphomas that include mycosis fungoides (MF) and the Sezary syndrome (SS). MF is an epidermotropic form of CTCL in which a malignant clone of helper T lymphocytes invades the skin. [4] MF presenting with hypopigmented lesions is a rare clinical variant described almost exclusively in dark skinned individuals, first description being given by Ryan *et al* in 1973. Hypopigmented lesions can present as a sole manifestation of the disease or can be associated with erythematous patches, plaques or tumors. [5] Clinically, the hypopigmented patches are asymptomatic, not sharply circumscribed, and have slightly dry surface. Mild atrophy can be seen on close examination. Some of these patches may develop focal hyperpigmentation resulting in poikilodermatous changes in the center as the chronicity of infiltration increases. [2] This variant of MF can mimic some of the common diseases like atopic dermatitis, vitiligo, post inflammatory hypopigmentation, tinea versicolor, pityriasis alba, macular hypomelanosis of

the trunk and leprosy (Table 1). [6] The real frequency of hypopigmented MF is still unknown and probably underestimated. Moreover, the prolonged, non-progressive course of the disease makes the diagnosis difficult and delayed. [5]

Histopathology shows characteristic tropism of large lymphocytes for the dermoepidermal junction and unusually sparse dermal lymphocytic infiltrate, with features of melanin incontinence. Monoclonality of T lymphocytes can be detected with the help of T-cell receptor gene rearrangement studies. Unlike classical MF which shows CD4⁺ T cells on immunohistochemical analysis, hypopigmented variant predominantly shows CD 8⁺ cells within the epidermis. [1,2] A predominance of CD 8⁺ cells in neoplastic infiltrates is consistent with the hypothesis that hypopigmentation results from the cytotoxicity of suppressor lymphocytes towards melanocytes. [1,5]

Hypopigmentation could represent the extreme result of a protective immune response: neoplastic or reactive CD8⁺ T cells in cellular infiltrates guarantee an indolent disease with good prognosis, and

prevent transformation to a Th2-type immune response, which is associated with progression to malignancy. [1]

There are only a limited number of case reports/studies available in the literature. A review of various previous studies is being summarized here. [2,5,7-9] (Table 2)

Table 1; Differential diagnosis of hypopigmented lesions and exclusion clues [6]

DD	Exclusion criteria
Tinea versicolor	Hypopigmented scaly macules distributed over upper truncal area, scaling accentuates on rubbing. Microscopically: sappegetti and meat ball appearance of <i>Malasezia furfur</i> can be seen.
Macular hypomelanosis of trunk	Clinically it affects the trunk only, shows no digitate pattern and may show confluence in center. Microscopically: intrafollicular bacteria (<i>Propionibacterium acnes</i>) with perifollicular infiltrate.
Indeterminate leprosy	Widespread lesions only in clinical setting of LL Other features of LL should be obvious.
Postinflammatory hypopigmentation	Precede by well defined inflammatory disorders such as psoriasis or pityriasis rosea
Pityriasis alba	Affects mainly exposed areas(face, forearms)and is usually associated with atopic dermatitis It is more common in children(rare in adults)
Hypopigmented MF	Lesions are in bathing suit area; lesion size > 6mm,with no digitate forma; atrophy, poikiloderma, erythema, scaling and pruritus is present in some cases. Pathologically: epidermotropism, atypical lymphocytes; more dense superficial perivascular infiltrate.

Abbreviations: DD-Differential diagnosis, LL-Lepromatous leprosy.

Table 2: A comparative review of the clinicopathologic findings in various past studies on hypopigmented mycosis fungoides

	Khopkar et al [2]	Tan et al [7]	Wain et a [8]	Lambroja et al [9]	Ardigo et al [5]
No of cases	15	8	8	7	7
Males	10	6	4	2	4
Females	5	2	4	5	3
Dark skin types	15	8	7	7	7
Fair skin types	0	0	1	0	0
Average duration of lesions prior to diagnosis(years)	3.83	4.5	6	3.5	3.4
Most common initial diagnosis	Hansen's disease (10 cases), vitiligo (1case), mycosis fungoides (4 cases)	Eczema(5cases),Tinea versicolor (2 cases), Vitiligo (1 case)	Eczema (2cases), Psoriasis(2cases), Mycosis fungoides (2 cases)		
Tagging of lymphocytes along basement membrane	15			7	
Pautrier's micro abscess	6/15 (40%)			2/7(28.5%)	
Diffuse lichenoid dermal infiltrate	2/15 (13.33%)			2/7(28.5%)	
Superficial perivascular and interstitial infiltrate	2/15 (13.33%)			1/7(14.28%)	
Superficial perivascular infiltrate	11/15 (73.33%)			4/7(57.14%)	
Immunohistochemistry done in	10/15		7/8		7/7
CD8 positive epidermotropism	8/10 (80%)		4/7(57.14%)		3
CD4 positive epidermotropism	5/10 (50 %)		5/7(71.4%)		4
CD4 and CD8 negative	2/10 (20%)		1/7(14.28%)		Not done
CD56 positive	Not done		1/7(14.28%)		3

The present case also showed dense superficial perivascular, lichenoid infiltrate of lymphocytes, along with tagging of small and large lymphocytes along the basement membrane in a toy soldier pattern.

The treatment of hypopigmented MF consists of topical nitrogen mustard, topical mechlorethamine, topical carmustine and

photo/photo chemotherapy. Photo chemotherapy in the form of PUVA is a safe, effective, and well tolerated first line therapy. The evidence for phototherapy in the form of narrow-band UVB (NB-UVB) is less robust but may be considered at least as effective. For inducing remission, three treatment sessions per week of PUVA

phototherapy or three sessions per week of NB-UVB phototherapy may be advised till the patient achieves complete remission. In cases of relapse, patients may be started again on PUVA monotherapy or PUVA may be combined with adjuvants like methotrexate and interferon. Maintenance therapy should not be employed for PUVA routinely and may be reserved for patients who experience an early relapse after an initial course of phototherapy. Bath-water PUVA may be tried as an alternative to oral PUVA in case the latter cannot be administered as the former may show similar efficacy. Given that hypopigmented MF is a highly recurrent disease, aggressive treatment is contraindicated. [1,3,10] Our patient also responded well to PUVA both clinically and histologically. The follow up till 18 months also did not show any evidence of relapse.

Since it may mimic several other hypopigmented skin disorders clinically, a clinicopathologic correlation is essential to make accurate diagnosis. Though, it seems to have a favourable and indolent course, long term survival data are not available. Recurrences can occur a few months or even many years after total remission and therefore follow up is mandatory.

REFERENCES

1. Furlan FC, Sanches JA. Hypo pigmented mycosis fungoides: a review of its clinical features and pathophysiology. *A Bras Dermatol*. 2013; 88 (6):954-60.
2. Khopkar U, Doshi BR, Dongre AM, *et al*. A study of clinicopathologic profile of 15 cases of hypopigmented mycosis fungoides. *Indian J Dermatol Venereol Leprol* 2011; 77(2):167-73.
3. Dogra S, Mahajan R. Phototherapy for mycosis fungoides. *Indian J Dermatol Venereol Leprol* 2015; 81(2):124-35.
4. Herrmann JJ, Roenigk HH Jr, Hurria A, *et al*. Treatment of mycosis fungoides with photo chemotherapy (PUVA): long-term follow-up. *J Am Acad Dermatol*. 1995; 33:234-42.
5. Ardigó M, Borroni G, Muscardin L, *et al*. Hypo pigmented mycosis fungoides in Caucasian patients: a clinicopathologic study of 7 cases. *J Am Acad Dermatol* 2003; 49(2):264-70.
6. El-Darouti MA, Fawzy MM, Hegazy RA, *et al*. Hypopigmented parapsoriasis en plaque, a new, overlooked member of the parapsoriasis family: a report of 34 patients and a 7-year experience. *J Am Acad Dermatol* 2012; 67(6):1182-8.
7. Tan E, Tay YK, Giam YC. Profile and outcome of childhood mycosis fungoides in Singapore. *Pediatr Dermatol*. 2000; 17(5):352-6.
8. Wain EM, Orchard GE, Whittaker SJ, *et al*. Outcome in 34 patients with juvenile-onset mycosis fungoides: a clinical, immunophenotypic, and molecular study. *Cancer*. 2003; 98(10): 2282-90.
9. Lambroza E, Cohen SR, Phelps R, *et al*. Hypopigmented variant of mycosis fungoides: demography, histopathology, and treatment of seven cases. *J Am Acad Dermatol*. 1995; 32(6):987-93.
10. Akaraphanth R, Douglass MC, Lim HW. Hypopigmented mycosis fungoides: treatment and a 6(1/2)-year follow-up of 9 patients. *J Am Acad Dermatol* 2000; 42: 33-9.

How to cite this article: Sharma A, Shanker V, Tegta GR et al. Hypopigmented mycosis fungoides: a rare variant. *Int J Health Sci Res*. 2017; 7(1):330-334.
