

Case Report

Prosthetic Rehabilitation of an Enucleated Eye Defect with Custom Made Ocular Prosthesis: A Case Report

Sabzar Abdullah^{1*}, Talib Amin Naqash^{2**}, Mehbooba Khazir^{3***}, Geeta Rajput^{4*}, Pankaj Kharade^{1*}

¹Assistant Professor, ²Registrar, ³Resident, ⁴Professor,

^{*}Department of Prosthodontics, ZA Dental College, AMU, Aligarh.

^{**}Department of Prosthodontics, Government Dental College & Hospital, Srinagar.

^{***}Government Dental College and Hospital Srinagar.

Corresponding Author: Sabzar Abdullah

Received: 19/10/2016

Revised: 11/11/2016

Accepted: 08/12/2016

ABSTRACT

Facial disfigurement on account of loss of an eye results in significant psychological and social consequences in the patient. A prosthetic eye can help improve the appearance of patient who has lost an eye to injury or disease. This case report presents a palliative treatment for a patient with an enucleated eye by fabricating a custom ocular prosthesis which improved his psychological, physical, social, functional, emotional and spiritual needs.

Keywords: Enucleation, Evisceration, Orbital exenteration, Ocular prosthesis.

INTRODUCTION

An ocular prosthesis, artificial eye or glass eye is a type of craniofacial prosthesis that replaces an absent natural eye. Surgical removal of this organ may be indicated in cases of a severe trauma; congenital abnormality; or disease such as an infection, a tumor or untreatable painful glaucoma either by enucleation, evisceration, or exenteration. [1,2]

Evisceration is the removal of the contents of the eye but leaving the outer layer of the eyeball, or sclera, intact. This is performed by an eye surgeon in the case of infections, severe pain or problems inside the eye if vision is already lost. This should not be used for malignant tumors, or cancer. [3]

Enucleation is the removal of the eye, including the globe, but leaving the rest of the orbital (eye socket) contents in place. Examples of the orbital contents that are left

in place include the bones of the orbit, extra ocular muscles, fat and conjunctiva. Enucleations are done for infections or malignant cancers that are completely within the globe of the eye. This can be done for cancers such as retinoblastoma or other cancers in which vision is already gone. [3,4]

Orbital exenteration is the removal of all eye socket contents, including muscles, the lacrimal gland system, and the optic nerve as well as varying parts of the bone of the orbit. The eyelid can be spared, depending on the extent of the tumor. This is done for large cancers of the eye, the skin over the eye or eyelid or cancers from other areas that extend into the eye socket, including the paranasal sinuses, maxilla, skin or a part of the eye. [3]

An ocular prosthesis can be either readymade (stock) or custom-made. [5] Stock prosthesis comes in standard sizes,

shapes, and colors. [5] They can be used for interim or postoperative purposes. [5] Custom eyes have several advantages including better mobility, even distribution of pressure due to equal movement thereby reducing the incidence of ulceration, improved fit, comfort, and adaptation, improved facial contours, and enhanced esthetics gained from the control over the size of the iris, pupil, and color of the iris and sclera. [5]

CASE REPORT

A thirteen year old male patient reported to the Department of Prosthodontics, Government Dental College and Hospital, Srinagar with chief complaint of missing left eye (Figure 1). Examination revealed enucleated left eye socket. Examination of the socket revealed healthy conjunctiva lining and absence of infection. History revealed surgical removal of the eye ball after a traumatic injury. Treatment plan included fabrication of custom made ocular prosthesis.

Patient Evaluation

Following observations were made during examination of the patient: [5,6]

- Relationship of the palpebral fissures in an open and closed position.
- Evaluation of the muscular control of the palpebrae.
- Internal anatomy of the socket in a resting position and during full excursive movements of the eye musculature.
- Mobility of the posterior wall of the defect during the movement of the intact eye.

Ocular Prosthesis Fabrication

Impression making (Figure 2): An impression of the socket was made with light body rubber base additional silicone impression material (Aquasil, Densply, India). An impression tray was fabricated from the hard base plate wax by warming it over a flame and adapting it to the contour of the area around the eye. During the secondary impression, the head was moved

back to the vertical position and the patient was directed to move her eyes up and down. This will facilitate the flow of the impression material to all aspects of the socket. Patient was asked to look at a distant spot at eye level with her gaze maintained in a forward direction.

After the material was set, cheek, nose and eyebrow regions were massaged to break the seal. While the patient gazed upwards, the cheek was pulled down and the inferior portion of the impression rotated out of the socket. Impression was checked for accuracy and excess material was trimmed.

A two-piece Type III dental stone cast (Kalabhai Dental, India) was poured to immerse the lower part of the impression. After the stone had set, the separating medium was applied on the surface. A second layer was then poured. Markings were made on all four sides of the cast for proper reorientation (Figure 3). The space left in the mold was filled with molten base plate wax to fabricate a scleral wax pattern. Wax pattern was finished and polished; try in was done (Figure 4).

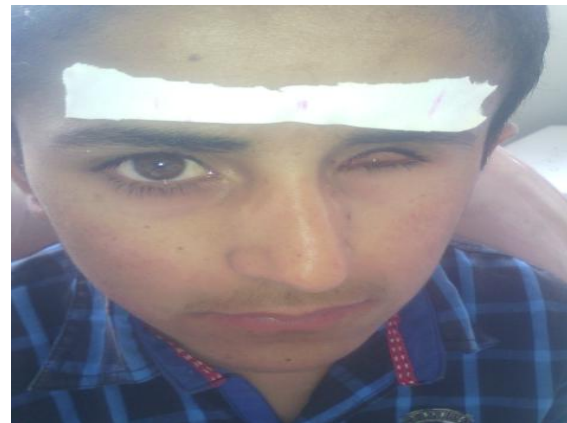

Figure 1: Pre operative view showing enucleated socket




Figure 2: Impression

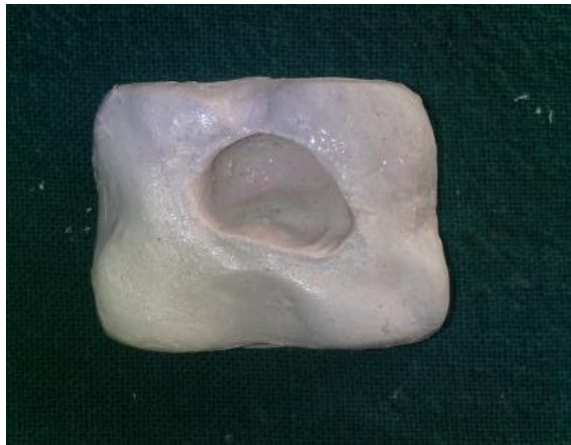

Figure 3: Cast Fabrication

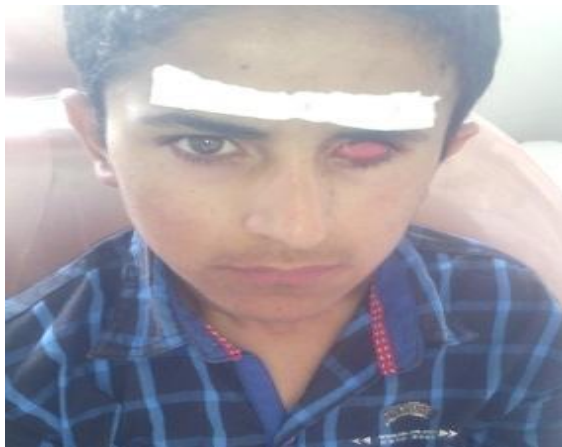

Figure 4: trial in of the scleral wax pattern

The position of contralateral eye's iris was used as a guide, to mark expected position of iris on a wax pattern. Prefabricated eye shell matching the patient's natural iris in color and size was selected. Iris portion of this shell was separated by trimming away the scleral portion with the help of a bur. Wax was scooped out from the area for iris marked on the wax pattern and the iris disc was placed in that position. Care was taken to blend the surface of the iris disc with the rest of the scleral wax pattern.

Trial: After the placement of iris disc, the wax pattern was highly polished and tried in the socket. Position, gaze and esthetics of the iris were established by comparing with the natural eye.

Flasking and curing (Figure 5): Wax pattern with iris disc was flaked in a crown flask to create a split mold. Dewaxing was done and the iris disc was replaced in its position and secured with the help of glue.

Tooth moulding heat cured acrylic (Tooth moulding powder, DPI, India) of appropriate shade was mixed and packed into the mold. Processing was done using short curing cycle. After processing, prosthesis was recovered. It was finished and polished to a high shine, disinfected and stored in water for 24 hrs before insertion.

Insertion: Prosthesis was inserted into the socket, and checked for any areas requiring adjustment. Esthetics and comfort of the patient were evaluated. The patient was educated to insert and remove the prosthesis. Ophthalmic lubricant was advised for lubrication.



Figure 5: Lab procedure for the fabrication of ocular prosthesis



Figure 6: Patient with custom ocular prosthesis

DISCUSSION

Ocular prosthesis is an artificial replacement of the bulb of the eye. [5] Multidisciplinary management and a team approach are essential in providing accurate and effective rehabilitation and follow-up

care for the patient. [5,7] Therefore, combined efforts of the ophthalmologist, oral and maxillofacial surgeon, plastic surgeon, and the maxillofacial prosthodontist are essential to restore the patient's quality of life. [5]

A properly fitted and accepted custom ocular prosthesis has following characteristics: [8]

- Retains the shape of the defect socket.
- Prevents collapse or loss of the shape of the lids.
- Provides proper muscular action of the lids.
- Prevents accumulation of fluid in the cavity.
- Maintains palpebral opening similar to the natural eye.
- Mimics the coloration and properties of the natural eye.
- Has gaze similar to the natural eye.

Although the prosthetic rehabilitation may be enhanced with the use of implants, which can coordinate with the movements of the natural eye, they are not always possible or feasible. [9]

The use of custom-made ocular prosthesis has been a boon to the patients who cannot afford the implant placement. [5] Esthetic and functional results of the prosthesis was far better than the stock ocular prosthesis (Figure 6). Although the patient cannot see with the ocular prosthesis how-ever, it has definitely restored patient's self-esteem and allowed him to confidently face the world. [5] The use of ocular prosthesis has changed the patient's social life at a significant level and improved the confidence too. [10]

REFERENCES

1. Goel BS, Kumar D. Evaluation of ocular prosthesis. J All India Ophthalmol Soc. 1969; 17:266-9.
2. Nath K, Gogi R. The orbit. Indian J Ophthalmol. 1976; 24:1-14.
3. <http://www.headandneckcancerguide.org/adults/cancer-diagnosis-treatments/surgery-and-rehabilitation/cancer-removal-surgeries/evisceration-enucleation-and-exenteration>.
4. Custer PL. Enucleation: Past, present, and future. Ophthalmic Plast Reconstr Surg 2000;16:316
5. Prachi Thakkar, JR Patel, Rajesh Sethuraman, Narendra Nirmal. Custom Ocular Prosthesis: A Palliative Approach. Indian J Palliat Care. 2012 Jan-Apr; 18(1): 78-83.
6. Goel BS, Kumar D. Evaluation of ocular prosthesis. J All India Ophthalmol Soc. 1969; 17:266-9.
7. Artopoulou I, Montgomery P, Wesly P, Lemon J. Digital imaging in the fabrication of ocular prosthesis. J Prosthet Dent 2006; 95:327-30.
8. Haug SP, Andres CJ. Fabrication of custom ocular prosthesis. In: Taylor TD, editor. Clinical maxillofacial prosthetics. 1st ed. Chicago: Quintessence Publishing; 2000. pp. 265-76.
9. Doshi PJ, Aruna B. Prosthetic management of patient with ocular defect. J Indian Prosthodont Soc 2005; 5:37-38.
10. Nafij Bin Jamayet, Theerathavaj Srithavaj, Mohammad Khursheed Alam. A Complete Procedure of Ocular Prosthesis: A Case Report. International Medical Journal 2013; 20:6,729-730.

How to cite this article: Abdullah S, Naqash TA, Khazir M et al. Prosthetic rehabilitation of an enucleated eye defect with custom made ocular prosthesis: a case report. Int J Health Sci Res. 2017; 7(1):297-300.
