

Original Research Article

Cadaveric Study on the Length and Diameter of the Hepatic Ducts

Sushma Khatiwada ¹, Budhi Nath Adhikari ², Shuvechha Shakya ³

Name of the Institution (research) = Kathmandu Medical Hospital (KMC), Duwakot, Bhaktapur, Nepal.

¹Lecturer of Clinical Anatomy at Chitwan Medical College, Kailashnagar, Chitwan, Nepal,

²Consultant Plastic Surgeon, ³Lecturer of Clinical Anatomy at Chitwan Medical College, Bharatpur-10, Chitwan, Nepal

Corresponding Author: Sushma Khatiwada

ABSTRACT

Introduction: The biliary system develops as a complex process that can lead to several anatomic variations; its thorough knowledge is essential in radiologic, endoscopic and surgical approaches to the biliary system. The right hepatic duct (RHD) is shorter, wider and more vertical than the left hepatic duct (LHD). This study aims to accurately measure the length and diameter of the right and left hepatic ducts as well as look for any existing correlation between them.

Methods: This observational study was commenced in July 2013 and completed in June 2014 at the Department of Anatomy Kathmandu Medical College Teaching Hospital, Kathmandu, Nepal after taking Ethical clearance from the hospital ethical board. 32 Livers were dissected; the ducts were traced, colored, photographed and measured. Previously operated, diseased and injured liver were excluded from the study.

Results: The length of left hepatic duct was found to range from 18.12 to 24.14 mm with a mean of 20.77 mm while the length of right hepatic duct was found to range from 8.95 to 12.32 mm with a mean of 10.48 mm. The mean of external diameter of right hepatic duct obtained from the present study was 3.37 mm and the mean internal diameter of right hepatic duct was 2.1 mm. The mean of external and internal diameters of left hepatic duct was found to be 2.54 mm and 1.37 mm respectively.

There is a strong correlation between internal diameter of RHD with external diameter of RHD (Pearson correlation coefficient value of 0.85 with p-value <0.0001); length of LHD with length of RHD (p-value =0.03); internal diameter of LHD with length of RHD (p=0.03) and internal diameter of LHD with external diameter of LHD (p-value=<0.0001).

Conclusion: The length of left and right hepatic ducts were found to range from 18.12 to 24.14 mm (mean 20.77 mm) and from 8.95 to 12.32 mm (mean 10.48 mm) respectively. The mean of external and internal diameters of right hepatic duct were 3.37 mm and 2.1 mm respectively. Similarly, the mean of external and internal diameters of left hepatic duct were found to be 2.54 mm and 1.37 mm respectively.

A strong correlation exists between internal and external diameters of RHD, length of LHD and RHD, the internal diameter of LHD and length of RHD as well as the internal and external diameters of LHD.

Key words: *Intrahepatic biliary radicals, Bile ducts, RHD and LHD, Right and left hepatic ducts, cadaveric liver*

INTRODUCTION

Anatomical variability is the rule rather than the exception in the biliary system. [1] James H. Foster [2] has correctly said about the anatomy of the liver – "The liver, because of its unforgiving and extraordinarily difficult surgical anatomy and complex physiology will remain the Mount Everest of organs for surgeons. It is no place for the fainthearted, perhaps, but it will continue to challenge the bright and the bold."

Accurate knowledge of the length and caliber of the hepatic ducts are essential for management of hilar carcinoma, negotiation of scope for endoscopic interventions in the liver and during liver lobe resection and reimplantation for split liver transplantation. [3]

The right hepatic duct is formed by the union of anterior and posterior sectoral ducts whereas the left hepatic duct forms by the union of medial and lateral segmental ducts. The right hepatic duct is short and joins the left hepatic duct to constitute the confluence lying in front of the right portal vein and forming the common hepatic duct. [4]

The length of the right and left hepatic ducts is variable and usually measures up to 3 - 4 mm in diameter. The RHD, however, is shorter, wider and more vertical than the LHD.

We aim to accurately measure the length and diameter of typical hepatic ducts (type A in Blumgart's classification) in preserved cadaveric specimens of 32 Nepalese livers in an attempt to provide local references for interventional radiologists and surgeons working in the intrahepatic region.

METHODS

An Observational study was conducted from July 2013 to June 2014 in the Department of Anatomy, Kathmandu Medical College Teaching Hospital by taking 32 human cadaveric liver while previously operated, diseased and injured liver were excluded. All the livers were

dissected; duct traced, colored, photographed and measured using the same digital Vernier calipers accurate up to 0.01 mm.



Figure 1: Intrahepatic biliary apparatus of the liver (coloured)

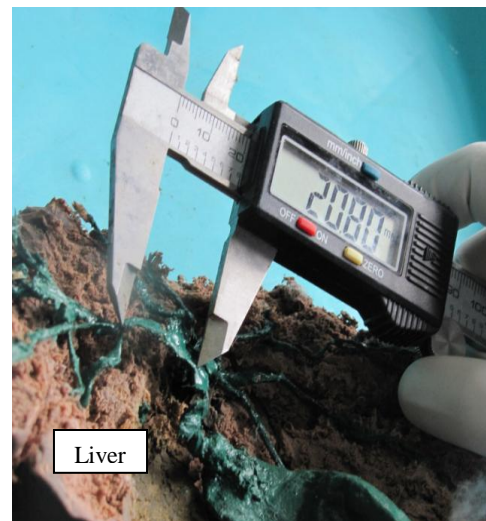


Figure 2: Measurement of intrahepatic bile duct

Structured proforma was used for data collection. Statistical analysis was performed by using the program SPSS Ver. 17. Percentage was computed for frequency of confluence of right and left hepatic duct. Charts were used whenever necessary. Mean and minimum and maximum values of length, external diameter, and internal diameter of right and left hepatic duct were obtained. The results were evaluated by using Pearson correlation test. Statistical significance was considered at p values <0.05.

Study approval was obtained from The Ethics & Research Committee of Kathmandu Medical College and Teaching Hospital. Permission was taken from the Department of Anatomy for the collection of data.

RESULT

The length and diameter of the hepatic ducts are tabulated in the table 1 below.

Pearson correlation coefficient was then calculated for the variables as shown in the table 2 below. Greater than 0.05 of p

value shows that there is no association between the variables.

Table1. Mean value of right and left hepatic duct before division

Description	Mean (mm)	Minimum	Maximum
Length of RHD before division	10.48	8.95	12.32
External Diameter RHD before division	3.37	2.08	3.98
Internal Diameter RHD before division	2.1	1.1	3.01
Length of LHD before division	20.77	18.12	24.13
External Diameter LHD before division	2.54	2.2	3.1
Internal Diameter LHD before division	1.37	0.95	2.27

Table2. Testing of Association between variables under study: Correlation Matrix

Description		Length RHD	External Diameter RHD	Internal Diameter RHD	Length LHD	External Diameter LHD	Internal Diameter LHD
Length RHD							
Ext Diameter RHD	r	-0.22					
	p	0.22					
Internal Diameter RHD	r	-0.04	0.78				
	p	0.85	<.0001				
Length LHD	r	-0.39	0.34	0.04			
	p	0.03	0.06	0.84			
External Diameter LHD	r	0.20	0.02	0.26	-0.05		
	p	0.28	0.90	0.15	0.77		
Internal Diameter LHD	r	0.39	-0.04	0.29	-0.33	0.80	
	p	0.03	0.84	0.11	0.07	<.0001	

As shown in table 3 below, there is a strong correlation between internal diameter of RHD with external diameter of RHD having Pearson correlation coefficient value of 0.85 with p-value <0.0001. Likewise there is an association between the length of LHD and the length of RHD (p-value =0.03); internal diameter of LHD and the length of RHD (p=0.03) and the internal diameter of LHD and external diameter of LHD (p-value=<0.0001). Apart from these, there is no association between the variables.

Table3. Correlation coefficient and p value of different variables

Variable 1	Variable 2	r (Pearson correlation coefficient)	p value
Internal Diameter RHD	Ext Diameter RHD	0.85	0
Length LHD	Length RHD	-0.39	0.03
Internal Diameter LHD	Length RHD	0.39	0.03
Internal Diameter LHD	External Diameter LHD	0.8	0

Figure 1 shows positive correlation [Pearson correlation coefficient (r) value is 0.85 with p-value <0.0001] between the external diameter of right hepatic duct and internal diameter of right hepatic duct.

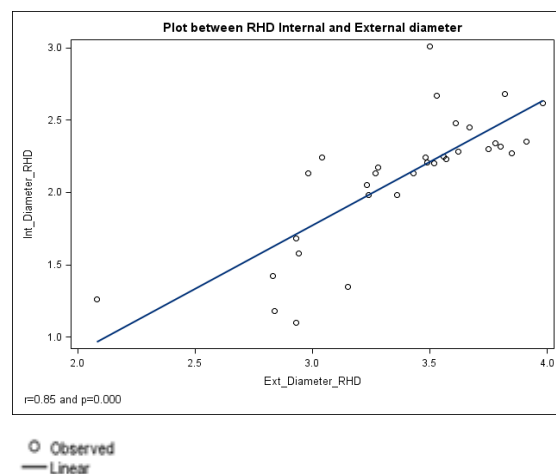


Figure 1: Correlation between external diameter and internal diameter of right duct

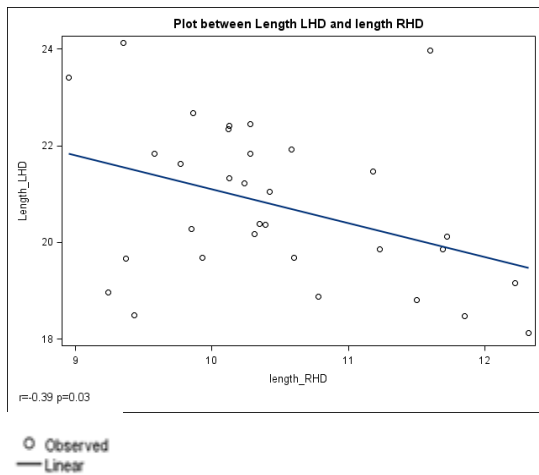


Figure 2: Correlation between length of left and right hepatic ducts

The scatter plot in figure 2 shows negative correlation [Pearson correlation coefficient (r) value is -0.39 with p-value <0.003] between the length of right hepatic duct and the length of left hepatic duct.

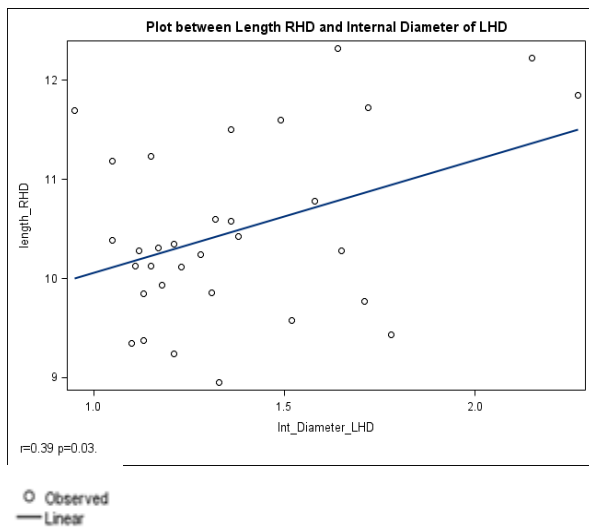


Figure 3: Correlation between length of right hepatic duct and internal diameter of left hepatic duct

Figure 3 shows positive correlation [Pearson correlation coefficient (r) value is 0.39 with p-value <0.003] between the internal diameter of left hepatic duct and length of right hepatic duct.

Figure 4 shows positive correlation [Pearson correlation coefficient (r) value is 0.85 with p-value <0.0001] between the internal diameter of right hepatic duct and external diameter of left hepatic duct.

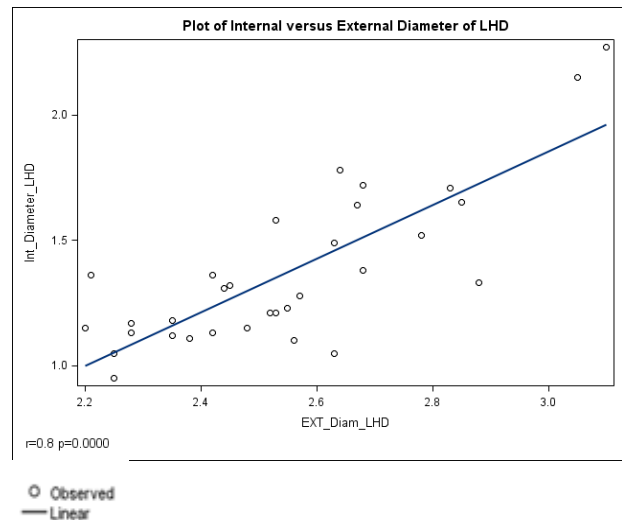


Figure 4: Correlation between external diameter and internal diameter of right hepatic duct

CONCLUSION

The length of left hepatic duct was found to range from 18.12 to 24.14 mm with a mean of 20.77 mm while the length of right hepatic duct was found to range from 8.95 to 12.32 mm with a mean of 10.48 mm.

The mean external diameter of right hepatic duct obtained from the present study was 3.37 mm and the mean internal diameter of right hepatic duct was 2.1 mm. The mean of external and internal diameters of left hepatic duct were 2.54 mm and 1.37 mm respectively.

There is a strong correlation between internal diameter of RHD and external diameter of RHD; length of LHD and length of RHD; internal diameter of LHD and length of RHD; & internal diameter of LHD and external diameter of LHD.

DISCUSSION

The left hepatic duct is 2.5 cm long, from 2 to 5 cm, depending on the size of the posterior margin of the quadrate lobe. The normal right duct is short and vertical and 1 cm in length, from 0.5 to 2.5 cm. [5]

Choi et al have found the length of 1st order branch (RHD) in typical pattern to range from 2.4 to 30 (mean, 12.8) mm; and in 34% it was less than a cm. [6]

The length of true RHD averaged 9 mm in the study by Healey. [7]

In the study by Deka et al, RHD length ranged from 1.2 to 33 mm, with 56 % of the study population with measurable RHD having a length of <10 mm. [8]

Ayuso et al have predicted difficult transplantation if the RHD is less than 1 cm in length. [9]

The right and left hepatic ducts usually measures up to 3 - 4 mm in diameter.

Eftekhari-Vaghefi et al from Iran have studied the diameters of the RHD, LHD and CHD; and found the average diameters to be 8.63 mm (SD 1.92), 6.61 mm (SD 1.58) and 8.91 mm (SD 1.93) respectively. [10] Kim et al have found mean maximal and mid-portion diameters of the common hepatic duct to be 6.1 mm (SD 1.8) and 5.3 (SD 1.6) in 8194 normal Korean cholangiograms which is lower than the Iranian study. He has suggested that the normal diameter of biliary tract may be different for the eastern and western populations and found that biliary anomalies, in contrast to pancreatic anomalies, to be more common in Korea and Japan as compared to the western countries. [11]

The larger intrahepatic ducts, before forming the right and left hepatic ducts are 1 to 1.5 mm in diameter. [12]

The values may be little higher for ERCP and cholangiograms because of magnification of the cholangiograms and also from ductal distension from contrast injection. [13]

The measurement of the hepatic duct length varies even for different approaches of MRC. [14]

Neuhaus found that the length of the LHD varies from 1 - 5 cm whereas the RHD rarely measures >1 cm. [15]

Coulaud [16] in 1999 published a new book titled "Tell me more about liver anatomy" and briefly mentioned the length of the hepatic duct as follows: the right hepatic duct is short (range 1–24 mm; mean = 9.005 mm, n = 107) and missing in 46.72 % of the cases in which the separate right lateral and right paramedian branches are

replaced; the left hepatic duct length is 13.47 ± 1.67 mm when the right hepatic duct is single and 10.89 ± 1.92 mm when the right hepatic duct is duplicated.

Limitations of our study are as follows:

1. This observed pattern of distribution in the present study may be attributed to less number of cases, a different population group studied or that smaller friable ducts may have been damaged in the preserved cadaveric livers.
2. Due to the use of preserved cadaveric liver, male and female comparison of ductal pattern as well as ductal pattern according to certain age was not possible.

SUMMARY

Study of the intrahepatic biliary ducts can be performed by various ways. In this study, 32 cadaveric livers were dissected, colored and measurements were done. We went further to check for any significant correlation between the measured parameters.

The mean length of RHD and LHD were 20.77 and 10.48 mm respectively while the mean external and internal diameters of the right and left hepatic ducts were 3.37/2.1 mm and 2.54/1.37 respectively. Negative correlation was found between the lengths of RHD and LHD while positive correlation exists between internal/external diameters of RHD and LHD as well as between internal diameters of LHD with external diameter of RHD.

Our study may provide impetus for better future structured studies to better delineate measurements of the intrahepatic biliary tree.

REFERENCES

1. Marcos A, Ham JM, Fisher RA, Olzinski AT, Posner MP. Surgical Management of Anatomical Variations of the Right Lobe in Living Donor Liver Transplantation. *Ann Surg.* 2000; 231(6):824–31.
2. Skandalakis JE, Branum GD; Colborn GL, Mirilas PS, Weidman TA, Skandalakis LJ et al. In: Skandalakis JE, editor-in-chief. *Skandalakis' Surgical Anatomy: The Embryologic and Anatomic Basis of Modern Surgery - 2 Volumes* [Internet]. New York: The McGraw-Hill Companies; 2006.

3. Vakili K, Pomfret E. Biliary anatomy and embryology. *Surg Clin N Am.* 2008; 88:1159-74.
4. Blumgart LH and Hann LE. Surgical and radiologic anatomy of the liver, biliary tract, and pancreas. In: Jarnagin WR, editor-in-chief. *Blumgart's Surgery of the Liver, Biliary Tract, and Pancreas* [Internet]. 5th ed. Philadelphia: Elsevier Saunders; 2012.
5. Castiang D. Surgical anatomy of the biliary tract. *HPB.* 2008; 10:72-6.
6. Choi JW, Kim TK, Kim KW, Kim AY, Kim PN, Ha HK et al. Anatomic Variation in Intrahepatic Bile Ducts: an Analysis of Intraoperative Cholangiograms in 300 Consecutive Donors for Living Donor Liver Transplantation. *Korean J Radiol.* 2003; 4:85-90.
7. Healey JE Jr, Schroy PC. Anatomy of the biliary ducts within the human liver: analysis of the prevailing pattern of branchings and the major variations of the biliary ducts. *Arch Surg.* 1953; 66:599-616.
8. Deka P, Islam M, Jindal D, Kumar N, Arora A, Negi SS et al. An analysis of biliary anatomy according to different classification systems. *Indian J Gastroenterol.* 2014 Jan-Feb; 33(1):23–30.
9. Ayuso JR, Ayuso C, Bombuy E, De Juan C, Llovet JM, De Caralt TM et al. Preoperative evaluation of biliary anatomy in adult live liver donors with volumetric mangafodipir trisodium enhanced magnetic resonance cholangiography. *Liver Transpl.* 2004; 10:1391-7.
10. Eftekhari-Vaghefi SH, Shams-Ara A, Jamalizade M. A Study of the anatomic Variations in Extrahepatic Bile Ducts in 50 Adults referred to Kerman Forensic Medicine Organization. *Anat Sci J.* 2013; 10(1):57-62.
11. Kim HJ, Kim MH, Lee SK, Seo DW, Kim YT, Lee DK et al. Normal structure, variations, and anomalies of the pancreaticobiliary ducts of Koreans: a nationwide cooperative prospective study. *Gastrointest Endosc.* 2002; 55:889-96.
12. Suchy FJ. Anatomy, Histology, Embryology, Developmental Anomalies, and Pediatric Disorders of the Biliary Tract. In: Feldman M, Friedman LS, Brandt LJ, editors. *Sleisenger and Fordtran's Gastrointestinal and Liver Disease: Pathophysiology, Diagnosis, Management* [Internet]. 10th ed. Philadelphia: Elsevier Saunders; 2015.
13. Upadhyay R. Clinical approach to dilated bile duct [Internet]. *Medicine Update.* Vol. 20, 2010 [cited 2015 Jan 20]. Available from: http://www.apiindia.org/pdf/medicine_update_2010/ge_and_hepatology_04.pdf.
14. Kim B, Kim KW, Kim SY, Park SH, Lee J, Song GW, Jung DH et al. Coronal 2D MR cholangiography overestimates the length of the right hepatic duct in liver transplantation donors. *Eur Radiol.* 2017 May;27(5):1822-1830
15. Neuhaus P, Jonas S, Bechstein WO et al (1999) Extended resections for hilar cholangiocarcinoma. *Ann Surg* 230:808–818
16. Couinaud C (1999) Tell me more about liver anatomy. *Paris Chirurgie* 124:587–588

How to cite this article: Khatiwada S, Adhikari BN, Shakya S. Cadaveric study on the length and diameter of the hepatic ducts. *Int J Health Sci Res.* 2017; 7(12):46-51.
