

Histomorphological Variation of Breast Lump in Lumbini Zone of Nepal

Rajeeva Dhar Dwivedee¹, Nabin Shrestha², Anup Pandeya³

¹Lecturer, Department of Pathology, Kathmandu University, Devdaha Medical College and Research Institute (DMCRI), Devdaha, Rupandehi, Nepal.

²Lecturer, Department of General Surgery, Kathmandu University, Devdaha Medical College and Research Institute (DMCRI), Devdaha, Rupandehi, Nepal.

³Lecturer, Department of Anatomy, Kathmandu University, Devdaha Medical College and Research Institute (DMCRI), Devdaha, Rupandehi, Nepal.

Corresponding Author: Rajeeva Dhar Dwivedee
E-mail: rajeevdwivedee@gmail.com

ABSTRACT

Background: Breast lump can present as inflammatory to neoplastic lesion. Any kind of lesion present in breast makes anxiety to patient for cancer. Histopathology is key for confirm each lesion.

Objective: This study is aimed to observe histomorphological variation of excised breast lump in Lumbini zone of Nepal.

Materials & methods: Prospective descriptive study was done from April 2016 to October 2016 of excised 54 cases of all female breast lumps in National Path Lab, Rupandehi, Nepal. FNAC and excised male breast lump were excluded from the study.

Results: The entire excised breast lumps were categorized as Inflammatory, Non-neoplastic and Neoplastic. Neoplastic is classified as Benign and Malignant lesion. Out of 54 cases aged from 15 -72 years, Fibroadenoma, Fibrocystic Disease, Abscess/Mastitis and Invasive Ductal Carcinoma was dominant lesion of each categories. Fibroadenoma, Fibrocystic Disease with equal frequency of 25.92%, Abscess/Mastitis and Invasive Ductal Carcinoma was 22.22% and 7.40% respectively

Conclusion: Malignant lesion was least common of each category with predominance of Invasive Ductal Carcinoma 7.40% .Invasive Ductal Carcinoma was prevalent in 7th decades.

Key words: Breast Lump, Fibroadenoma, Histopathology

INTRODUCTION

Breast is organ which can change according to marital status and age of patient. ⁽¹⁾ Due to awareness of patient, for any palpable breast swelling, pain and discharge from breast make anxious to patient for malignant lesion. ⁽²⁾ Most common cancer of female in western world is breast cancer and is most common cause of death in 4th to 6th decades. ⁽¹⁾

Lesions in breast varied according to age group and carcinoma of breast is extremely rare before 2nd decades and is

rises after this age and almost 20% upto 9th decade. ⁽¹⁾ Incidence of breast cancer in Asian patient are more commonly seen in younger age group compare to western and nearly one fourth breast cancer in young age. ⁽³⁾ Benign breast lesion are most common lesion of all breast lesion of earlier age group, among them most common were Fibroadenoma and Fibrocystic disease. Despite knowing this excision biopsy is performed to rule out malignant lesion. ⁽⁴⁾

Most of lesions are diagnose on the basis of clinical history, physical

examination, FNAC, ultrasonography, mammographic findings and histopathology correlation. (2,5) Among all such technique biopsy is gold standard for confirmation of diagnosis. (6) This study is carried out to observe the histomorphological profile of all types of breast lump in Lumbini zone of Nepal.

MATERIALS & METHODS

Prospective study from April 2016 to October 2016 received 54 excised biopsy specimen of breast of all age group of female in histopathology department of National Path Lab Butwal, Rupendehi, Nepal. FNAC case and male was excluded from study. Hematoxylin & Eosin staining of section were performed according to manual methods and observed under the

light microscope. The data were tabulated in Microsoft excel 2007 and was analyzed by SPSS 16.

RESULT

The result of present descriptive study is categorized into three categories Inflammatory, Non-neoplastic and Neoplastic. Dominant lesion was Neoplastic 22(40.74%). Neoplastic is again divided into Benign and Malignant lesion and most common lesion was Benign and Fibroadenoma was most prevalent which is 14 (25.92%). Similarly, in Inflammatory and Non-neoplastic categories, Abscess/ Mastitis and Fibrocystic diseases was 12(22.22%) and 14(25.92%) respectively and were shown below in Table 1, Fig 1 and Fig 2.

Table 1: Histopathological finding in different age group (N= 54)

Type of lesion	Total Number of cases and percentage (N=54)	Age group						
		10-20	21-30	31-40	41-50	51-60	61-70	>71
Inflammatory	15 (27.77%)							
Abscess /Mastitis	12 (22.22%)	2	8		1			1
Duct ectasia	1 (1.85%)				1			
Galactocele	2 (3.70%)		2					
Non-neoplastic	17 (31.48%)							
Fibrocystic disease	14 (25.92%)	4	2	5	2	1		
Sclerosing Adenosis	1 (1.85%)		1					
Lactational Adenosis	2 (3.70%)		2					
NEOPLASTIC	22 (40.74%)							
Benign	17 (31.48%)							
Fibroadenoma	14 (25.92%)	6	7	1	0	0		
Myofibroblastoma	1 (1.85%)	1						
Intraductal papilloma	1 (1.85%)					1		
Lactating adenoma	1 (1.85%)		1					
Malignant	5 (9.25%)							
Invasive Ductal carcinoma	4 (7.40%)				1	1	2	
Invasive lobular carcinoma	1 (1.85%)				1			

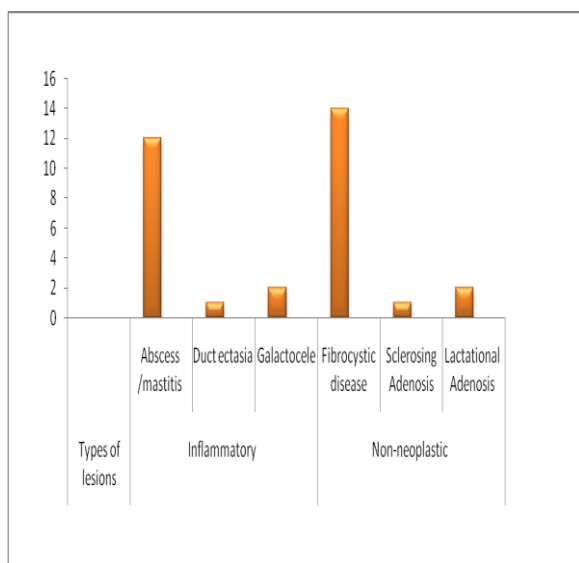


Fig 1: Bar diagram of non-neoplastic and inflammatory lesion

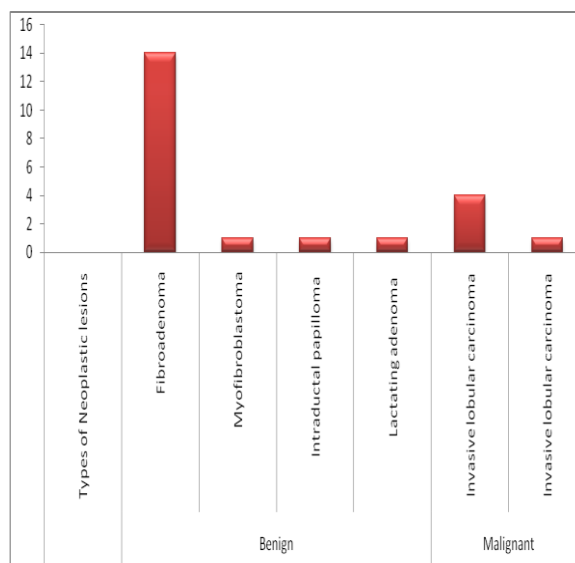


Fig 2: Bar diagram of neoplastic lesion

DISCUSSION

The majority of breast disease patient in Nepal were female. Present study was prospective study and highlighted on frequency and percentage with histomorphological changes of Inflammatory, Non-neoplastic and Neoplastic lesion of specimen sent in National Path Lab, Butwal Nepal. This study was compatible with the study done by Abdul Kader M Albasri et al in reference to most common lesion of these entire Benign and Nonneoplastic lesion showing Fibroadenoma 44.3% and fibrocystic disease 23.4%. Present study showing Benign and Malignant ratio was 4.4:1. (3) In Malignant lesion, most dominant were Invasive Ductal Carcinoma 7.40% is consistent with study done by Shirley SE et al showed 69.5%. (7) The number of frequency is low this is because of less number of cases and short duration of study. Present study showed that dominant type of carcinoma is Invasive Ductal Carcinoma which is 7.40% and other is Invasive Lobular Carcinoma 1.85% and study done by Khokher S et al showed the frequency was 91% of Invasive Ductal Carcinoma and 2% had Invasive Lobular Carcinoma which is also concordance with this study. (8) Similar study done by Abu Khalid et al also showed that Invasive Ductal Carcinoma is the dominant lesion among the malignant lesion with frequency of 7.9% is also consistent with present study. (9) There is no any significant histopathological difference between types of Breast Carcinoma despite short duration of study. Among Benign, Nonneoplastic and Inflammatory lesion prevalence of Fibroadenoma and Fibrocystic Disease was with equal frequency 25.92% and Abscess/Mastitis 22.22% respectively and were most common lesion of each category. This study is about similar in prevalence with study of Abu Khalid et al showing that Fibroadenoma, Fibrocystic Disease and Abscess were 39.4%, 18.4% and 15.9% respectively. (9) Present study revealed that Fibroadenoma and Abscess/Mastitis were seen most commonly

in 3rd decade. However, Fibrocystic Disease was in 4th decade and the cases were 7, 8 and 5 respectively. Present study is concordance with study done by Abdul Kader M Albasri et al in case of Fibroadenoma. However, fibrocystic disease and Abscess/Mastitis were common in 3rd and 5th decade respectively. (3) The reason for this could be due to less sample size and short duration of study in present study.

CONCLUSION

Malignant lesion is least common of each category with predominance of Invasive Ductal Carcinoma 7.40%. Invasive Ductal Carcinoma is prevalent in 7th decades.

ACKNOWLEDGEMENTS

I would like to thank all the National Path Lab histopathology department technical staff and special thanks to Yuvraj Bhusal and Deepa Poudel for entering the data.

REFERENCES

1. Sadik AZ, Hasan MM, Ahmed FU, Kabir MZ. Different Types of Breast Lump in Relation to Different Age Groups. *Faridpur Medical College Journal*. 2014;8(2):56-8.
2. Bajracharya A, Pangeni A. Profile of Breast Diseases in Eastern Nepal. *Journal of College of Medical Sciences-Nepal*. 2016;12(3):89-93.
3. Albasri AM. Profile of benign breast diseases in western Saudi Arabia: An 8-year histopathological review of 603 cases. *Saudi medical journal*. 2014;35(12):1517.
4. McFARLANE M. Benign breast diseases in an afro-caribbean population. *East African medical journal*. 2001;78(7).
5. Choudhary P, Koirala A, Rimal H, Deo A. Cytomorphological study of palpable breast lumps. *Journal of Pathology of Nepal*. 2015;5(10):817-9.
6. Ibrahim IM, Iliyasu Y, Mohammed AZ. Histopathological review of breast tumors in Kano, Northern Nigeria. *Sub-Saharan African Journal of Medicine*. 2015;2(1):47.
7. Shirley S, Mitchell D, Soares D, James M, Escoffery C, Rhoden A, et al. Clinicopathologic features of breast disease in Jamaica: findings of the Jamaican Breast Disease Study, 2000-2002. *West Indian*

- Medical Journal. 2008;57(2):90-4.
8. Khokher S, Qureshi MU, Riaz M, Akhtar N, Saleem A. Clinicopathologic profile of breast cancer patients in Pakistan: ten years data of a local cancer hospital. *Asian Pacific Journal of Cancer Prevention*. 2012; 13(2):693-8.
 9. Raza AKMM, Zaman Ahmed MRI. Study of Breast Lump-A Histopathological Audit of Five Years Specimen in a Medical College of Bangladesh. *Archives of Microbiology & Immunology*. 2017;1(1): 27-32.

How to cite this article: Dwivedee RD, Shrestha N, Pandeya A. Histomorphological variation of breast lump in Lumbini zone of Nepal. *Int J Health Sci Res*. 2017; 7(11):38-41.
