

Case Report

## Rare Presentation of Recurrent Hydatid Cysts

B. Ananda Rama Rao<sup>1</sup>, P.Saikumar<sup>2</sup>, J.srikanth<sup>2</sup>, Md.Raheem<sup>2</sup>

<sup>1</sup>Professor of Surgery, SVS Medical College, Mahabubnagar, Telangana, India,

<sup>2</sup>Resident in Surgery, SVS Medical College, Mahabubnagar, Telangana, India,

Corresponding Author: B. Ananda Rama Rao

### ABSTRACT

Cystic echinococcosis (CE) is a widely endemic helminthic disease caused by infection with larval stage of the *Echinococcus granulosus* tapeworm. Large numbers of people are affected by CE due to presence *E. granulosus* on every continent with the exception of Antarctica. Upon infection with CE, cyst formation mainly occurs in the liver (70%). The diagnosis of non complicated hepatic hydatid cyst depends on clinical suspicion. They appear in two ways as systemic symptoms, and local symptoms based on the site and organ on which larva settles. Here we discuss three different cases presented with mass per abdomen, abdominal pain, vomiting and fever, diagnosed as hydatid cysts of liver, spleen and pelvis with the help of imaging studies and serology. These patients were managed surgically.

**Keywords:** *Echinococcus granulosus*, Hydatid cyst, Tapeworm, Serology.

### INTRODUCTION

Hydatid cyst (HC), or hydatidosis, is a global parasitic zoonosis. <sup>[1]</sup> *Echinococcus Granulosus* being the causative agent of HC disease belongs to taeniidae family of cestoda class, with the height of 2-6 mm and the maximum width of 0.6 mm, consisting of 3-4 rings. <sup>[2,3]</sup> Six different types of *E. granulosus* (sheep, cattle, horse, camel, swine and deer) have been shown based on their genetic structures and biological properties. Sheep type is the most common form in human infections. <sup>[4,5]</sup> *Echinococcus* has two hosts in the life-cycle, Dogs are the “definitive hosts” while Sheep and goats are “intermediate hosts” in which the illness occur. Adult form of tape worms are present in the intestines of primary host animals. Here, they only cause intestinal parasitosis but not organ disease. Adult parasite lives approximately for 5 months in dog intestines. <sup>[6,7]</sup> “Definitive hosts” spread millions of parasite eggs during defecation. The animals which consume these

contaminated herbs becomes “intermediate host”. Embryo (oncosphere) which comes out of the egg taken via gastrointestinal tract, adheres to intestinal wall with its hooks, then enters into circulation and reaches firstly to the liver. Thus, liver is the most common site of disease in humans with 60-70% rate. The second common organ is lung with 20-25% rate. Other than these sites, disease may occur via systemic circulation in another organ (spleen, kidney, bone, brain etc.) with 10% rate. Embryo loses its scolex when it settles in an organ, and takes the cyst form consisting of cuticula (exocyst) and germinal membrane (endocyst). Here we discuss our experience in managing various patients presenting as recurrent hydatid cysts.

### CASE REPORT

**CASE-1:** A 50 years old female from non endemic area with moderate built and poor nourishment presented with complaints of mass in epigastrium, early satiety and post

prandial abdominal discomfort since two years. Vitals were normal, biochemical values were within normal limits except for leukocytosis and elevated LFTs. O/E non tender, non mobile mass measuring approximately 6X6cms present in epigastrium probably intra peritoneal. USG abdomen suggestive of 8x8 cms and 5x6 cms Cystic lesions with multiple small

loculations and internal echoes within it, in the Left lobe and a smaller one in the antero inferior aspect of Right lobe of Liver- Multiple Hydatid Cysts in Liver with Daughter cysts. Patient was posted for surgery and simple cyst resection was done, followed by Post operative mebendazole therapy for six months.

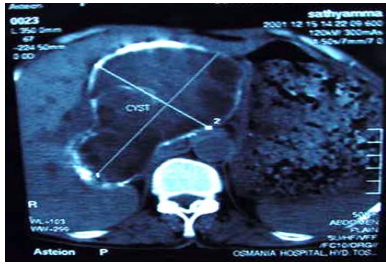


Fig no:1 USG

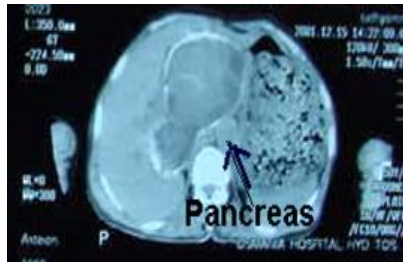

Fig no: 2 CT Scan

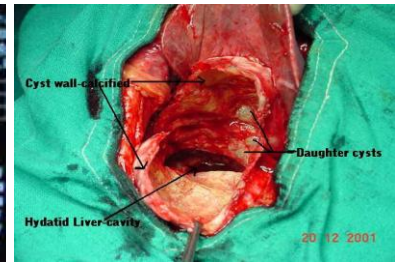


Fig no:3 Intra op

**CASE-2:** A 50 years old female referred from gynecology department for complaints of vomitings, lower abdominal pain since three months. Patient was moderately built and nourished with stable vitals and all biochemical values were within normal limits. She was operated for hydatid cysts of liver in 1985. O/E vague mass present in the left hypogastrum probably arising from spleen. P/V-mass palpable in the left fornix and uterus was fixed. USG s/o Spleen: 10

cms, Cystic lesion with collapsed membrane adherent to spleen measuring 4.7x5.2 cms and Mixed echogenic mass 6.5 x 5.0 cms in Right adnexa while Left ovary was not visualized- Intra peritoneal hydatid cysts and ?Right ovarian Hemorrhagic cyst. Patient was posted for surgery and radical cystectomy for splenic cysts and pericystectomy for pelvic cysts was done. Post operatively patient was started on albendazole therapy for three months.

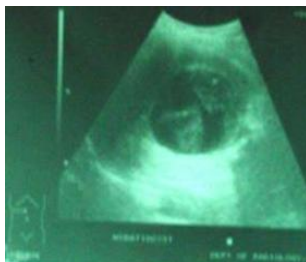

Fig no:4 Splenic cyst.

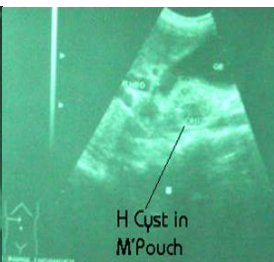


Fig no:5 M-pouch

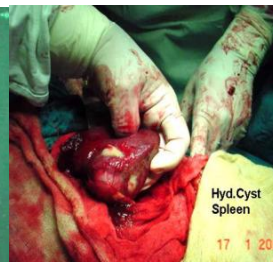

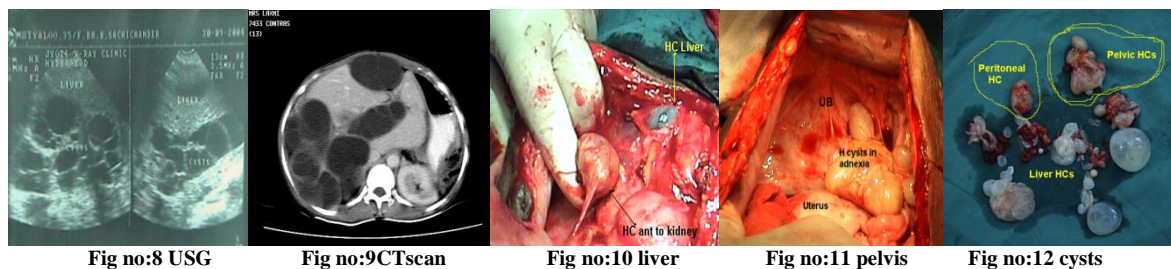
Fig no:6 splenic cyst

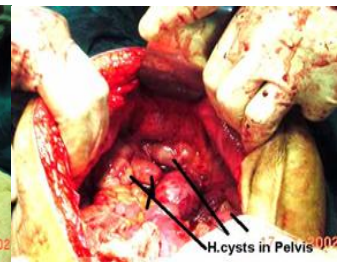

Fig no:7 pelvic cysts

**CASE-3:** A 59 years old female presented with complaints of recurrent abdominal pain since two years which aggravated since two months. Mass in the upper half of the abdomen and fever with chills since one month with post splenectomy status. O/E palpable mass measuring approximately 10X8cms present in the epigastrium with no palpable lymphnodes. Patient was operated

for hydatid cysts of liver and spleen in 1997. USG s/o multiple hydatid cysts of liver, retroperitoneum and adnexa. Biochemical tests show eosinophilia and increased alkaline phosphatase levels. Pericystectomy was done and thorough wash of the peritoneum with hypertonic saline and scolicedal agents was done.



## DISCUSSION

*E. granulosus* is a small tapeworm that typically infects carnivores after the consumption of offal from infected intermediate hosts, such as sheep or pigs. In the small intestine, the parasite firmly attaches to the mucosa, and later sheds gravid proglottids that are excreted in the infected animal's feces. [8] Within each proglottid, there are hundreds of eggs. These eggs can then be ingested by intermediate hosts where they mature into cysts and daughter cysts. Humans are accidental intermediate hosts that become infected by ingesting water, food, or soil contaminated with such feces. In human infection, the first stage is the asymptomatic incubation period, where oncospheres that are able to penetrate the human intestinal wall are released. These oncospheres enter the liver, lungs, and various other organs through portal venous system. [9-11] Next, the oncospheres begin cyst development [9,12] which are usually unilocular, and can range from 1 cm to 15 cm in diameter. In hepatic cystic echinococcosis (CE), cyst growth ranges from 1–2 mm to 10 mm per year. The cysts are composed of two layers, inner nucleated, germinal membrane, and an outer acellular, laminated layer. The immune system responds to the cyst by forming a calcified fibrous capsule around it, which is the layer that is most often visualized on imaging studies. [13] Most of the patients are asymptomatic as they are slow growing. Large cysts >10cms may cause most characteristic right upper quadrant pain. [14] Pain may be intermittent or continuous and gradually increasing over a period of time. Urticaria, asthma and fever may occur as a response to the *Echinococcus* antigen in cyst fluid. physical signs are raised right hemi

diaphragm, a tender enlarged liver or palpable liver mass. Cyst may rupture into the biliary system (leading to cholangitis with or without obstructive jaundice), into the peritoneum (leading to anaphylaxis and peritoneal dissemination) or into the pleura or lung (causing pleural hydatidosis or bronchial fistula). Diagnosis is based on history, clinical examination, imaging (USG being widely used, CT scan) and serology, most commonly IgG. Medical treatment with Benzimidazole carbamates, Albendazole and Mebendazole is being used for inoperable cases, The metabolite of albendazole is more potent than the rest. [15] Surgical management of echinococcal cysts, most commonly with partial and total cystectomy, has long been considered the definitive cure for CE. [16,17] Different surgical approaches are radical resection, simple resection, radical pericystectomy, incision and drainage with instillation of scolicidal agents and PAIR (percutaneous aspiration injection and reaspiration). A newer surgical approach called subadventitial cystectomy has been developed for liver hydatid disease. [18,19] Follow-up is recommended initially every six months for the first two years, and then once a year depending on the appropriate clinical setting.

## CONCLUSION

Hepatic echinococcal should be considered in the differential diagnosis of hepatic cysts. The rate of sensitivity is less for Serum antibody assays, but antigen assays may be of value. For determining cyst stage, size, location and complications imaging studies are very crucial. It can also be helpful in assessing the suitability of a minimally invasive PAIR approach.



Uncomplicated active cysts can be managed with chemotherapy alone or in combination with a PAIR approach. Uncomplicated, inactive cysts can be managed with the “watch-and-wait” strategy. Patients with Complicated cysts with structural involvements of the biliary system must undergo surgery. Combined treatment with ALB + surgery leads to a lower risk of recurrence compared with surgery alone.

#### REFERENCES

1. Buttenschoen K, CarliButtenschoen D.(2003) Echinococcus granulosus infection: the challenge of surgical treatment. *Langenbecks Arch Surg.* 2003; 388:218–230
2. Eckert J,Conraths FJ, Tackmann K(2000) Echinococcosis: an emerging or re-emerging zoonosis? *Int J Parasitol* 2000;30:1283-1294.
3. Polat P, Kantarci M, Alper F, (2003) et al. Hydatid disease from head to toe. *Rdiographics*2003;23: 475-494.
4. Chabane-Banaoues R, Oudni-M'radM, M'rad S, (2016) Environmental Contamination by Echinococcus granulosus ensulato Eggs in Relation to Slaughterhouses in Urban and Rural Areas in Tunisia. *Korean J Parasitol*2016;54:113-118.
5. Thompson RC, McManus DP (2001) Aetiology: parasites and lifecycles. In: Eckert J, Gemmell M, Meslin FX, Pawlowski Z. *WHOI/OIE manual on echinococcosis in humans and animals: a public health problem of global concern.* Paris: World Organisation for Animal Health 2001;1-19
6. Carrim ZI, Murchison JT (2003)The prevalence of simple renal and hepatic cysts detected by spiral computed tomography. *ClinRadiol* 2003;58: 626-629
7. Karaman U, Mman O, Kara M, et al (2005). [Hydatid cyst prevalence in the region of Kars.]. *TurkiyeParazitDerg*2005;29: 238-240.
8. Siracusano A, Teggi A, Ortona E. (2009)Human Cystic Echinococcosis: Old Problems and New Perspectives. *Interdiscip Perspect Infect Dis.* 2009;474368.
9. Lewall DB. (1998) Hydatid disease: Biology, pathology, imaging and classification. *Clin Radiol.* 1998;52:863–874.
10. Gottstein B. (2000) Hydatid Disease, Major Tropical syndromes by body system. *Systemic infections.* Chap. 2000;169 section
11. Siracusano A, Delunardo F, Teggi A, (2012) E. Host-Parasite Relationship in Cystic Echinococcosis: An Evolving Story. *Clin DevImmunol.* 2012;2012:639362.
12. Pedrosa I, Saíz A, Arrazola J, et al (2000) CS. Hydatid disease: Radiologic and pathologic features and complications. *Radiographics.* 2000;20:795–817
13. al-Karawi M, el- Shiekh Mohamed AR, Yasawy MI.(1990) Advancesin diagnosis and management of hydatiddisease. *Hepatogastroenterology* 1990;37:327-31.
14. Smego R, Sebanego P(2015). Treatment options for hepatic cystic echinococcosis. *Int J Infect Dis.* 2005;9:69–76.
15. Tuxun T, Zhang JH, Zhao JM, et al.(2014) World review of laparoscopic treatment of liver cystic echinococcosis—914 patients. *Int J Infect Dis.* 2014;24:43–50.
16. Junghanss T, da Silva AM, Horton J, (2008). Clinical management of cystic echinococcosis: state of the art, problems, and perspectives. *Am J Trop Med Hyg.* 2008;79:301
17. Lv H, Jiang Y, Peng X, Zhang S, et al(2002). Total subadventitial cystectomy for the treatment of 30 patients with hepatic hydatid cysts. *Chin J Gen Surg.* 2002;17:529–530.
18. Peng X, Li J, Wu X, Zhang S, et al(2006). Detection of Osteopontin in the pericyst of human hepatic Echinococcusgranulosus. *Acta Trop.* 2006;100:163–171
19. Marani SA, Canossi GC, Nicoli FAetal (1990) Hydatid disease: MR imaging study. *Radiology.* 1990;175:701–706.

How to cite this article: Rao BAR, Saikumar P, Srikanth J et al. Rare presentation of recurrent hydatid cysts. *Int J Health Sci Res.* 2017; 7(11):321-324.

\*\*\*\*\*