

Case Report

## Metastasis of Lung Carcinoma Diagnosed From Radiograph of the Jaw: A Case Report

Dr Sneha R Sharma<sup>1</sup>, Dr Freny R Karjodkar<sup>2</sup>, Dr Kaustubh P Sansare<sup>3</sup>,  
Dr Satyapal Johaley<sup>1</sup>

<sup>1</sup>Postgraduate Student, <sup>2</sup>Prof and HOD, <sup>3</sup>Associate Professor,  
Department of Oral Medicine and Radiology, Nair Hospital Dental College, Mumbai Central, Mumbai,  
Maharashtra, India

Corresponding Author: Dr Sneha R Sharma

### ABSTRACT

Tumors metastasizing to the oral cavity and the jaws are a rare entity, and they account for less than 1% of all malignant tumors occurring in the oral cavity. The breast, lung and kidney are the common sources of metastasis to the oral cavity and the jaw bones. Metastasis from a primary lung carcinoma to the mandible is rare, but shows features similar to other common pathologies like odontogenic tumors or cysts. This makes their diagnosis all the more challenging. Here we present a case of a 61 year old male patient who presented with metastasis from the lung to the mandible, where the metastasis was detected before the primary tumor in the lung.

**Key words-** Metastasis, pulmonary carcinoma, tumor.

### INTRODUCTION

Tumors metastasizing to the oral cavity and the jaws are a rare entity, and they account for less than 1% of all malignant tumors occurring in the oral cavity. [1] Metastasis from a primary lung carcinoma to the mandible is rare, but shows features similar to other common pathologies like odontogenic tumors or cysts.

The age of the patients presenting with metastatic tumors is generally between 40-70 years. [2]

The gingiva and alveolar mucosa (54%) and tongue (30%) are mainly involved in patients presenting with metastatic lesions. [3,4] The breast, lung and kidney are the common sources of metastasis to the oral cavity and the jaw bones. [5]

In 25% of the diagnosed cases, oral metastatic lesions are found to be the

primary sign of metastatic spread, while in 23% of cases; the metastatic tumor is an indication of undetected primary metastatic tumor of a distant organ. [6] Metastasis to the oral cavity is often the first manifestation of lung cancer. [7] Approximately 9-30% of patients presenting with lung cancer develop metastases to bone, which further causes significant morbidity and mortality. [8]

The characteristic features that Lung carcinomas present are insidious onset, early metastatic spread and poor prognosis as difficulty in detection causes a delayed detection.

Here we present a case report of a patient which describes a case of lung carcinoma metastatic to the mandible, where the metastasis was detected before the primary tumor in the lung, with emphasis on a complete and detailed dento-alveolar examination so as to aid in early diagnosis of the primary focus of metastatic tumor.

## CASE REPORT

A 61 year old male patient reported to the OPD with a chief complaint of a growth in the lower right posterior region of the jaw, since one month.

The patient was apparently alright 1 month ago when he noticed a small growth which was gradually increasing in size, causing difficulty while chewing food. There were no associated symptoms of pain or paresthesia. The patient also had some occasional pain in the diaphragm area for which he was ignorant and did not visit any physician for the same. Patient had a habit of tobacco chewing since 35 years.

On examination it was found that the patient had normal built but had difficulty in walking and had generalized weakness. There was no extra oral swelling, and no gross facial asymmetry.

On intra oral examination (figure 2), a well-defined solitary soft tissue growth was noted in the mandible extending from 43 to 47. The growth extended superiorly from the occlusal level of the mandibular molar teeth upto the buccal vestibule inferiorly. The growth was firm and fibrotic in consistency and non-tender on palpation, with an erythematous ulcerated area noted on its superficial aspect. Expansion was noted on the buccal aspect of the growth. There was no associated pus discharge.

The adjacent teeth were 44 45 and 47 were mobile and 46 was missing, and the patient did not give a history of a recent extraction. Generalized attrition was noted with all the maxillary and mandibular teeth which were present. The submandibular lymph nodes on the right side were fixed.

A Digital OPG was carried out as a primary radiographic investigation which revealed a well-defined radiolucent radiopaque lesion mandible extending over the alveolar ridge of 46. Ill-defined alveolar bone loss was noted in the apical region of 43 44 45 46. The most distal tooth present was 47 which showed peri-radicular bone loss. (Figure 3)



Figure 1- Extra-oral clinical picture

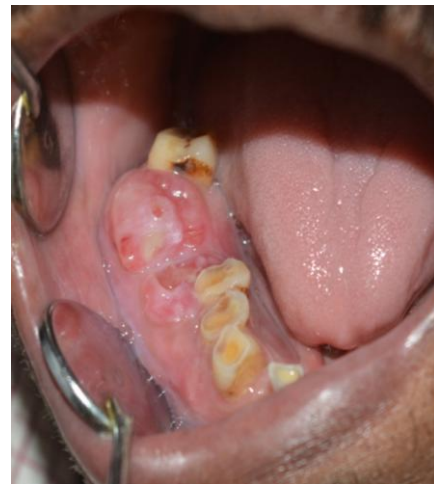

Figure 2- Intraoral clinical picture showing a well-defined exophytic growth in the 45 46 region

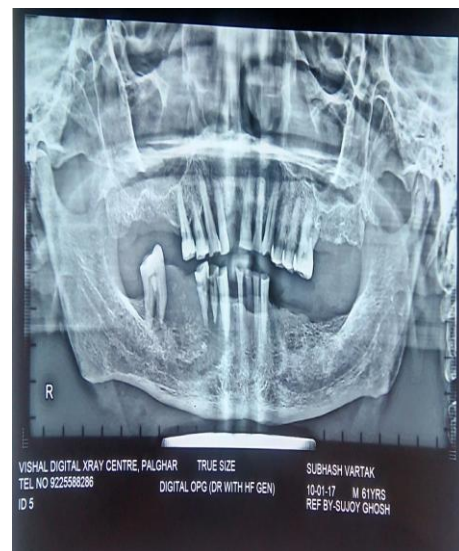

Figure 3- Digital OPG showing a diffuse irregular radiolucency with ragged borders in the right side body of the mandible in 46 region

Based on the clinical and radiographic findings, a provisional diagnosis of a malignancy was given. Further investigations showed that blood

glucose, serum calcium, serum phosphorus and creatinine levels were within normal limits and alkaline phosphatase levels were raised. The patient was then referred for Scintigraphy and a full body CT scan.

The scintigraphy procedure involved intravenous injection of 20mCi of 99M Tc-MDP and static images were taken 3 hours later.

The scintigraphy showed intense radiotracer uptake in the entire skeleton and indicated Super Scan Appearance which was suggestive of extensive skeletal metastasis. (Figure 4)

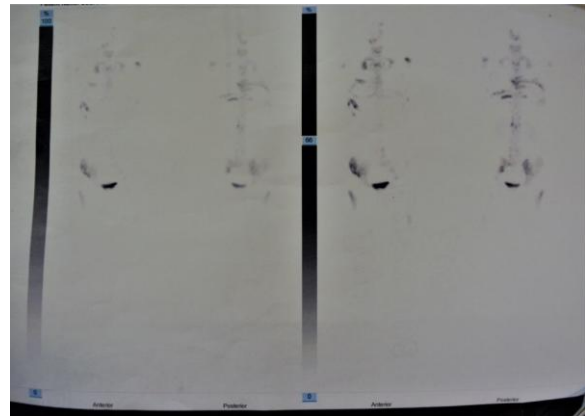


Figure 4-Scintigraphy showing intense radiotracer uptake in the entire skeleton

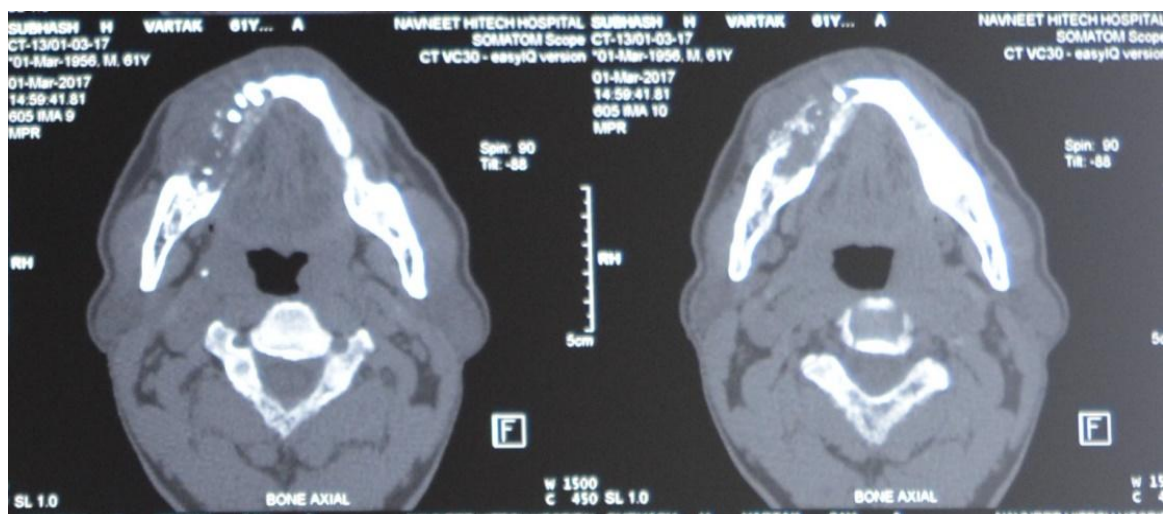


Figure 5- CT Scan- Axial section showing destruction of the buccal and lingual cortical plates in the right side body and parasymphysis of the mandible.

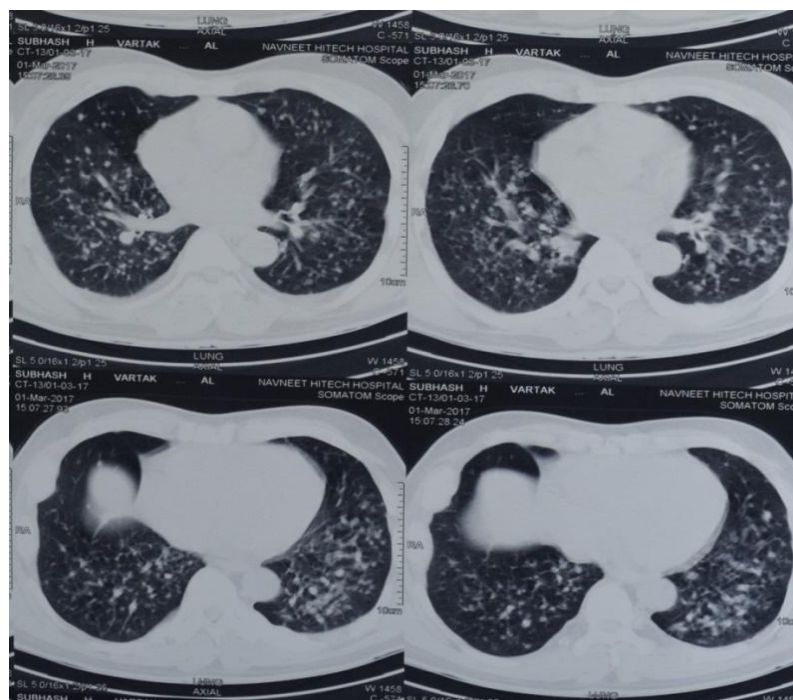


Figure 6 CT Scan - Axial Section of the Lung showing moderate to enlarged soft tissue mass in the lung parenchyma

The full body CT was done to identify the location of the primary carcinoma. The CT scan was done by administration of oral and intravenous contrast media and the study was performed on 16 slice Siemens Somatom scope.

The CT image showed bone lesion in the mandible along its anterior and right lateral aspect measuring 5.4 x 2.5 cms in maximum dimensions (figure 5). It also revealed moderate to large sized enlarged nodular neoplastic soft tissue mass lesions involving the right paratracheal and right hilar region of the mediastinum and lung parenchyma measuring 5.5x5.2x4.5 cms (SI x ML x AP) in maximum dimensions and revealed moderate inhomogeneous enhancement on post contrast study with areas of central necrotic changes (figure 6). Multiple enlarged lymph nodes were present in the right paratracheal, prevascular, precarinal, subcarinal and left hilar region of the mediastinum.

There was generalized prominence of the bronchovascular markings in both lung fields suggestive of lymphatic spread along the interstitium. Rest of the lung parenchyma revealed multiple small sized nodular lesions which were distributed randomly and extensively along the bronchovascular interstitium, most likely of interstitial spread of the neoplastic process. All these features led to a diagnosis of a primary lung carcinoma with metastasis to the jaws.

The patient was then referred to a tertiary centre for a biopsy and further treatment. There was a loss to follow up as the patient was reluctant to undergo biopsy even after being informed about his condition.

## DISCUSSION

Metastasis is the spread of cancer cells from one part or organ of the body to another part or organ, which are not directly connected to each other. [9,10] The process of metastasis involves breach of a sequence of barriers by tumor cells. [2]

The most common type of metastatic cancers spreading to the oral cavity and

jaws are the carcinomas. [11] There is slight male predilection with the mean age of occurrence being 54 years. [12] In male patients the metastasis to the oral cavity occurs most commonly from the lungs, kidney liver and prostate, while for females it is the breast, female genital organs, kidney and colorectum. [5] In the present case too, the lungs were found to be the site of primary tumor.

The pathology behind the oral metastasis remains unclear but it is believed to be a process involving multiple stages, where the tumor cells detach themselves from the primary tumor site and traverse the lymphatic or blood vessels to reach the distant organs. [13]

Metastatic foci are situated mainly in the red marrow of all bones. The mandible is more affected than the maxilla, mainly the molar area, as the mandible contains more of red bone marrow mainly in the ramus and angle region as compared to the zygoma and maxilla which contain more yellow bone marrow. [14]

Another mechanism that has been proposed as the basic mechanism behind the metastatic spread, is the Batson's plexus which is a retrograde flow through the venous system. [7,15]

It has been stated in literature that 70-85% of patients who present with malignant disease of the breast lungs or prostate cancer will also have skeletal metastasis, of which only 1% involving the jaw bones. [16]

The intraoral appearance of metastatic lesions is similar to reactive lesions or benign tumors like pyogenic granuloma, epulis, or peripheral giant cell granuloma. [17]

The patients presenting with jaw bone metastasis may complain of pain swelling and paresthesia.

As this is a rare condition, the clinical presentation may lead to misdiagnosis of a benign process.

The treatment modality for the metastatic tumors depends on the stage presented during its diagnosis. The oral

metastatic tumors are generally associated with involvement of multiple other organs, with a poor prognosis and are often not easy to palliate.<sup>[18]</sup> The various treatment options include chemotherapy, radiotherapy or surgical excision under anaesthesia.<sup>[17]</sup> The overall prognosis is poor and the average survival rate has been found to be 4-12 months with a maximum survival rate of 15 years.<sup>[19]</sup>

Suspecting a metastatic disease in all patients might seem overzealous during the examination of patients reporting with jaw pain or swelling. But necessary and specific investigations should be carried out in the patients who do not respond to conventional therapy or who appear to be debilitated with other medical symptoms. In the present case the patient had been ignorant to the generalized weakness and pain in his diaphragm and the region below the lungs, but careful examination and appropriate sequential investigations helped to reach a diagnosis of a primary carcinoma in the lung.

Thus it is the duty of the clinician to be vigilant to carry out a complete examination of the patient and carry out the necessary investigations which would aid in locating the primary site of the metastatic tumor. The early diagnosis and prompt treatment would thereby help in providing a better prognosis to the patients.

## REFERENCES

1. Servato JP, de Paulo LF, de Faria PR, Cardoso SV, Loyola AM. Metastatic tumours to the head and neck: retrospective analysis from a Brazilian tertiary referral centre. *Int J Oral Maxillofac Surg.* 2013;42(11):1391–6.
2. Hirshberg A, Shnaiderman-Shapiro A, Kaplan I, Berger R. Metastatic tumours to the oral cavity –pathogenesis and analysis of 673 cases. *Oral Oncol.* 2008;44:743–52.
3. Orlandi A, Basso M, Di Salvatore M, Federico F, Cassano A, Barone C. Lung adenocarcinoma presenting as a solitary gingival metastasis: A case report. *J Med Case Rep.* 2011;5:202.
4. Ravi Prakash SM, Verma S, Gill N, Malik V. Multiple gingival metastasis of adenocarcinoma of the lung. *Indian J Dent Res.* 2012;23:558–9.
5. Misir AF, Mercan U, Günhan O. Metastasis of lung adenocarcinoma to the mandible: Report of a case. *J Oral MaxillofacPathol.* 2013;17:253–6.
6. Akheel M, Tomar SS, Hussain SM. Metastatic oral soft-tissue lesions: An incidental finding in four cases. *South Asian J Cancer.* 2013;2:146.
7. Curien R, Moizan H, Gerard E. Gingival metastasis of a bronchogenic adenocarcinoma: report of a case. *Oral Surg Oral Med Oral Pathol Oral RadiolEndod.* 2007;104:e25-28.
8. Dhupar V, Akkara F, Kamat RD, Shetye O: Mandibular metastasis from a pulmonary squamous cell carcinoma. *Ann MaxillofacSurg* 4:103, 2014
9. Rossi G, Marchioni A, Sartori G, Longo L, Piccini S, Cavazza A. Histotype in Non-small lung cancer therapy and staging: The emerging role of an old and underrated factor. *CurrRespir Med Rev.* 2007;3:69–77.
10. Dorland WA. 30th ed. Philadelphia, PA: Elsevier Saunders; 2003. *Dorland's Illustrated Medical Dictionary*; p. 1138
11. Daley T, Darling MR. Metastases to the mouth and jaws: A contemporary Canadian experience. *J Can Dent Assoc.* 2010;76:1–7.
12. Seoane J, Van der Waal I, Van der Waal RI, Cameselle-Teijeiro J, Antón I, Tardio A, et al. Metastatic tumours to the oral cavity: A survival study with a special focus on gingival metastases. *J Clin Periodontol.* 2009;36:488–92.
13. Alaa MS, Emre B, Begüm K, Yetisyigi T. Metastasis from lung cancer. Presenting as pyogenic granuloma in the lower gingiva. *ActaStomatol Croat.* 2012;46:307–11.
14. Kricun ME (1985) Red-yellow marrow conversion: its effect on the location of some solitary bone lesions. *Skeletal Radiol* 14 (1):10–19
15. Marx RE, Stern D. Chicago, IL: Quintessence; 2003. *Oral and Maxillofacial Pathology: A Rationale for Diagnosis and Treatment*; pp. 822–6.

16. Meyer I, Shklar G. Malignant tumors metastatic to mouth and jaws. *Oral Surg Oral Med Oral Pathol.* 1965;20:350–62.
17. Huang ChJ, Chang YL, Yang MY, Hsueh CH, Yu ChT. Lung cancer metastatic to the maxillary gingiva—a case report and literature review. *Oral Oncology Extra.* 2005;41:118–120.
18. Rajappa S, Loya AC, Rao DR, Rao IS, Surath A, Srihari U. Metastasis to oral cavity- A report of two cases and Review of literature. *Indian Journal Of Medical & Paediatric Oncology.* 2005;26:43-6.
19. López-Jornet P, Garcia G, Camacho-Alonso F. Isolated gingival metastasis from lung carcinoma. *N Y State Dent J.* 2011;77:27-8.

How to cite this article: Sharma SR, Karjodkar FR, Sansare KP et al. Metastasis of lung carcinoma diagnosed from radiograph of the jaw: a case report. *Int J Health Sci Res.* 2017; 7(11):311-316.

\*\*\*\*\*