

Case Report

## Ossifying Fibroma of Jaw: A Clinico-Radiographic Case Series

Dr Satyapal Johaley<sup>1</sup>, Dr Freny R Karjodkar<sup>2</sup>, Dr Kaustubh P Sansare<sup>3</sup>,  
Dr Sneha R Sharma<sup>1</sup>, Dr Shikha Goyal<sup>4</sup>

<sup>1</sup>Postgraduate Student, <sup>2</sup>Prof and HOD, <sup>3</sup>Associate Professor, <sup>4</sup>MDS,  
Department of Oral Medicine and Radiology, Nair Hospital Dental College, Mumbai Central, Mumbai,  
Maharashtra, India

Corresponding Author: Dr Satyapal Johaley

### ABSTRACT

Ossifying fibroma (OF) is benign uncommon tumor usually unilocular occasionally multilocular fibro-osseous lesion, mainly involves craniofacial skeleton arising from the cells of the periodontal ligament, composed of fibrous connective tissue with a variable amount of mineralized materials. Mostly smaller in size diagnosed incidentally during routine dental radiographs, larger lesions the patient may complain of swelling with a displacement of teeth. OF shows varying radiographic patterns based on the amount of mineralized tissue and degree of maturation of the lesion. The timely diagnosis and management of the tumor are important to limit the spread and to reduce the morbidity of the patient. This article presents a series of cases of Ossifying fibroma along with the importance of advance imaging in diagnosis of ossifying fibroma.

**Keywords:** Ossifying Fibroma, Giant cement-ossifying Fibroma, Fibro osseous lesion, CBCT.

### INTRODUCTION

Ossifying Fibroma (OF) is uncommon benign fibro-osseous tumor commonly affecting the craniofacial region. The first description of ossifying fibroma was given by Menzel in 1872, calling it a cement ossifying fibroma. [1] Montgomery in 1927 first used the term OF<sup>2</sup>. In 1948 Sherman and Sternberg give the detailed description of the clinical, radiological and histological characteristics of OF. [3] Ossifying and/or cementifying fibroma arises from periodontal membrane a layer of fibrous connective tissue surrounding the roots of the teeth, which contains multipotential cells that are capable of forming cementum, lamellar bone, and fibrous tissue as a result of which they constitute histological variants of the same pathological process. [4] The histopathology

of the tumor may be confused with other fibro-osseous lesions, thus the final diagnosis requires correlation of the clinical histopathology and radiographic findings. [5,6] Advanced imaging modalities like CT and CBCT scans are very helpful in the investigation, especially in extensive cases since it defines the extent of the lesion and destruction of the surrounding structure.

### Case Report 1

A 36 years old female patient reported with chief complain of food lodgement in mandibular right first molar and swelling in right premolar region. The patient reported having suffered trauma in that same area 4 years ago had a history of extraction of the fractured mandibular second premolar. The patient had a history of hypothyroidism, endocrinology report

brought by patient revealed raised TSH level, T3 and T4 levels were within normal range.

Extraoral examination revealed no facial asymmetry, small swelling on the body of mandible right side. On palpation swelling was bony hard, non-tender afebrile; lymph nodes were non-palpable (Figure 1A).

Intraoral examination revealed the presence of swelling with obliteration of buccal and lingual vestibule in relation to the mandibular right first and second premolar region swelling was bony hard and non-tender on palpation. The overlying mucosa was normal, missing mandibular right second premolar, restoration present with amandibular right second molar (Figure 1B).

Panoramic radiograph showed well-defined mixed radiolucent-radiopaque density with ill-defined areas of dense radiopacities with surrounding ground-glass densities, surrounded by sclerotic borders, with a displacement of inferior alveolar nerve inferiorly. The lesion was surrounded by radiolucent rim suggestive of capsulation (Figure 1C).

CBCT scan revealed well-defined expansile osteolytic lesion in the body of mandible on right side. In sagittal section, lesion extending from distal to mandibular right lateral incisor to mandibular right first molar, superiorly from alveolar crest to lower border of the mandible, the internal structure showed ill-defined areas of dense sclerosis/amorphous calcification with surrounding ground-glass densities. In coronal section expansion of buccal and lingual cortex with the maintenance of integrity was noted (Figure 1D,E).

Clinical-radiological findings suggestive of Fibro-osseous lesion of jaw right side premolar region. Histopathological findings suggestive of Cemento-Ossifying Fibroma

Complete surgical resection with enucleation and curettage of the lesion with the extraction of mandibular right canine and first premolar. The patient was kept under regular clinical and radiological follow-up due to recurrent nature of the lesion.

FIGURE 1

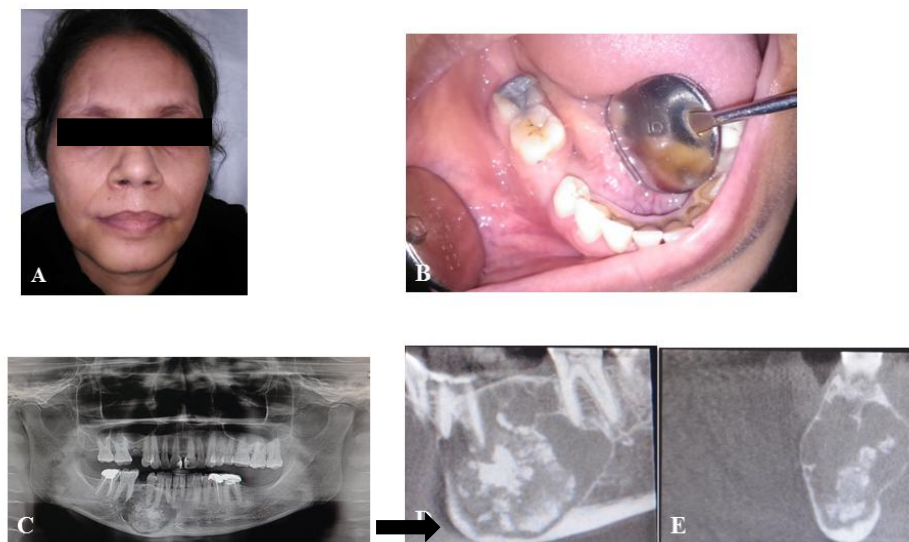


Figure 1: Case 1;

A: Extra Oral Clinical photograph showing facial asymmetry on left side.

B: Intraoral clinical photograph showing swelling mandibular right premolar region. C: panoramic radiograph showing solitary well-defined ovoid, corticated mixed radio-opaque radiolucency with central area of opacification surrounded by radiolucent rim (white arrow) involving the right body of mandible.

D: Sagittal C1 scan showing inferior displacement of lower border of mandible, cortical thinning, central area of amorphous radiopaque density (black arrow).

E: Axial CT scan showing bucco-lingual expansion

### Case Report 2:

A 50 years old female patient reported with chief complain of swelling on the mandibular right molar region since 6 months.

Extraoral examination revealed swelling over the preauricular region and ramus of mandible region swelling was bony hard in consistency and non-tender on palpation (Figure 2A).

Intraoral examination revealed swelling extending from distal to maxillary and mandibular right first molar to the retromolar area, involving postero-lateral surface of the hard palate and complete retromolar region with lingual expansion. The overlying mucosa was normal in appearance (Figure 2B). The swelling was bony hard in consistency and non-tender on palpation. Lymphadenopathy present right submandibular lymph node was palpable.

CBCT revealed a mixed expansile lesion in the right side. In Coronal section, lesion covers right infratemporal space and is a close relation to sphenoid bone and its

pterygoid plates with thinning and bowing of right side ramus and condyle extending from base of the skull in the temporal region to the lower border of the mandible superiorly involving complete ramus (Figure 2D). In the axial section, the periphery of the lesion showed well-defined corticated margin in some areas and irregular margins in certain areas as extending anteroposteriorly from posterolateral border to right maxilla till posterior border of the ramus of the mandible. The internal structure showed mixed radiopaque-radiolucent areas. Some areas showed well defined multiple separate radio-opacities and amorphous patterns (Figure 2E). Based on clinico-radiographic findings a provisional diagnosis of Fibro-osseous lesion.

Patient was referred for histopathological examination, findings were suggestive Cemento-Ossifying Fibroma of right ramus of the mandible and the posterolateral surface of the maxilla.

FIGURE 2

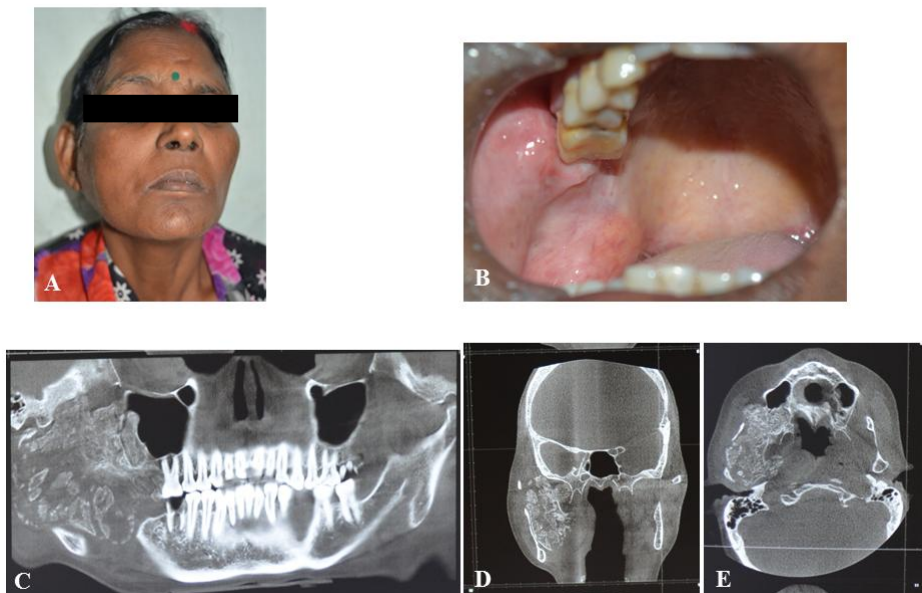


Figure 2, Case 2;

A: Extra Oral Clinical photograph showing facial asymmetry on right side.

B: Intraoral clinical photograph showing swelling on retromolar region right side.

C: Panoramic radiograph showing osseous lesion involving the mandible, maxilla and maxillary sinus right side.

D: Coronal CT scan showing lesion expanding the maxilla, and extending into the maxillary antrum and occupying complete ramus of mandible.

E: Axial CT scan showing mixed radiopaque radiolucent heterogeneous density (white arrow).

### Case Report 3:

A 15 years old female patient reported with complain of swelling on maxillary left first molar region and face since 6 months.

Extraoral examination revealed diffuse swelling on left side face with facial asymmetry (Figure3A, B). Left submandibular lymph node palpable and tender.

Intraoral examination revealed swelling in relation to maxillary left first molars and premolar region with buccolingual expansion, no displacement of the adjacent teeth. The swelling was bony hard and non-tender on palpation (Figure3C).

A panoramic radiograph revealed well-circumscribed, mixed radiopaque-radiolucent shadow in left maxilla involving the maxillary sinus and the alveolar bone extending from apical to maxillary left incisor to the first molar region with

displacement of adjacent teeth and floor of maxillary sinus superiorly (Figure3C).

CT scan revealed in axial and coronal section large expansile, circumscribed lesion involving maxillary alveolus on the left side and left half of hard palate, multilocular caused expansion of the walls of the maxillary sinus internal structure showed some areas of calcification. The lesion was slightly protruding into the nasal cavity. The medial wall of left maxillary sinus was bowed. Displacement of the inferior wall of orbit was seen axial section showed buccolingual expansion of cortical plates extending anteroposteriorly from distal to maxillary left canine to the posterolateral border of hard palate left side (Figure3D,E). Based on all the clinico-radiographic findings a provisional diagnosis of the Benign Odontogenic tumor was made. Histopathological findings suggestive of Ossifying Fibroma.

FIGURE 3

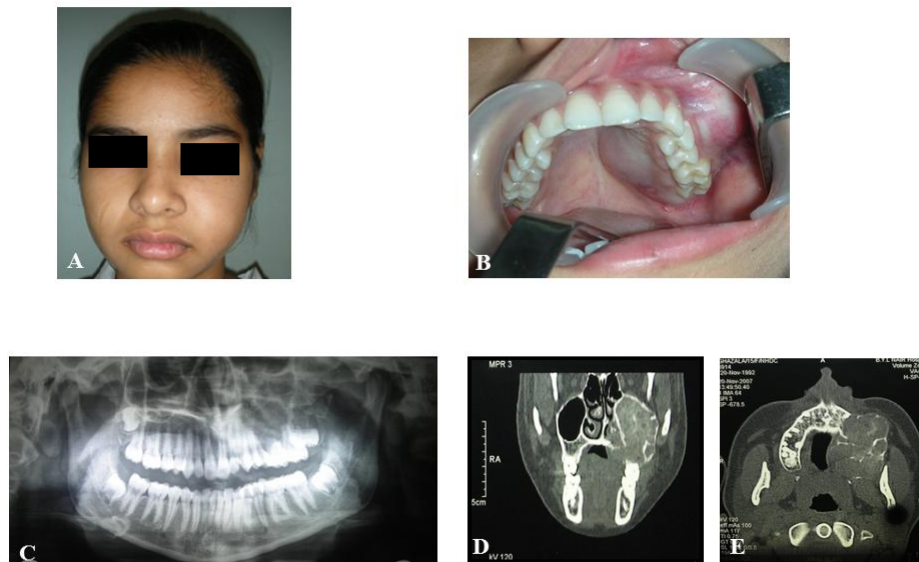


Figure 3, Case 3;

A: Extra Oral Clinical photograph showing facial asymmetry on left side.

B: Intraoral clinical photograph showing swelling on left side hard palate.

C: Panoramic radiograph showing large osseous lesion involving the maxilla and maxillary sinus left side.

D: Coronal CT scan showing of lesion invaginating the maxillary antrum, and extending into the nasal septum,

E: Axial CT scan showing centre of lesion with flecks of calcification surrounded by radiolucency (white arrow).

### Case Report 4:

A 15-year-old male patient complained of pain and swelling in the maxillary left molar region since 1 year.

Extraoral examination revealed diffuse swelling on left side of the face, extending anteriorly up to inner canthus of the eye, posteriorly till posterior border of

ramus, superiorly till tragus of the ear and inferiorly till inferior border of mandible (Figure 4A) with a smooth surface, the swelling was bony hard in consistency, a febrile and non-tender on palpation. Lymph nodes non-palpable.

Intraoral examination revealed swelling expanding bucco-lingually left side in relation to the mandibular left first molar and premolar region. The lesion was bony hard and non-tender on palpation (Figure 4B).

A panoramic radiograph revealed of maxilla right side in left ramus with well-defined margins extending anteriorly till mandibular left first molar and posteriorly till the posterior border of ramus with a displacement of the lower border of mandible inferiorly. (Figure 4C).

CT scan revealed well defined, heterogenous, non-enhancing lesion in left ramus of the mandible with undulated borders. Thinning of the cortex was noted at some places in coronal section (Figure 4D). The internal structure showed mixed radiopaque-radiolucent areas with amorphous densities. In axial section, at some place the lesion was surrounded with well-defined radiolucency suggestive of capsulation around the lesion (Figure 4E).

Based on clinico-radiographic findings a provisional diagnosis of the Benign Odontogenic tumor was made. Histopathological findings suggestive of Ossifying Fibroma of left body and ramus of the mandible.

FIGURE 4

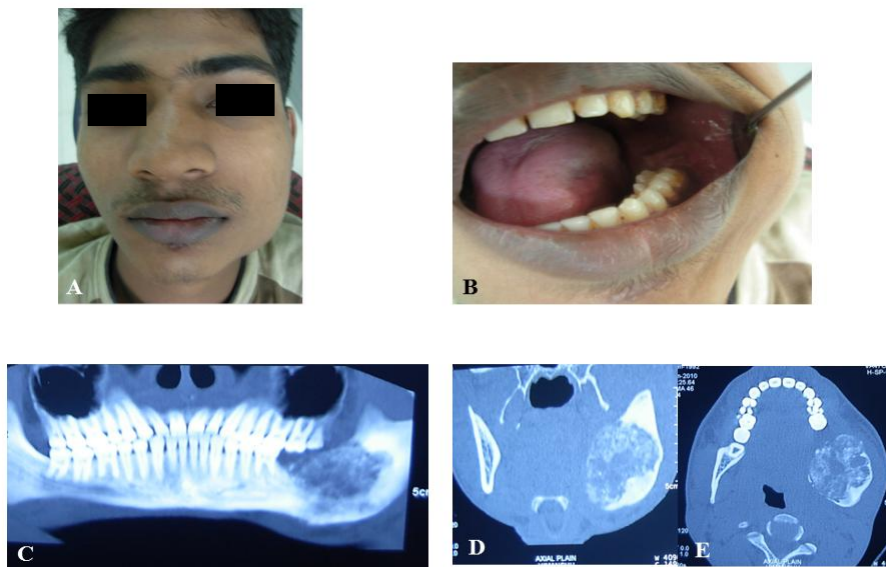


Figure 4, Case 4;

- A: Extra Oral Clinical photograph showing facial asymmetry on left side.
- B: Intraoral clinical photograph showing swelling on retromolar region left side.
- C: Panoramic radiograph showing osseous lesion involving the body and ramus of mandible left side.
- D: Coronal CT scan of lesion showing buccal expansion with cortical thinning involving ramus left side.
- E: Axial CT scan showing mixed radiopaque-radiolucent heterogeneous density (white arrow).

### Case Report 5:

A 10-year old female patient with complain of pain and swelling in right side of the face since 4 weeks. The swelling was initially smaller in size then gradually increased in size. The patient also complained of dull throbbing pain which was radiating to her right ear.

Extra oral examination showed facial asymmetry with diffuse swelling on the right side of the face, firm in consistency; smooth surfaced and non-tender on palpation (Figure 5A). Lymph nodes non-palpable.

Intraoral examination showed swelling extending from distal of maxillary right

lateral incisor to mesial aspect of maxillary right first molar causing buccal and palatal expansion and obliteration of buccal vestibule (Figure 5B). The swelling was hard, non-tender on palpation. Grade I mobility with lateral incisor was noted.

A panoramic radiograph revealed well-defined radiolucency in right side maxilla pushing the floor of maxillary sinus superiorly associated with impacted tooth. A dense radiopaque mass associated with the impacted tooth (Figure 5C).

CT scan revealed a mixed radiopaque-radiolucent lesion in right side of the maxilla with corticated borders extending superiorly till the right orbital

floor. The borders of right maxillary sinus were not traceable. Loss of continuity in the lateral wall of maxilla also noted internal structure showed some areas of calcification in coronal CT scan (Figure 5E). Axial CT scan showed buccal expansion with thinning of cortical plates extending from maxillary central incisor to maxillary first molar on right side.

Based on clinico-radiographic findings a provisional diagnosis of Fibro-osseous lesion of maxilla right side was made. Histopathological findings were suggestive of Juvenile ossifying fibroma of maxilla right side.

FIGURE 5

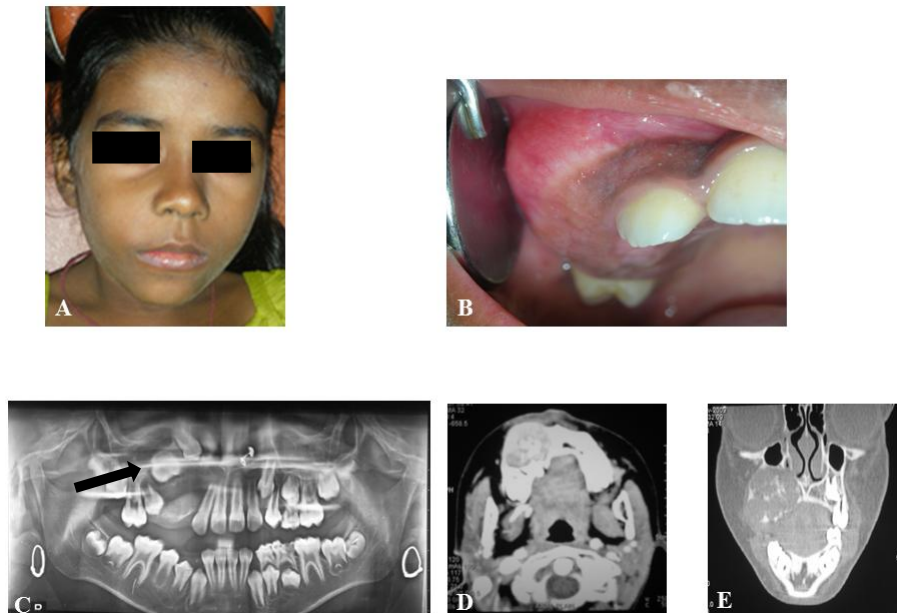


Figure 5, Case 5;

A: Extra Oral Clinical photograph showing facial asymmetry on right side.

B: Intraoral clinical photograph showing swelling on right side hard palate.

C: Panoramic radiograph showing unilocular radiolucency involving the maxilla and maxillary sinus right side, dense radiopaque mass associated with the impacted tooth (black arrow)

D: Coronal CT scan of lesion showing invagination of the lesion in maxillary antrum and extending into the nasal septum

E: Axial CT scan showing centre of lesion with flecks of calcification surrounded by radiolucency (white arrow)

### Case Report 6:

A 35 years old female patient reported with the chief complaint of a swelling on the left side of the mandible which gradually increased over the last 2 years.

Extra oral examination shows facial asymmetry on left side of the mandible

swelling was bony hard in consistency and non-tender on palpation (Figure 6A).

Intraoral examination revealed well-defined swelling, extending anteroposteriorly from mandibular left first molar to retromolar region with buccolingual expansion, with obliteration buccal vestibule (Figure 6B).

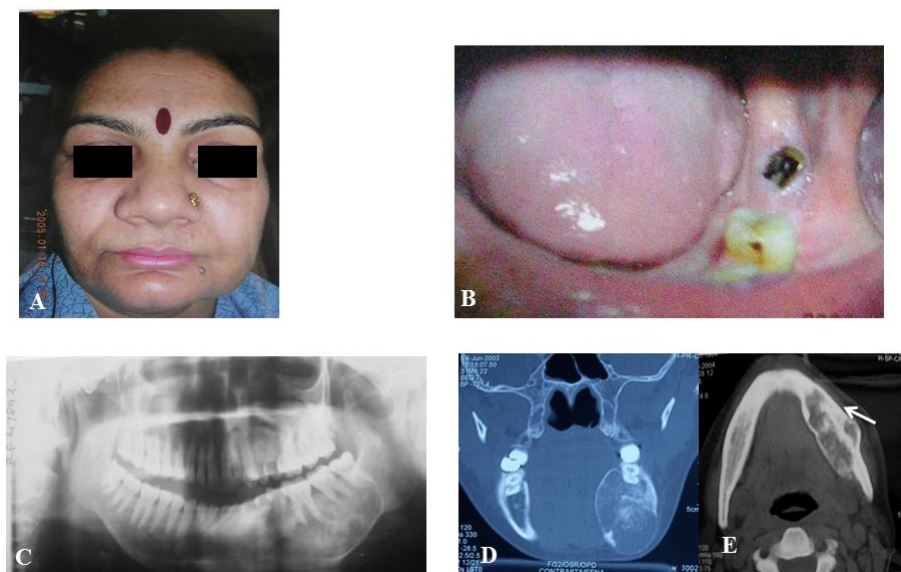
Panoramic radiograph showed a solitary well-defined radiolucency in the left

mandible with corticated borders, extending superoinferiorly from the superior alveolar margin of mandibular left premolar region to the inferior cortex of the mandible causing expansion of the inferior margin of the mandible at the body and angle with no discontinuity and inferiorly displaced inferior alveolar canal.(Figure 6C).

CT scan showed in axial section well-defined mixed radiopaque-radiolucency extending from distal to left

premolar to the anterior border of the angle of mandible region with marked expansion of lingual cortex compared to buccal cortex (Figure 6 E).In coronal section extension of the lesion from the crest of the alveolar ridge to the inferior border of the mandible with displacement, with buccolingual expansion of cortical plates, internal structure showed flecks of calcification in the center of the lesion with the radiolucent periphery. (Figure 6 D).

FIGURE 6



**Figure 6,** Case 6;  
 A:Extra Oral Clinical photograph showingFacial asymmetry on left side body of mandible B: Intraoral swelling on left side distal to mandibular left molar.  
 C: Panoramic radiograph showing osseous lesion involving mandible left side.  
 D: Coronal CT scan of lesion showing supero-inferior expansion with thinning of cortex without perforation  
 E: Axial CT scan showing centre of lesion with flecks of calcification surrounded by radiolucency (white arrow)

## DISCUSSION

The benign Fibro-osseous lesion is a condition in which normal bone is replaced with fibrous tissue constitutes anomalous bone or cementum [8] In 1971 the cementum containing lesions are classified into four types; fibrous dysplasia, ossifying fibroma, cementifying fibroma and cemento-ossifying fibroma by World Health Organization (WHO). [7] According to the second WHO classification, benign fibro-osseous lesions in the oral and maxillofacial regions were divided into two categories, osteogenicneoplasm, and non-neoplastic bone lesions; cementifying ossifying

fibroma belonged to the previous category. [8] However, the term “Cementifying ossifying fibroma” was reduced to Ossifying fibroma in the new WHO classification in 2005. [9]

Clinical features of Ossifying Fibroma can vary from inactive to aggressive behaviour. The features are more like those of tumour than bone dysplasia. [10] OF is asymptomatic slow growing lesion generally manifests in 2<sup>nd</sup> to 4<sup>th</sup> decade of life at the time of diagnosis ,though younger age group have also been affected. It exclusively affects craniofacial bone, mandible being the most common site of

involvement. it can also involve skull base and Para nasalsinuses and temporal bone. In our cases, three cases were located in mandible and two cases in the maxilla, two cases located both in maxilla and mandible. Three patients reported with intermittent painful swelling and two patients with painless swelling, one patient reported with extensive facial deformity involving the whole mandible and left side face. Case 2 there was involvement of temporal bone and Para nasal sinuses with extra oral bony hard swelling present in all the cases with clear boundaries. some authors has reported trauma in the area of the lesion, history of extraction and the prior existence of periodontitis as possible triggering factors. [11] In our study, Case 1 reported with a history of trauma 4 years ago on left body mandible and case 2 with a history of extraction with maxillary and mandibular right molar.

Benign tumors enlarge slowly by the formation of additional internal tissue. OF shows variation in internal structure based on the amount of mineralized tissue. The lesion appears initially as an osteolytic lesion followed by gradual transformation into the mixed lesion. The radiographic borders of the tumor appear relatively smooth, well defined, and sometimes corticated. The lesion tends to be concentric within the medullary part of the bone with centrifugal growth pattern with outward expansion of cortical plates equal in all direction without cortical plates perforation thus maintains the spherical shape. [10]

Ossifying fibroma of the maxilla is large and may expand freely within maxillary sinus. In mandible the tumor expands displacing inferior alveolar canal with a displacement of the involved tooth, resorption may occur. In our cases, tumor not only involves right maxilla but also affected the hard palate, the right maxillary antrum, right zygoma and even the floor of the right orbit. Juvenile ossifying fibroma (JOF) is another kind of aggressive form of benign tumor, similar to OF and of earlier onset. In our case 5 shows rapid growth

involved the right maxilla, the floor of maxillary antrum, and displacing the orbital floor. Diagnosed histopathologically as JOF.

Recent advances in imaging modalities in dentistry helps the dental practitioner to use the CBCT with the appropriate field of view and resolution, the internal mineralized structures of the pathology can be analyzed with a low dose. The three-dimensional scans establish accurate location and extent of the lesion. And even slight perforation of the cortical plates can be evaluated on CBCT scans. By using CBCT, discrimination of ossifying fibroma with other similar fibro-osseous lesion with mixed radiolucent-radiopaque densities can be done that exhibit similar internal calcification on conventional radiographs. In our cases, conventional radiographs like intraoral periapical radiograph and occlusal radiograph were not advised as the size of the lesion are large. The large lesions require a detailed assessment of the extent of the pathology, which can be obtained with CT or CBCT imaging. The clinical management of OF remains unpredictable. Small lesions can be treated conservatively by enucleation or curettage; large lesions require radical surgical resection as early as possible because OF is well circumscribed can be enucleated easily at surgery, but maxillary OF are more difficult to remove completely than mandibular lesion. This may be due to the difference in bone integrity between maxilla and mandible and the available space for expansion in maxillary antrum. Relapse rate varies from 6% to 28 % for mandible and relapse rate of the maxilla is unknown but it is probably higher because of the difficulty of their surgical removal. [1,12] The overall prognosis with most types of OF appears to be good.

## CONCLUSION

Ossifying Fibroma uncommon tumor can present a diagnostic dilemma for the dental surgeon and the pathologist, hence it needs to be correlated with radiographic features. The early diagnosis



and management of this tumor are of utmost importance to limit the progression and to reduce the morbidity of the patient. In the present case report, advanced imaging modalities played an important role in determining the extent of the lesion thus aid in timely diagnosis and management.

#### REFERENCES

1. S.M. Gondivkar et al. Ossifying fibroma of the jaws: Report of two cases and literature review. *Oral Oncology* 47 (2011) 804–809
2. Montgomery AH. Ossifying fibroma of the jaw. *Arch Surg* 1927; 15:30–44.
3. Sherman RS, Sternberg WC. Roentgen appearance of ossifying fibroma of bone. *Radiology* 1948; 50:295–309.
4. Hamner 3rd JE, Scofield HH, Cornyn J. Benign fibro-osseous jaw lesions of Periodontal membrane origin: An analysis of 249 cases. *Cancer* 1968; 22:861–78.
5. Waldrom CA. Fibro-osseous lesions of the jaws. *J Oral Maxillofac Surg* 1993; 51:828–35.
6. Eversole R, Su L, ElMofty S. Benign fibro-osseous lesions of the craniofacial complex. A review. *Head Neck Pathol* 2008;2:177–202.
7. Pindborg JJ, Kramer IRH. Histological typing of odontogenic tumors, jaw cysts and allied lesions. In: International histological classification of tumors. Geneva: WHO, 1971, pp 31–34.
8. Kramer IRH, Pindborg JJ, Shear M. Neoplasm and other lesions related to bone. Histologic typing of odontogenic tumors, World Health Organization. Berlin, Springer-Verlag 1992: 28–31.
9. Reichart PA, Philipsen HP, Sciubba JJ. The new classification of Head and Neck Tumours (WHO) – any changes? *Oral Oncol* 2006; 42: 757–758.
10. White SC, Pharoah MJ, Oral Radiology Principles and interpretation 6<sup>th</sup> edition p.440-441
11. Martín-Granizo R, Sánchez-Cuellar A, Falahat F. Cemento ossifying fibroma of the upper gingivae. *Otolaryngol Head Neck Surg* 2000; 122:775.
12. Eversole LR, Leider AS, Nelson K. Ossifying fibroma: a clinicopathologic study of sixty-four cases. *Oral Surg Oral Med Oral Pathol* 1985; 60:505–11.

How to cite this article: Johaley S, Karjodkar FR, Sansare KP et al. Ossifying fibroma of jaw: a clinico-radiographic case series. *Int J Health Sci Res.* 2017; 7(10):269-277.

\*\*\*\*\*