

Original Research Article

A Correlative Study on Fine Needle Aspiration and Histopathology of Thyroid Lesions

Malliga S¹, Vijayalakshmi A², Visalakshi P¹

¹Associate Professor, ²Assistant Professor,
Department of Pathology, Govt Sivagangai Medical College, Sivagangai.

Corresponding Author: Malliga S

Received: 28/07/2016

Revised: 22/08/2016

Accepted: 24/08/2016

ABSTRACT

The main purpose of thyroid fine needle aspiration is to distinguish between patients with malignant thyroid nodule who requires surgery and those with benign nodules that can be followed clinically or treated medically. The aim of this study is to know the incidence of fine needle aspiration cytology in thyroid enlargement in our institution and to correlate the cytology and histopathological diagnosis of thyroid lesions. Patients with thyroid enlargement referred from clinical departments were included in the study. Patients of thyroid swelling with toxic features and in severe respiratory distress were excluded. FNAC and histopathological study were done in 97 cases and the sensitivity, specificity and diagnostic accuracy were calculated. In our study the sensitivity was 87.9%, specificity 96.1% and the diagnostic accuracy was 91.7%. As the technique is minimally invasive, produces a speedy result and is inexpensive. Thyroid FNAC may be considered as first line diagnostic tool in patients with thyroid swelling.

Key words: FNAC, histopathology, multinodular goiter.

INTRODUCTION

Fine aspiration cytology was initially performed to confirm a clinical suspicion of local recurrence or metastasis of known cancer without subjecting the patient to further surgical intervention. Following success in this area, FNAC was applied as a preoperative diagnostic tool in all kinds of neoplastic processes, benign or malignant in any organ or tissue of the body. It is also valuable in the diagnosis of inflammatory, infectious and degenerative diseases. [1]

As the technique is simple, cost effective and has increased diagnostic accuracy, it becomes the first line diagnostic test in all thyroid lesions. FNAC of thyroid lesions are helpful in avoiding unnecessary thyroidectomies in benign and non-neoplastic lesions.

In non- iodine deficient region the prevalence of palpable thyroid nodules ranges from 4-7 % in the general adult population and from 0.2 to 1.5 % in children. [2,3] Prevalence of malignancy in solitary thyroid nodules ranges from 10% to 44.7%. The main purpose of thyroid fine needle aspiration is to distinguish between patients with malignant thyroid nodule who requires surgery and those with benign nodules that can be followed clinically or treated medically. Other specific indications of FNA are evaluation of diffuse goiter and follow up of individuals exposed to irradiation of head and neck. [2] With FNA, number of thyroidectomies has been reduced and the incidence of malignant lesions has been doubled.

The aim of the study is know the diagnostic accuracy of fine needle aspiration cytology in correlation with histopathology of thyroid lesions. Study was conducted after obtaining permission from institutional ethical committee. Patients referred for FNAC from clinical departments were included in the study. The incidences of thyroid swelling in our institution were measured. After surgery histopathology reports were correlated with previous cytology and the sensitivity, specificity and diagnostic accuracy were calculated.

MATERIALS AND METHODS

The present study was conducted in Department of Pathology, Govt Sivagangai Medical College for the period of two years from May 2014-June 2016. Fine needle aspiration of thyroid swelling was performed by using 23-24 gauge needles either with attached syringe or non aspiration technique. The aspirated material was placed on glass slides and fixed with Isopropyl alcohol. The smears were stained with Haematoxylin- Eosin stain and studied by pathologist. After surgery fixed specimens were received from surgery department, HPE examination was done and the results were compared. The sensitivity, specificity, diagnostic accuracy, positive predictive value and negative predictive value were calculated.

OBSERVATION AND RESULTS

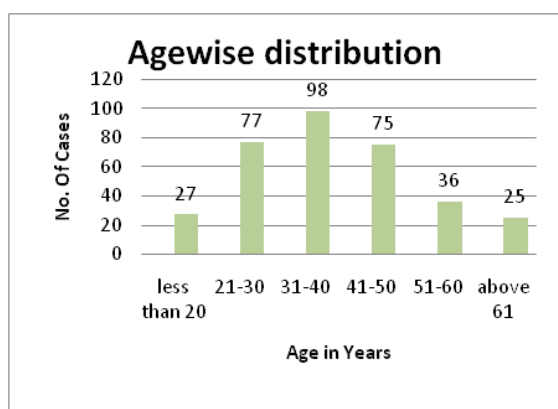


Chart 1: Age wise distribution

In the two year study period totally 1114 FNA were performed for various

palpable swellings, among them 338 cases were for thyroid enlargement. Among them 317 were female and 21 were male with M: F ratio of 1:15. The average incidence of thyroid FNAC of our institution was 30.3%. Commonest age group of patients was between 31-40 years and the youngest was 8years and elderly one was 85 years. The mean age of patients suffered with thyroid swelling was 39 years. (Chart 1)

Among the 338 cases, non neoplastic lesion was the commonest lesion which accounts for 303 cases (89.6%) followed by neoplasm 19 cases (5.6%) and scanty aspirate in 16 cases. (Table 1) Post surgical histopathological examination was done for 97 cases. Correlative study was done in these patients.

Table 1: Lesion wise distribution of cases

Lesion	No. of cases	Percentage
Colloid goiter	115	34
Nodular colloid goiter	68	20.1
NCG with cystic degeneration	34	10
NCG with papillary hyperplasia	11	3.2
Hashimoto thyroiditis	62	18.3
Hurthle cell lesion	2	0.59
Granulomatous lesion	1	0.29
Cystic lesion	10	2.9
Follicular neoplasm	7	2.07
Papillary carcinoma	10	2.9
Medullary carcinoma	1	0.29
Anaplastic carcinoma	1	0.29
Unsatisfactory	16	4.71
Total	338	

Table 2: FNAC results

Cytology	No. of cases	Percentage
Nodular Colloid goiter	52	53.60
Colloid goiter	21	21.64
Nodular goiter with papillary hyperplasia	5	5.15
Hashimoto thyroiditis	6	6.18
Cystic lesion	2	2.06
Follicular neoplasm	3	3.09
Papillary carcinoma	4	4.12
Anaplastic carcinoma	1	1.03
Unsatisfactory	3	3.09

In cytology (Table 2) 86 cases were reported as non neoplastic lesion among those 75 cases were confirmed in histopathology (Table 3). 11 cases were false negatively given as non neoplastic, but histopathology revealed follicular adenoma in 7 cases. Micro papillary carcinoma was seen in 2 cases and 2 cases of papillary carcinoma.

8 cases were diagnosed as neoplastic and 5 were confirmed, of which 4 papillary carcinoma and 1 anaplastic carcinoma. 3 were false positively reported as malignancy but found to be multinodular goiter with adenomatous change.

Three were shown scanty aspirate in cytology and no opinion was given. In histopathology two cases were found to be multinodular goiter with degenerative changes and one was micropapillary carcinoma.

Table 3: HPE diagnosis

Histopathology	No. of cases	percentage
Multinodular goiter	73	75.25
Hashimoto thyroiditis	6	6.18
Thyroglossal cyst	1	1.03
Follicular adenoma	7	7.21
Papillary carcinoma	9	9.27
Anaplastic carcinoma	1	1.03

The sensitivity was 87.9%, specificity 96.1% and the diagnostic accuracy was 91.7%. The positive predictive value was 96.38% and the negative predictive value was 87.2%.

DISCUSSION

FNA of thyroid is the first line procedure fully accepted in the diagnostic workup of patients with thyroid enlargement in addition to other traditional methods. [2] In non iodine deficient region the prevalence of palpable thyroid nodules ranges from 4-7 % in the general adult population and from 0.2 to 1.5 % in children. [2,3] The main indication for FNA thyroid is to identify the nodule whether it is benign or malignant. The other indications are evaluation of diffuse goiter; follow up of individuals exposed to irradiation in the head and neck region.

Table 4:

Study	Sensitivity	Specificity
Akila Sekar et al [5]	84.62%	99.26%
Dipanwita Das et al [6]	83.3%	80%
Rupam Borgohain et al [7]	82.14%	86.81%
Nepali R et al [8]	91.6%	97.29%
Our study	87.9%	96.1%

In our study the sensitivity was 87.9%, specificity 96.1% and the diagnostic accuracy was 91.7%. The results are correlating with the study conducted by

Akila Sekar et al, [5] Dipanwita Das et al, [6] Rupam Borgohain et al [7] and Nepali R et al. [8] (Table 4)

The positive predictive value was 96.38% and the negative predictive value was 87.2%.

Table 5

Study	PPV	NPV
Rupam Borgohain et al [7]	65.71	94.04
Nepali R et al [8]	91.66	97.29
Our study	96.38	87.20

False negative diagnosis of follicular neoplasm as nodular colloid goiter and false positive reporting of adenomatous goiter as follicular neoplasm was the reason for low sensitivity and diagnostic accuracy in our study. Studies have shown that the false negative rate of cytological diagnosis of follicular neoplasm may be 30% or more. [9]

Selective sampling of microfollicular focus in nodular goiter with repetitive pattern of microfollicles or rosettes with no colloid makes us misdiagnose nodular colloid goiter as follicular neoplasm. [10]

In follicular neoplasm when follicular cells are mixed with colloid, the cellularity will be reduced because of dilution and make it difficult to differentiate from multinodular goiter. When the follicular cells are seen in syncytial clusters we have to look for the nuclear crowding and overlapping which will suggest a neoplasm. [11]

In evaluating single nodular lesions, when the nodule is less than 3cm one to four aspirates are enough. If the lesion is larger four to eight aspirations may considerably reduce false negative results. [4]

Aspiration under ultrasound guidance for those patients where the nodule is deeply located in the neck and cytology yields no cellular material will increase the diagnostic accuracy. [12]

CONCLUSION

The technique is minimally invasive, produces a speedy result and is inexpensive. Results and accuracy are highly dependent on the quality of samples and smears. By

improving the technique of aspiration, with good interpretation skill and correlating with other investigatory findings the accuracy of fine needle aspiration cytology can be increased further.

Fine needle aspiration of thyroid enlargement has considerably reduces the unwanted surgery in many centers around the world. At the same time the diagnosis of malignancy in surgical specimens has doubled. Cytology has definitely has a role in reducing unnecessary thyroidectomies and revealing unsuspected malignancies.

REFERENCES

1. Gita J, Orell SR. Thyroid. In: Orell SR, Sterrett GF, editors. Fine Needle Aspiration Cytology. 5th ed. Philadelphia: Churchill Livingstone; 2012.118-55.
2. Hugo Galera-Davidson and Richardo Gonzalez - Campora. Comprehensive cytopathology. 3rd edition. Saunders; Elsevier:
3. Layfield LJ, Cibas ES, Ghariab H, Mandel SJ. Thyroid aspiration cytology: current status. CA cancer J clin 2009; 59: 99-1190.
4. Hamburger H, Husain M, Nishiyama R, et al. increasing the accuracy of fine needle of thyroid nodules. Arch pathol Lab Med 1989; 113:1035-1041.
5. Akhila Sekhar¹, Inamda S.S, V.D. Dombale, Prabhu M.H. Fine Needle Aspiration Cytology Study of Thyroid Lesions-A 2 year prospective study in a Tertiary centre. International Journal of Pharmaceutical and Biological Science Archive Volume 3 Issue 1; 2015, Page No.15-19.
6. Dipanwita Das, MC Sharma, Aditya Sharma et al. A comparative study between FNAC and HPE in the diagnosis of neoplastic and nonneoplastic lesions of thyroid gland. SSN-0301-1216 Indian J. Prev. Soc. Med. Vol. 43 No 1, 2012.
7. Rupam Borgohain¹, Ranjeet Kumar Lal, Pritam Chatterjee, Nancy Brahma, Swagata Khanna. A Study of Cyto-Histological Correlation in the Diagnosis of Thyroid Swelling. IOSR Journal of Dental and Medical Sciences. Volume 13, Issue 11 Ver. IV (Nov. 2014), PP 46-49.
8. Nepali R, Banita V, Thakur G. Comparative Study of FNAC and Histopathology in the Diagnosis of Thyroid Swelling. The Internet Journal of Head and Neck Surgery. 2012 Volume 5 Number 2.
9. Cusick EL, Macintosh CA, Krukowski ZH et al. Management of isolated thyroid swellings. A prospective six years study of fine needle aspiration cytology in diagnosis. Br Med J 1990; 301:308-21.
10. Droese M. Cytological aspiration biopsy of thyroid gland, 2nd edition. Stuttgart; schattauer: 1995.
11. Suen KC. How does one separate cellular follicular lesions of the thyroid by fine needle aspiration cytology? Diagn cytopathol 1998; 4:78-81.
12. Danse D, Sciaahitano S, Farsetti A, et al. Diagnostic accuracy of conventional versus sonography guided fine needle aspiration of thyroid nodules. Thyroid 1998; 8:15-21.

How to cite this article: Malliga S, Vijayalakshmi A, Visalakshi P. A correlative study on fine needle aspiration and histopathology of thyroid lesions. Int J Health Sci Res. 2016; 6(9):122-125.
