

Original Research Article

Duplication of Extrahepatic Bile Duct: A Challenge to Surgeons

Sagar Kurunkar¹, Chetan Kantharia², Mirza Beg Kasim¹, Sharvar Pujari³, Ramkrishna Prabhu⁴

¹Registrar, ²Head of Department and Professor, ³Assistant Professor, ⁴Associate Professor, Department of Surgical Gastroenterology, Seth GS Medical College and KEM Hospital, Mumbai.

Corresponding Author: Sagar Kurunkar

Received: 26/06/2016

Revised: 07/08/2016

Accepted: 08/08/2016

ABSTRACT

Biliary anatomical variation is a common variation seen in human body but duplication of extrahepatic bile duct is rare. Precise knowledge of this variation helps in preventing serious complications during surgery of the biliary tract. The present article reviews this rare anomaly and its management.

Key words: Duplication of extrahepatic bile duct, anatomical variation.

INTRODUCTION

Conventional biliary anatomy is believed to be present only in 50 to 60% of the population with more than 40% of patients show anatomical variations in their biliary anatomy though mostly pertaining to the intra-hepatic biliary system.

In contrast, duplication of the extrahepatic bile duct is a rare congenital variant that has been rarely reported, with very few cases reported in literature.

Though prior knowledge of this variant is important prior to surgery, most often they come to notice either during surgery or post-operatively when patient present with recurrent symptoms pertaining to biliary system. This is because, the preoperative diagnostic work up for Laparoscopic Cholecystectomy, which mainly comprises of Ultrasonography of the abdomen, can seldom diagnose this anomaly. ⁽¹⁾ However, a wide spectrum of biliary tree malformations along with pancreatic anomalies can be recognized by radiologic investigations such as MRI, MRCP and multi-detector or helical CECT scan have improved image quality greatly

and have contributed to increased recognition of these anatomical variations. ⁽²⁾

The present study highlights the anatomical variations and congenital anomalies of the extra hepatic biliary system encountered by us during surgeries on biliary tract.

MATERIALS AND METHODS

This is a retrospective observational study carried out at a premier teaching institute over the last three years from 2013 to 2016.

Records and data of the patient undergoing open surgery for biliary tract were reviewed.

278 patients were subjected to surgeries on biliary tract during the said period, whose biliary anatomy was studied.

Of these three patients were identified to have extra-hepatic bile duct duplication. These patients were studied for their demographics, type of anomaly, their presentation, whether history of previous surgery, their intra-operative findings and the surgical intervention done

The extra-hepatic bile duct duplication anomalies were classified into five types as proposed by Choi et al.

All the three patients were subjected to MRI with MRCP prior to intervention

Two patients presented with recurrent symptoms post laparoscopic

cholecystectomy. One patient presented with calculuscholecystitis with cholangitis. Out of these three patients two had cholangitis at their presentation. Their profile is as given below in table I.

Table I: Patients' Profile.

Pt	Age	Sex	Presenting Complaints	Previous surgery	MRCP findings	Intra-op findings	Surgical intervention
1	50	F	Biliary colic	Laparoscopic cholecystectomy 7 yrs back	Lower cbd calculi Left duct calculi Abnormality: Type V-a	Right and left duct joining lower down near duodenum	Hepatico- dochojunostomy
2	65	F	Biliary colic and Cholangitis	Laparoscopic cholecystectomy 4 years back	Dilated IHBR, calculi in proximal right and left duct Abnormality: Type III-a	Right and left duct opening separately in duodenum	Hepatico- dochojunostomy
3	60	F	Calculous cholecystitis with cholangitis	No previous surgery	Calculus in proximal right hepatic duct. Abnormality: Type III-a	Cystic duct opening into right hepatic duct. Right and left duct opening separately in duodenum.	Open cholecystectomy and Hepatico- dochojunostomy

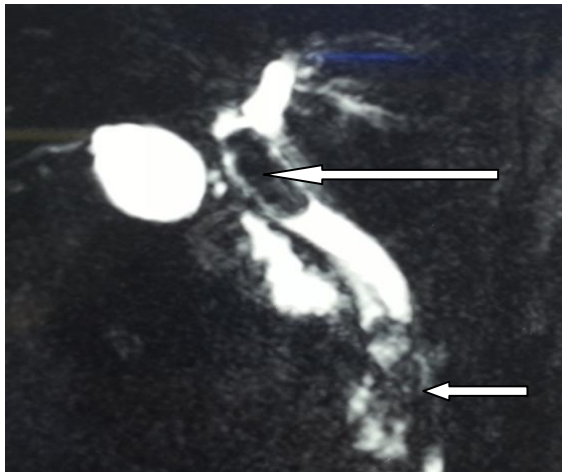


Figure I: MRCP picture showing, 1 cm calculi in lower CBD (short arrow) and calculi in left duct (long arrow). Right and left duct joining lower down without any communication between right and left duct suggestive of type V-a anomaly.

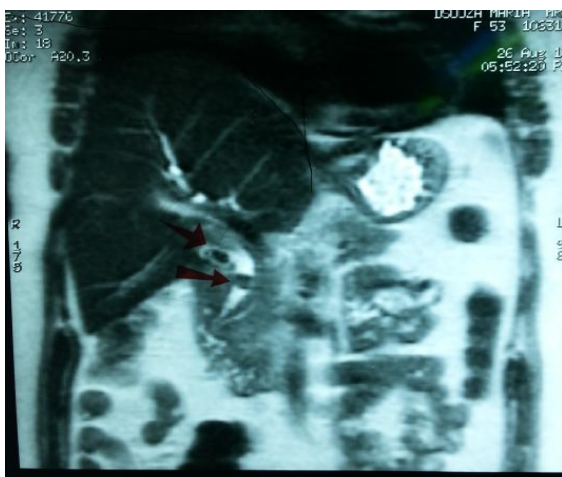


Figure II: MRI picture showing filling defects one in lower CBD and other in left duct

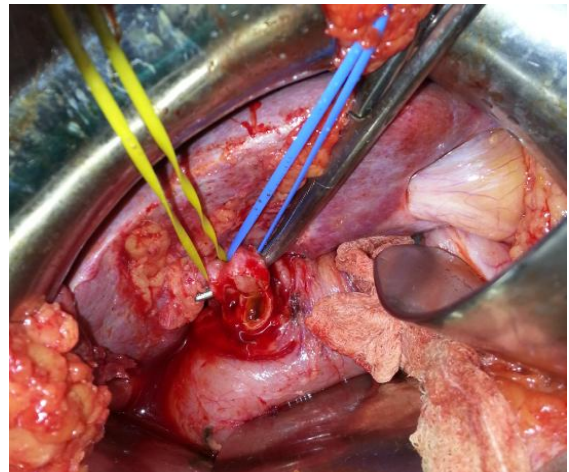


Figure III: Intraoperative picture showing both right and left duct in supraduodenal part, both ducts joining lower down to form CBD

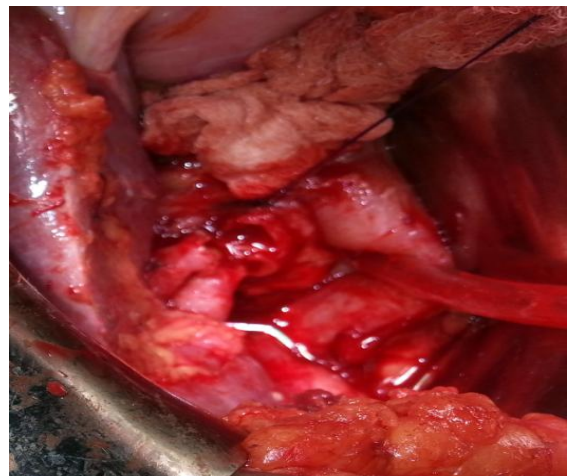


Figure IV: Intraoperative picture of type V-a anomaly of duplication of bile duct

RESULTS

Of the 278 number of the surgeries performed on biliary system during the study period, 3 patients (1.07%), (all females, age range 50-65 years, median age being 60 years) were found to be having duplication of extrahepatic bile duct.

Their clinical presentation was choledocholithiasis in two patients while one patient had calculus cholecystitis. Two patients had associated Cholangitis.

Out of three two patients underwent previous surgery in form of laparoscopic cholecystectomy and one patient didn't undergo any surgical intervention previously.

MRI with MRCP done prior to intervention revealed Type III-A type of variation in two patients and Type V variation in one.

ERCP couldn't clear the stones in these patients due to difficulty in identification of duct and stones present higher up in biliary system.

All the three patients were subjected to open surgical intervention hepaticoduchojunostomy.

All three patients recovered well and discharged, on regular follow up.

DISCUSSION

Bile duct duplication although a normal feature in reptiles, fish, and birds, is a rare congenital anomaly of the human biliary system. The presence of double bile duct is a normal step during development of embryo; however, this primitive duplicated system regresses to form the standard anatomy consisting of a single common bile duct. Duplication of the common bile duct in humans was first reported in 1543 by Vesarius and until 1986 only 24 cases were reported in the Western literature. (3)

This distinct anomaly has been reported in association with anomalous bilio-pancreatic junction, congenital choledochal cyst, and biliary atresia and can predispose to complications such as choledocholithiasis, cholangitis, pancreatitis, and malignancies, including

cholangiocarcinoma and cancer of the upper gastrointestinal tract. (4-8)

The basic knowledge of embryologic development and normal anatomy of biliary tree will help in understanding and identifying this group of anomalies. (9) Biliary tree develops from hepatic diverticulum which gives rise to gallbladder, extra-hepatic ductal system with hepatic parenchyma whereas intrahepatic ducts are derived from endoderm at the tip of diverticulum. The accessory anomalies or aberrant bile ducts may result when interconnecting ducts persists. (10) The extra hepatic bile duct system is divided into four topographic portions. Cystic duct and gall bladder, right and left hepatic ducts, common hepatic and bile duct including its supra and retro-duodenal parts and the pancreatic and intraduodenal portions. (11)

Congenital duplication of the common bile duct is an extremely rare anomaly of the biliary tract, which represents failure of regression of the embryological double biliary system.

Depending on the morphology of the duplicated bile duct, the anomaly can be classified into five distinct subtypes as per the modified classification proposed by Choi et al (12) as shown in figure V.

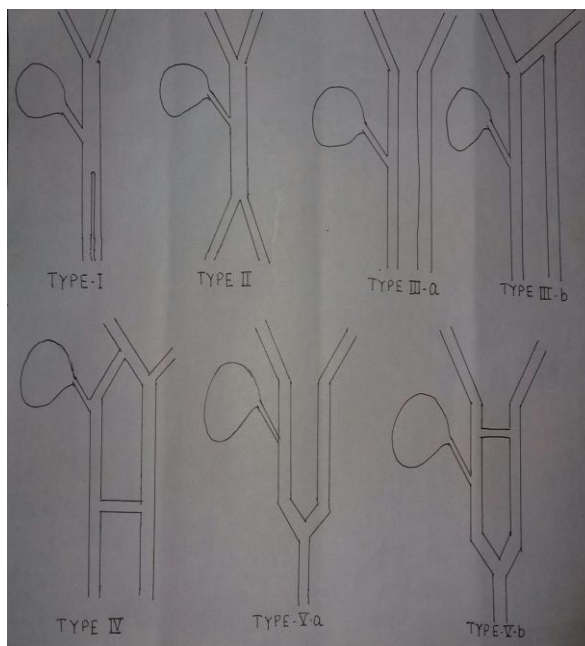


Figure V: Modified classification of extrahepatic bile duct duplication proposed by Choi et al.

- Type I - CBD with a septum in the lumen;
- Type II - CBD that bifurcates and drains separately;
- Type III - Double biliary drainage without extrahepatic communicating channels (without [a] or with intrahepatic communicating channels [b]);
- Type IV - Double biliary drainage with one or more extra hepatic communicating channels;
- Type V - Single biliary drainage of double extrahepatic bile ducts without (a) or with communicating channels (b).

Literature review reveals very limited data on this rare anomaly. Most of the reports are from Asia, especially from Japan, with Kanematsu *et al* in 1992 reporting 56 cases⁽¹³⁾ and Yamashita *et al.* reporting 46 cases.⁽³⁾ A high incidence of these cases in this region may be attributed to the ethnicity. Type V anomaly is one of the rarest in these variations with hardly any cases reported of this type of anomaly.

In the present study we came across 2 cases of type III-a and one case of type V-a anomaly which is one of the rarest anomaly of duplication of extrahepatic biliary system, with very few cases reported in the literature to date. We managed 2 patients who presented with cholangitis medically and subjected to surgical intervention later. Doing therapeutic ERCP in these patients with duplicated biliary system is herculean task since it is very difficult to locate the papilla and after that accessing the right and left duct is challenging. We tried ERCP in all these patients but we could not succeed to clear the stones from biliary system due to difficulty in identification of duct and also stones present higher up in biliary system.

All these three patients underwent hepaticoduchojejunostomy where we anastomosed right and left duct side to side and that was anastomosed to roux limb of jejunum. Along with this one patient

underwent cholecystectomy in whom cystic duct was draining into right hepatic duct.

Knowledge of this aberrant biliary anatomy if obtained prior to surgery helps to plan the surgery and prevent accidental ductal injuries. The accessory duct can be confused for cystic duct and its ligation leads to biliary obstruction. Pre-operative MRCP leads to increased recognition of these conditions which helps in therapeutic intervention. In the present study 2 of three patients had undergone laparoscopic cholecystectomy prior, and had presented to us at a later date with symptoms of either cholangitis or choledocholithiasis. In view of previous history of surgery and the presenting symptoms, they were subjected to MRCP which helped us to recognize the variant preoperatively and helped us in planning their management. We tried ERCP in all these patients but we could not succeed to clear the stones from biliary system due to difficulty in identification of duct and also stones present higher up in biliary system. Obviously these anomalies were missed during primary surgery and were detected because of the imaging in form of MRI with MRCP.

This anomaly is commonly complicated by Cholelithiasis, choledocholithiasis, cholangitis, pancreatitis, and cholangiocarcinoma.⁽¹⁴⁾ Hence it is important to keep a differential of extrahepatic biliary anomaly in mind in patients presenting with choledocholithiasis or cholangitis post cholecystectomy. In all these patients doing therapeutic ERCP is very difficult and most of these patients require surgical intervention. Also, it is imperative to note the site of opening of the accessory biliary duct as this heralds biliary and pancreatic reflux with chronic irritation and is associated with the site-specific malignancies as gastric, duodenal, and gall bladder malignancies. This anomaly merits surgical intervention when they present with complications, following which they do well as in our three cases.

CONCLUSION

Duplication of Extra-hepatic Bile duct is a rare anomaly. Preoperative MRCP not only helps us in recognizing this anomaly but also in planning of management and avoiding intra-operative complications.

REFERENCES

1. Carbajo MA, Martin del Orono JC, Balanco JI, Cuesta C, Martin F, Toledano M, et al. Congenital malformations of gallbladder and cystic duct diagnosed by laparoscopy: high surgical risk. *JLS* 1999; 3: 319-21.
2. Marcos A. Right lobe living donor liver transplantation, a review. *Liver Transpl* 2000; 6:3-20.
3. Yamashita K, Oka Y, Urakami A, Iwamoto S, Tsunoda T, Eto T. Double common bile duct: A case report and a review of the Japanese literature. *Surgery*. 2002; 131:676-81.
4. Catalano OA, Singh AH, Uppot RN, Hahn PF, Ferrone CR, Sahani DV. Vascular and biliary variants in the liver: Implications for liver surgery. *Radiographics*. 2008;28:359-78
5. Gupta V, Chandra A. Duplication of the extrahepatic bile duct. *Congenit Anom (Kyoto)* 2012;52:176-8
6. Chen G, Wang H, Zhang L, Li Z, Bie P. Double common bile duct with choledochal cyst and cholelithiasis: Report of a case. *Surg Today*. 2014; 44:778-82.
7. Kim SW, Park do H, Shin HC, Kim IY, Park SH, Jung EJ, et al. Duplication of the extrahepatic bile duct in association with choledocholithiasis as depicted by MDCT. *Korean J Radiol*. 2008;9:550-4
8. Park MS, Kim BC, Kim Ti, Kim MJ, Kim KW. Double common bile duct: Curved-planar reformatted computed tomography (CT) and gadobenatadimeglumine-enhanced MR cholangiography. *J MagnReson Imaging*. 2008;27:209-11
9. Mortelet KJ, Rocha TC, Streeter JL, Taylor AJ. Multimodality imaging of pancreatic and biliary congenital anomalies. *Radiographics* 2006; 26: 715-31.
10. Schulte S J. Embryology, normal variation and congenital anomalies of pancreas. In: Margulis and Burhenne's alimentary tract radiology. 5th ed. St Louis: Mo Mosby, 1994; 1039-51.
11. Chen WJ, Ying DJ, Liu ZJ, He ZP. Analysis of the arterial supply of the extrahepatic bile ducts and its clinical significance. *Clin Anat* 1999; 12: 245-9.
12. ChoiE,Byun JH, Park BJ, Lee MG. Duplication of the extrahepatic bile duct with anomalous union of the pancreaticobiliary ductal system revealed by MR cholangiopancreatography. *Br. J. Radiol*. 2007; 80: E150-E154.
13. Kanematsu M, Imaeda T, Seki M, Goto H, Doi H, Shimokawa K. Accessory bile duct draining into stomach: Case report and review. *Gastrointest Radiol*. 1992; 17:27-30.
14. Djuranovic SP, Ugljesic MB, Mijalkovic NS, Korneti VA, Kovacevic NV, Alempijevic TM, et al. Double common bile duct: A case report. *World J Gastroenterol*. 2007; 13:3770-2.

How to cite this article: Kurunkar S, Kantharia C, Kasim MB et al. Duplication of extrahepatic bile duct: a challenge to surgeons. *Int J Health Sci Res*. 2016; 6(9):70-74.
