

Case Report

Management of Splenic Artery Aneurysm in Extra- Hepatic Portal Hypertension

Praveen Kumar R Bhat, Ramkrishna Yeshwant Prabhu, Apurv Ashokrao Deshpande, Sharvari Gopal Pujari, Chetan Vinod Kantharia

Department of Surgical Gastroenterology, Seth GS Medical College and KEM Hospital, Parel, Mumbai, India.

Corresponding Author: Praveen Kumar R Bhat

Received: 03/02/2016

Revised: 14/03/2016

Accepted: 22/03/2016

ABSTRACT

Splenic artery aneurysm (SAA) is commonest visceral artery aneurysm. Prevalence and precise etiology are not known. We present two cases of extra-hepatic portal vein (EHPV) thrombosis with portal hypertension (PH) presenting with SAA managed successfully.

51 year male, EHPV thrombosis with PH, on regular endoscopy, presents with dull aching pain in left upper abdomen. Contrast CT showed large trilobed saccular aneurysm of splenic artery. Patient underwent distal pancreatectomy with splenectomy. Second patient was asymptomatic 27 year male, with EHPV thrombosis with PH, on regular endoscopic follow-up. CT angiography revealed aneurysm of splenic artery near splenic hilum. Patient underwent splenic artery ligation proximal to aneurysm with devascularization.

SAA more than 2 cm needs treatment. Limited information is available in literature regarding management in patients with EHPV thrombosis and SAAs. Though proximal spleno-renal shunt is ideal, with no shuntable vessels, devascularization with splenectomy and excision of SAA is valid option.

Key words: Extra-hepatic portal hypertension, splenic artery aneurysm, aneurysmectomy, devascularization.

INTRODUCTION

Splenic artery aneurysm (SAA) is the most common visceral artery aneurysm and third most common intra-abdominal aneurysm after abdominal aorta and iliac artery. ^[1,2] True prevalence of SAA, though not known, ranges from 0.2 - 10.4%. ^[3,4] With wider use of cross sectional imaging, incidental diagnosis is done with increased frequency. ^[5] Precise etiology is unknown. Hemodynamic changes play an important role in pathogenesis of SAA ^[6] in patients with portal hypertension (PH). We present two cases of extra hepatic portal vein (EHPV) thrombosis with PH presenting with SAA, managed successfully by surgery.

CASE REPORTS

Case 1

51 year male patient, known case of EHPV thrombosis with PH since teenage, presented with dull aching pain in left upper abdomen - since 6 months. He had mild icterus, splenomegaly reaching 2 cm above the umbilicus. Blood investigations showed no evidence of hypersplenism. Serum bilirubin was 2.1 mg/dL, with direct being 1.1 mg/dL; normal transaminases and alkaline phosphates and serum albumen. Contrast enhanced CT (CECT) (Fig.1) revealed peri-gastric and splenic hilar collaterals; EHPV, splenic vein and superior mesenteric vein replaced by collaterals and 6.2 x 4.2 x 4cm trilobed saccular aneurysm

of the splenic artery with intra luminal thrombus. Upper GI endoscopy showed large esophageal varices, endoscopic banding of these varices done. Patient was planned for aneurysmectomy with splenectomy and esophago-gastric de-vascularization. Intra-operatively the aneurysm was adherent to the pancreas. Splenic artery was ligated 1 cm distal to its origin and distal pancreatectomy with splenectomy with esophago-gastric de-vascularization was done (Fig.2). Post-operatively, patient developed ascites, which responded to diuretics, otherwise an uneventful recovery.

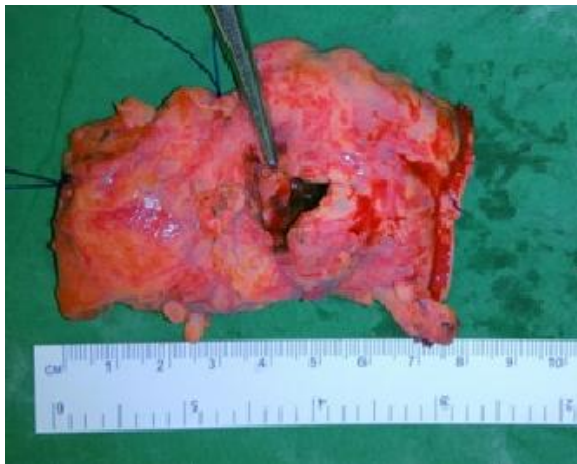

Fig 2. Case 1, Operative Specimen - Posterior aspect of distal pancreatectomy specimen with the splenic artery aneurysm. The artery forceps pointing to the opening made on the aneurysm.

Case 2

27 years male patient, known case of EHPV thrombosis with PH, diagnosed 9 years back, on regular endoscopic follow-up, asymptomatic. Routine follow-up endoscopy showed large esophageal varices, band ligation of these was done. Doppler USG of the abdomen was done, which showed an aneurysm of the splenic artery near its distal end with other findings confirming PH. On clinical examination, spleen was palpable 8 cm below the costal margin. Blood investigations showed features of hypersplenism. CECT abdomen revealed that portal vein and splenic veins were replaced by collaterals, peri-esophageal and peri-gastric varices and 3 x 2 cm aneurysm of the splenic artery near the hilum of the spleen. The superior mesenteric

vein was 6 mm in diameter. Patient underwent ligation of the splenic artery proximal to the aneurysm with de-vascularization procedure. Post-operatively, patient developed ascites, managed with diuretics, otherwise uneventful post-operative course.

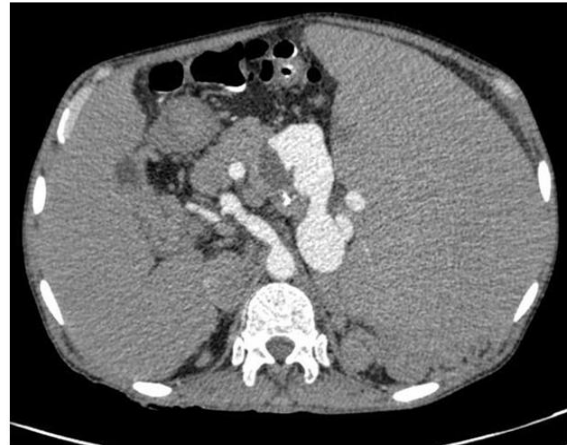

Fig 1. Case 1, CT scan of patient showing the SAA.

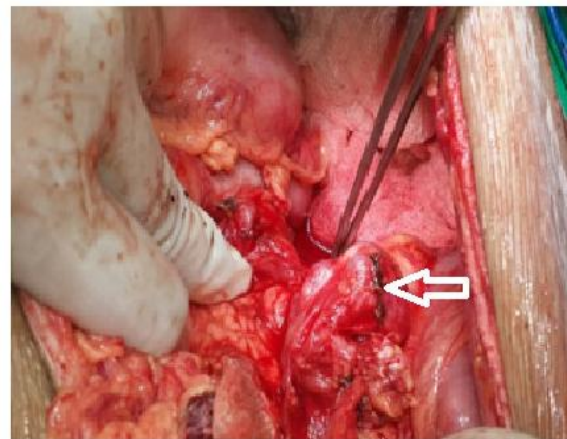


Fig 3. Case 2: Splenic artery aneurysm.

DISCUSSION

SAA is the most common visceral artery aneurysm. Though, exact etiology of the development of SAA is unknown, known risk factors include hypertension, PH, cirrhosis, pregnancy, collagen vascular diseases and autoimmune conditions like lupus, vasculitidis. [7-10] Upto 24% of patients of SAA have PH and the reported rate of SAA in patients of PH and cirrhosis range from 7 to 50% [11,12] and may be multiple. [13] The rate of growth of the aneurysm depends on the splenic artery diameter; greater the diameter of the splenic artery, greater will be the rate of growth of

SAA. [12] There exists a splenic hyperkinetic state in patients of PH, as demonstrated by Ohta M et. al, these patients have significantly higher splenic vein flow. Splenic artery diameter and porto-systemic collaterals. Increased flow and diameter of the splenic artery are thought to be leading to the development of SAAs. [6] Histopathology of these aneurysms reveals arterial fibro dysplasia. [7] An increasing frequency of development of SAA is seen in patients after liver transplantation and it is recommended that all patients considered for liver transplantation be screened for SAAs. [9,13]

SAA are usually asymptomatic and diagnosed incidentally on cross sectional imaging. In two large series by Reber PU et al and Pitkaranta et al, 17% and 20% lesions were symptomatic, [14,15] respectively, with vague pain in left upper quadrant and epigastric pain or discomfort. Rarely, patient may present with severe pain abdomen with shock, due to rupture of the aneurysms. The incidence of rupture of SAA in patients with PH is as high as 35% with a mortality rate of 57%. [12] One of our patients was asymptomatic while the other had pain in left hypochondrium. These lesions were diagnosed on CECT of abdomen, which in addition show the size, location and number of aneurysms with the presence of shuntable splenic or superior mesenteric veins in the patients of PH.

Treatment is indicated in all patients of SAAs of size >2cm due to high risk of complications including rupture. [8] In patients of PH the risk of complications like rupture is higher, owing to the hemodynamic changes in portal circulation, hence treatment is advocated in all cases, irrespective of the size. The treatment options include endovascular and surgical techniques. Endovascular techniques include embolization of the aneurysm using glue or coil and stent exclusion of the aneurysm using covered stents. Surgical options are ligation of splenic artery, aneurysmectomy and excision of the aneurysm with splenectomy. [16,17]

Treatment of patients of SAA with PH depends on the presence or absence of cirrhosis. In high risk patients with cirrhosis, endovascular treatment options give good alternative to high risk surgical treatments, with good results. [18,19] Majority of the literature describe treatment options in patients with cirrhosis and only limited information regarding management options in patients with EHPV thrombosis with SAA. [20] Non surgical options may be considered in patients with EHPV thrombosis with SAA without any bleeding esophageal varices, portal biliopathy or hypersplenism. The risk of re-bleeding after endovascular treatment in these patients on long term is not known. In patients with biliopathy, significant esophageal or gastric varices and hypersplenism, surgical treatment can offer relief from both the problems. Splenectomy with proximal spleno-renal shunt offers good treatment option for patients with EHPV thrombosis and excision of the aneurysm or proximal ligation of the splenic artery to treat SAA at the same time.

Our patients did not have shuntable veins. Both splenic and superior mesenteric veins were replaced by collaterals in the first case and the superior mesenteric vein was of small caliber of 6 mm in the second case. Splenectomy with esophagogastric de-vascularization remains an effective surgical tool in patients with non-cirrhotic PH with upper GI bleeding without shuntable vessels. [21,22] These patients were treated with de-vascularization procedure along with excision of the aneurysms.

CONCLUSION

Hyperdynamic circulation in the splanchnic system plays an important role in the pathogenesis of SAA. Proximal spleno-renal shunt can be offered at the same setting for the management of PH. In those patients who do not have shuntable vessels, de-vascularization can be offered as treatment option in patients with upper GI bleeding and hypersplenism along with splenectomy and excision of the SAA.

REFERENCES

1. Agrawal A, Whitehouse R, Johnson RW, Augustine T. Giant splenic artery aneurysm associated with arteriovenous malformation. *J Vasc Surg.* 2006; 44:1345-9.
2. Trastek VP, Pairolero PC, Joyce JW, Hollier LH, Bernatz PE. Splenic artery aneurysms. *Surgery* 1982; 91:694-699.
3. Stanley JC, Thomas NW, Fry WJ. Splanchnic artery aneurysms. *Arch Surg* 1970; 101:689-697.
4. Bedford PD, Lodge B. Aneurysm of the splenic artery. *Gut* 1960; 1:312-320.
5. Rokke O, Sondenaa K, Amundsen S, Bjerke-Larssen T, Jensen D. The diagnosis and management of splanchnic artery aneurysms. *Scand J Gastroenterol* 1996; 31:737-743.
6. Ohta M, Hashizume M, Ueno K, Tanoue K, Sugimachi K, Hasuo K. Hemodynamic study of splenic artery aneurysm in portal hypertension. *Hepatogastroenterology* 1994; 41: 181 - 184
7. Stanley JC, Fry WJ. Pathogenesis and clinical significance of splenic artery aneurysms. *Surgery* 1974;76:898-909.
8. Abbas MA, Stone WM, Fowl RJ, et al. Splenic artery aneurysms: two decades experience at Mayo Clinic. *Ann Vasc Surg* 2002; 16:442-449.
9. Lee PC, Rhee RY, Gordon RY, Fung JJ, Webster MW. Management of splenic artery aneurysms: the significance of portal and essential hypertension. *J Am Coll Surg* 1999; 189: 483-490.
10. Selo-Ojeme DO, Welch CC. Review: spontaneous rupture of splenic artery aneurysm in pregnancy. *Eur J Obstet Gynecol Reprod Biol* 2003; 109:124-127
11. Boijesen E, Efsing HO. Aneurysm of the splenic artery. *Acta Radiol Diagn (Stockh)* 1969; 8:29-41.
12. Sunagozaka H, Tsuji H, Mizukoshi E, Arai K, Kagaya T, Yamashita T, Sakai A, Nakamoto Y, Honda M, Kaneko S. The development and clinical features of splenic aneurysm associated with liver cirrhosis. *Liver International* 2006; 26: 291-297.
13. Ayalon A, Wiesner RH, Perkins JD, et al. Splenic artery aneurysm in liver transplant patients. *Transplantation* 1988; 45(2): 386-389
14. Reber PU, Baer HU, Patel AG, et al. Life-threatening upper gastrointestinal tract bleeding caused by ruptured extrahepatic pseudoaneurysm after pancreaticoduodenectomy. *Surgery* 1998; 124(1): 114-115
15. Pitkaranta P, Haapiainen R, Kivisaari L, Schroder T. Diagnostic evaluation and aggressive surgical approach in bleeding pseudoaneurysms in pancreatic pseudocysts. *Scand J Gastroenterol* 1991; 26(1): 58-64.
16. McDermott VG, Shlansky-Goldberg R, Cope C. Endovascular management of splenic artery aneurysms and pseudoaneurysms. *Cardiovasc Intervent Radiol* 1994; 17:179- 184.
17. de Perrot M, Bühler L, Deléaval J, Borisch B, Mentha G, Morel P. Management of true aneurysms of the splenic artery. *Am J Surg* 1998; 175:466-468.
18. Briard RJ, Lee J, Doyle T, Thompson P. Endovascular repair of a portal hypertension-related splenic artery aneurysm using a self-expanding stent-graft. *Cardiovasc Intervent Radiol* 2009; 32:1111-1113.
19. Roland J, Brody F, Venbrux A. Endovascular management of a splenic artery aneurysm. *Surg Laparosc Endosc Percutan Tech* 2007; 17:459-461.

20. Debnath J, George RA, Rao PP, Ghosh K. Splenic artery aneurysm-- a rare cause for extrahepatic portal venous obstruction: a case report. Int J Surg 2007;5:351-352.
21. Hassab MA. Gastro-esophageal decongestion and splenectomy GEDS (Hassab), in the management of bleeding varices. Review of literature. Int Surg. 1998;83(1):38-41.
22. Sujoy Pal. Current Role of Surgery in Portal Hypertension. Indian J Surg. 2012 Feb; 74(1): 55-66.

How to cite this article: Bhat PKR, Prabhu RY, Deshpande AA et al. Management of splenic artery aneurysm in extra-hepatic portal hypertension. Int J Health Sci Res. 2016; 6(4):561-565.

International Journal of Health Sciences & Research (IJHSR)

Publish your work in this journal

The International Journal of Health Sciences & Research is a multidisciplinary indexed open access double-blind peer-reviewed international journal that publishes original research articles from all areas of health sciences and allied branches. This monthly journal is characterised by rapid publication of reviews, original research and case reports across all the fields of health sciences. The details of journal are available on its official website (www.ijhsr.org).

Submit your manuscript by email: editor.ijhsr@gmail.com OR editor.ijhsr@yahoo.com