

Case Report

Bednar's Tumour of the Wrist: A Rare Diagnosis

Priyanka^{1*}, Jyotsna Sen^{2*}, Sonu Kalyan^{1**}, Minu Gill^{2**}, Poonam Tanwar^{1*}

¹Junior Resident, ²Professor,
*Department of Radiodiagnosis, PT BDS PGIMS, Rohtak, Haryana.
**Department of Pathology, PT BDS PGIMS, Rohtak, Haryana.

Corresponding Author: Priyanka

Received: 02/03/2016

Revised: 19/03/2016

Accepted: 22/03/2016

ABSTRACT

Pigmented dermatofibrosarcoma protuberans, also known as Bednar tumor, is a rare variant of dermatofibrosarcoma protuberans (DFSP). Dermatofibrosarcoma Protuberans (DFSP) is a rare type of cancer, a soft tissue sarcoma that develops in the deep layers of skin. We report an unusual case of histopathologically proved DFSP of the right wrist with clinical and imaging characteristics.

Keywords: DFSP, Bednar tumor, Wrist.

INTRODUCTION

Pigmented dermatofibrosarcoma protuberans, also known as Bednar tumor, is a rare variant of dermatofibrosarcoma protuberans (DFSP). DFSP is a rare type of cancer, a soft tissue sarcoma that develops in the deep layers of skin. DFSP is most commonly found on the torso, but can also be seen on the arms, legs, head and neck. ^[1] It has a tendency to recur in the same location after it is removed. However, it spreads to other parts of the body in about 5% of cases. DFSP tends to affect people between the age of 20 and 50, but it has been diagnosed in people of all ages. ^[2] It occurs predominantly in blacks. ^[1] Herein, we report case of Bednar tumor of wrist with clinical and imaging characteristics.

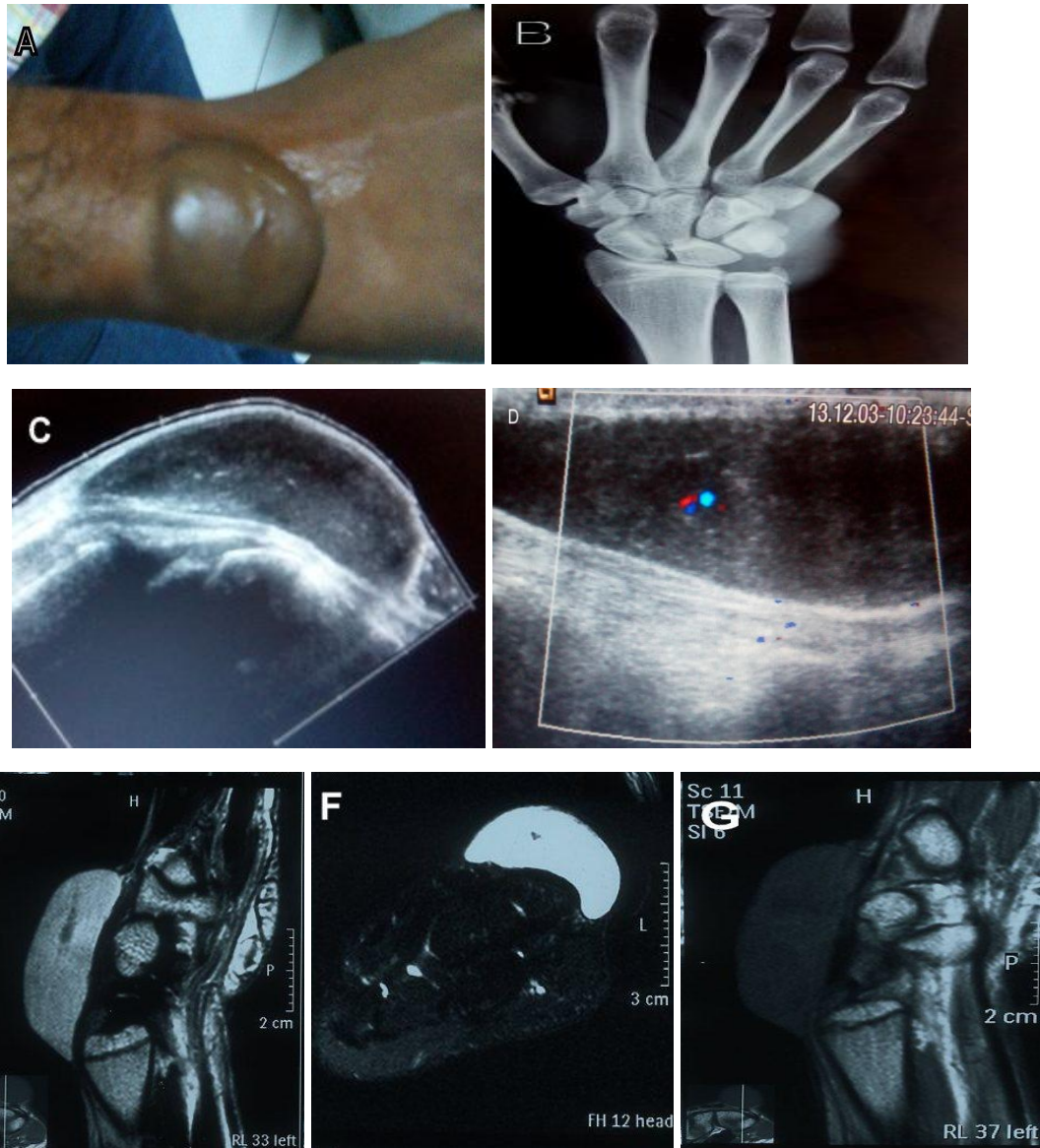
CASE REPORT

A 16 year old male patient presented to the orthopaedics OPD with a mass on the ulnar side of dorsal aspect of right wrist which was first noted 2 years back and started increasing in size since 2 months.

There was bluish discoloration of the overlying skin. Swelling was firm, slightly tender and non mobile on palpation. There was no neurovascular compromise and strength was normal.

X-ray of the wrist showed soft tissue density mass over ulnar aspect of right wrist without evidence of bone involvement or calcification. On USG, a well defined hypoechoic solid lesion of approx size 4 × 4 cm was seen adjacent to the tendons showing flow on color Doppler.

Subsequent MRI revealed an oval soft tissue mass of approx size 3.5 × 1.8 × 4.9 cm in the subcutaneous plane on dorsomedial aspect of right wrist. It was hypointense on T1W and hyperintense on T2W and STIR images. There were subtle hypointensities within the lesion on T2W images. On contrast administration, there was no significant enhancement. Underlying muscles, bones and neurovascular structures were normal. Complete surgical excision was done and was reported as Bednar tumor on histopathology.



BEDNAR'S TUMOUR OF DORSUM OF RIGHT WRIST

Fig. A- Bluish swelling over the dorsal wrist. **Fig. B -** X-ray Right wrist (AP view) with hand shows a soft tissue density mass over the ulnar aspect of the wrist. **Fig. C,D -** USG images well defined hypoechoic lesion showing minimal flow on color Doppler. **Fig. E,F -** T2W saggital and T2W FS axial images show well defined hyperintense lesion. **Fig. G -** T1W saggital image shows lesion is hypointense.

DISCUSSION

Dermatofibrosarcoma protuberans (DFSP) is a low to intermediate grade soft-tissue sarcoma originating from the dermal layer of the skin. Although historically it has been attributed to fibroblastic origin, DFSP is now thought to originate from mesenchymal stem cells according to the currently dominant cancer stem cell hypothesis. [2] It has potential for local recurrence after excision. Metastases are rare and usually occur late in the disease course and dissemination may occur via hematogenous route and rarely lymphatic. [3]

DFSP comprises roughly 0.01% of all malignant tumors and approximately 2 to 6 percent of all soft-tissue sarcomas. The incidence among blacks is almost double that among whites. [2] It most commonly affects patients between 20 and 50 years of age, although it has been described in both children and in the elderly.

DFSP usually has a long slow indolent course, with early tumors appearing as painless areas of cutaneous thickening. They may have pink, dark red or even bluish discoloration, particularly at the periphery. Over time, they develop into a larger nodular mass, and ultimately can

develop into a large fungating lesion. When they grow into the epidermal layer of the skin, they may eventually ulcerate. Unlike tumors of the subcutaneous tissue, DFSP is adherent or intimate with its overlying skin. Typically it is not adherent to underlying structures, with most tumors being superficial and less than 5 cm in size at time of diagnosis. [2]

The duration of tumor growth ranges from months to years and may, in some cases, span decades. DFSP often is mistaken for lipomas, deep-seated epidermal cysts, scars, hypertrophic scars, keloids, dermatofibromas, nodular fasciitis, and insect bites and a delayed diagnosis is not uncommon. The trunk is the most common location (47%), followed by lower extremity (20%), upper extremity (18%), and finally head and neck (14%). DFSP is a malignant tumor, but only metastasizes 1-4% of the time. Metastasis is a late clinical outcome and typically occurs only after several local recurrences.

Our patient, presenting with swelling on dorsal aspect of wrist, was found to have hypoechoic lesion on USG. Lesion was hypointense on T1W and hyperintense on T2W and STIR images and showed subtle hypointensities within the lesion on T2W images (due to melanin). On contrast administration, there was no significant enhancement. Diagnosis of Bednar's tumor was made on histopathology. Similarly Bednar's tumor presenting in deeper layers of skin at trunk have been reported by Kobayashi T et al. [4] However Bednar's tumor presenting as wrist swelling has not been reported in literature.

Although routine imaging is not necessary, magnetic resonance imaging (MRI) may be helpful to evaluate the gross local extent of the tumor and may be important in preoperative planning for

larger tumors. As with many other soft tissue tumors, T1-weighted images demonstrate low signal characteristics while T2-weighted images exhibit higher signal. While MRI can adequately delineate the bulk of the tumor, it does not define microscopic tumor extension. Furthermore, it does not clearly define recurrent lesions or lateral infiltration which is typical of this entity. In patients with prolonged or recurrent DFSP or when sarcomatous changes are evident, a CT of the chest should be obtained to evaluate for pulmonary metastases. A CT scan of the local area may be useful if bony involvement is suspected. Diagnosis is made using either a core needle or an open incisional biopsy. [2]

Conflict of interest: All authors state that there are no conflicts of interests.

REFERENCES

1. Dupree WB, Langlos JM, Weiss SW. Pigmented dermatofibrosarcoma protuberans (Bednar tumor). A pathologic, ultrastructural, and immunohistochemical study. *Am J Surg Pathol.* 1985 Sep; 9(9):630-9.
2. O'Halloran K, Courtney J, G. Gorlick R, S. Geller D. The Liddy Shriver Sarcoma Initiative's Accomplishments in 2012 [Internet]. Liddy Shriver Sarcoma Initiative. 2015[cited 30 November 2015]. Available from: <http://sarcomahelp.org/newsletter/articles/editorial-2012.html>
3. Kaul R, Kaur N, Dogra SS, Chander B. Variant of dermatofibrosarcoma protuberans: Bednar tumor. *Indian J Dermatol.* 2015 Jan-Feb; 60(1):107.
4. Kobayashi T, Hasegawa Y, Konohana A, Nakamura N. A case of Bednar tumor. Immunohistochemical positivity for CD 34. *Dermatology* 1997; 195(1):57-9.

How to cite this article: Priyanka, Sen J, Sonu Kalyan S et al. Bednar's tumour of the wrist: A rare diagnosis. *Int J Health Sci Res.* 2016; 6(4):558-560.
