

Case Report

Fast Growing Giant Intramural Leiomyoma - A Case Report

Sangita Ramteke, Pravina Joshi, Ashish Zararia, Deepika Dharmale

Government Medical College and Hospital, Nagpur, Maharashtra, India.

Corresponding Author: Pravina Joshi

Received: 10/01/2016

Revised: 08/03/2016

Accepted: 09/03/2016

ABSTRACT

Though uterine fibroids are the most common benign pelvic tumours found in women of reproductive age groups, giant leiomyomas are rarely encountered and many a times misdiagnosed as malignancy. We report a case of giant leiomyoma in a 40 year old parous woman, which weighed 6.5kg and filled the patient's abdomen. Physical examination and trans-abdominal ultrasound were pointing towards ovarian mass. Whereas Abdominal Computed Tomography scanning suggested a large myometrial fibroid of uterus. Abdominal hysterectomy and unilateral salpingo-oophorectomy was performed. Uterine mass 26x23x18 cm was removed which on cut section showed partially autolysed intramural fibroid. The post-operative period was uneventful and patient was discharged from the hospital on 10th post-operative day.

Keywords: Giant intramural leiomyoma, Ultra-sonography, CT scan, Hysterectomy, Anaemia.

INTRODUCTION

Leiomyoma is the most frequent pelvic tumor in women, with the highest prevalence occurring during the fifth decade. (1) Giant uterine leiomyoma is a very rare neoplasm and a great therapeutic and surgical challenge. Such leiomyomas are solitary and although have a clinical presentation similar to that of leiomyosarcoma, have a benign prognosis. The most common symptoms are pelvic heaviness, pain including dysmenorrhea, abnormal uterine bleeding, urinary frequency and urgency. The diagnosis is clinically confirmed by physical examination. Upon palpation, an enlarged, firm, irregular uterus may be felt. Ultrasound is diagnostic in most of the cases. CT scan can distinguish between malignant and benign varieties. Symptomatic uterine leiomyomas are the primary indication for approximately 30% of all hysterectomies. (2)

CASE SUMMARY

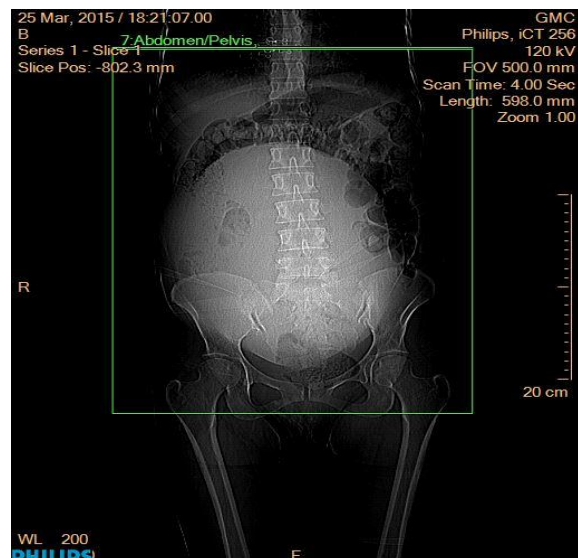


Figure 1: Tomogram showing extent of the tumor in the abdominal cavity

A 40 year female, housewife, presented in our gynaecology department with history of abdominal distention since two months, decreased appetite and weakness, fatigue and weight loss since 1.5

months, complaint of excessive bleeding per vaginum since 15 days, associated with passage of clots. Patient was married since 20 years with 2 normal vaginal deliveries. She had regular menstrual cycles of 4-5/30 days with heavy bleeding. She did not have any associated bowel or bladder complaints. On examination she was of thin built, weighing 39kgs having pallor grade 3. On per abdominal examination, an ovoid mass of approx. 25x15x12 cm felt, occupying epigastric, umbilical, hypogastric and both iliac quadrants, non-tender, mobile side to side but not vertically, having variegated consistency. On vaginal examination uterus could not be felt separately from the mass. Bilateral fornices were free and non-tender. Her transabdominal ultrasound was

suggestive of bilateral adnexal mass; both ovaries could not be visualized separately from the mass. Hence her CA-125 was done which came to be normal. A provisional diagnosis of uterine fibroid was made but possibility of ovarian tumour could not be ruled out due to clinical course of rapid growth, weight loss and consistency of the mass. For confirmation of diagnosis, CT scan was done.

CT scan was confirmatory of fibroid uterus. Large, well defined hypodense non enhancing lesion of approximately 19.5x15.5x21.1 cm in transverse, AP and craniocaudal axis respectively involving myometrium of the uterus was seen. (Figure 1, 2 and 3)

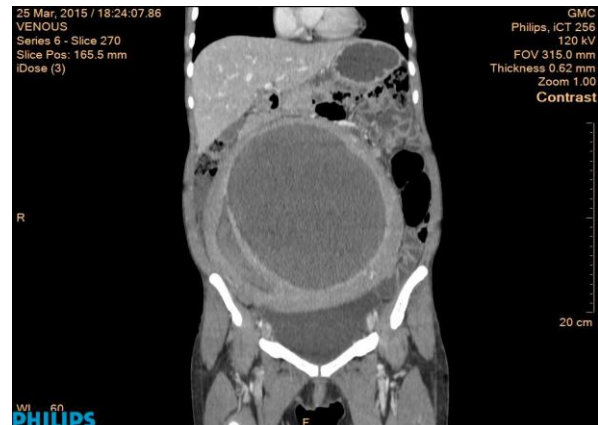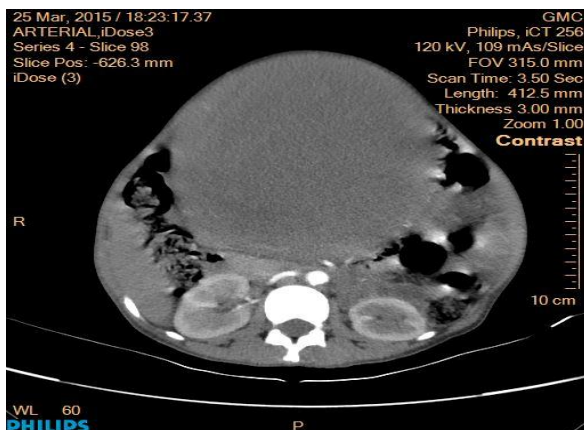


Figure 2&3: CECT axial and coronal view shows well defined hypodense non enhancing lesion noted involving left lateral wall of uterus with possible communication with endometrial cavity.

Preoperatively Patient was optimized by giving 3 units of whole blood. On laparotomy, large regular, solid, mass within uterus was identified. Right ovarian cyst was found. Left ovary was normal. Patient underwent abdominal hysterectomy with right salpingo-oophorectomy. Grossly the specimen weighed 6.5 kg. Size of the mass along with uterus was 26x23x18 cm. Right ovary with cyst measured 8x7x3 cm (figure 4).

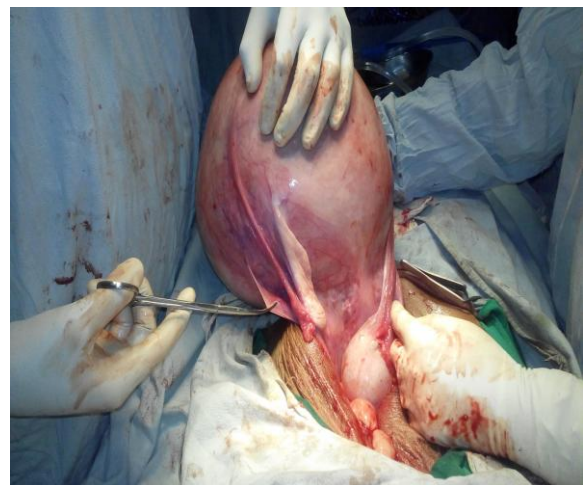

Figure 4: Intraoperative image showing enlarged uterus with tumor (Posterior view) with right ovary with cyst and normal left sided ovary

Histopathological findings- Gross-uterine mass 26x23x18 cm with cervix 4cm. Uterine cut section showed intramural fibroid, partially autolysed. (figure 5). The section of uterine mass showed histological features of leiomyoma.

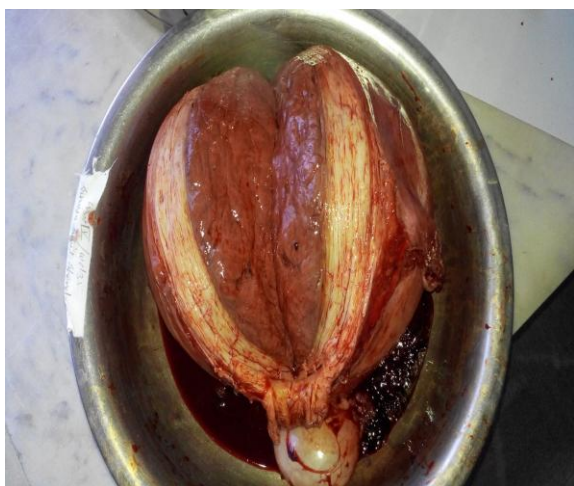


Figure 5: Cut section of the uterus showing intramural fibroid filling the uterine cavity.

DISCUSSION

Leiomyomas are slow to grow and it is often said to take 3 years for one to reach the size of an orange. This is only a generalization; the rate of growth varies from patient-to-patient and from time-to-time in the same patient. ⁽³⁾ Atypical presentation of giant fast growing leiomyoma may be misdiagnosed as leiomyosarcoma or ovarian malignancies. There are numerous diagnostic modalities for leiomyoma, leiomyosarcoma, or ovarian malignancy including ultrasonography, MRI, computed tomography, hysteroscopy, and saline infusion sonography. But none of these diagnostic imaging modalities can differentiate the benign and malignant growths exactly without confirmation by the pathological examination. Like this, as a blood test, the cancer antigen-125 is a useful marker in diagnosis of malignant ovarian mass but it can be seen in high levels also in uterine fibroids as well as in other benign gynecologic diseases. Ultrasonography is the preferred imaging tool for diagnosis of the initial evaluation after bimanual examination because of its wide availability, being inexpensive, and least invasive character. ⁽⁴⁾ Symptomatic uterine leiomyoma are the primary indication for approximately 30% of all hysterectomies. ⁽²⁾ Hysterectomy is the definitive procedure and carries an outstandingly good outcome and guarantees complete cessation of periods with no risk of fibroid recurrence. ⁽⁵⁾

CONCLUSION

Giant and fast growing leiomyomas may create a diagnostic dilemma due to their unusual clinical course and thus increase the morbidity in the patients. Ultrasonography, though non-invasive and cost-effective modality, may not be diagnostic in such cases. CT scan should be performed in cases of diagnostic dilemma to confirm the diagnosis and decide further course of management. In a developing country like India, patients from remote areas do not have early access to health-care facilities, and thus present with complications related to the disease increasing morbidity and mortality. (Such as anaemia in this case)

Whenever patient presents with fast growing pelvic tumour, possibility of giant uterine leiomyoma should be kept in mind. Hysterectomy is the treatment of choice.

REFERENCES

1. Săvulescu F, Iordache I, Albița O, Hristea R, Dumitru C, Iordache A, Bălașa G, Iordache C, Leau D, Rogin T, Vîrjoghe V. Chirurgia (Bucur). Giant uterine leiomyoma. 2011 Sep-Oct; 106(5): 665-8. Available from <http://www.ncbi.nlm.nih.gov/pubmed/22165069>.
2. Florencia Elena Castaneda Valladares, M.D, Miguel Polamares M.D. Francisco Urias Soto et al Large uterine myoma of giant cells (8.1kg): case report [internet] 2013 available from <http://www.epostersonline.com/rcog/2013/?q=node/1175>.
3. Malhotra N, Kumar P, Malhotra J, Bora N, Mittal P. Jeffcoate's principles of Gynaecology 8e. New Delhi: Jaypee brothers medical publishers (P) ltd.; 2014. 453-471.
4. Erbil Karaman, NumanCim, GulayBulut et al. A case report of Giant Uterine Lipoleiomyoma simulating malignancy. Case Reports in Obstetrics and

Gynaecology, volume 2015 (2015),
Article ID 926961.

5. Amir T Khan, Manjeet Shehmar,
Janesh K Gupta. Uterine fibroids:

Current perspectives. International
journal of womens' health volume
2014; 6:95-114.

How to cite this article: Ramteke S, Joshi P, Zararia A et al. Fast growing giant intramural leiomyoma - a case report. Int J Health Sci Res. 2016; 6(4):542-545.

International Journal of Health Sciences & Research (IJHSR)

Publish your work in this journal

The International Journal of Health Sciences & Research is a multidisciplinary indexed open access double-blind peer-reviewed international journal that publishes original research articles from all areas of health sciences and allied branches. This monthly journal is characterised by rapid publication of reviews, original research and case reports across all the fields of health sciences. The details of journal are available on its official website (www.ijhsr.org).

Submit your manuscript by email: editor.ijhsr@gmail.com OR editor.ijhsr@yahoo.com