

Original Research Article

A Study of Communications of Ulnar, Median and Musculocutaneous Nerves

N. B. S. Parimala

Associate Professor, Dept of Anatomy, N.R.I Medical College, Chinakakani, Guntur District, (AP), India.

Received: 26/02/2016

Revised: 14/03/2016

Accepted: 15/03/2016

ABSTRACT

The median nerve has two roots from the lateral (C5, 6, 7) and medial (C8, T1) cords, which embrace the third part of the axillary artery, and unite anterior or lateral to it. If the lateral root is small, the musculocutaneous nerve (C5, 6, 7) connects with the median nerve in the arm. Communications between the median and musculocutaneous nerves are not uncommon. The ulnar nerve has its roots C8 and T1 and it is a branch of medial cord. To have fibres of C7 root in it, the ulnar nerve must receive the contribution from lateral cord. 90 upper limbs obtained from 45 cadavers allotted for routine dissection to undergraduate medical students were studied over a period of 5 years (2010-2015). Communication between musculocutaneous nerve and median nerve was observed in 19 out of 90 upper limbs and complete fusion of musculocutaneous nerve and median nerve was observed in 8 out of 90 upper limbs. The MCN or MN injuries proximal or distal to the communicating branches could determine beneficial or deleterious modifications in the function and movement of the upper extremity.

Key words: Median nerve, Musculocutaneous nerve, ulnar nerve, Communications.

INTRODUCTION

The median nerve has two roots from the lateral (C5, 6, 7) and medial (C8, T1) cords, which embrace the third part of the axillary artery, and unite anterior or lateral to it. If the lateral root is small, the musculocutaneous nerve (C5, 6, 7) connects with the median nerve in the arm. ^[1]

The ulnar nerve has its roots C8 and T1 and it is a branch of medial cord. To have fibres of C7 root in it, the ulnar nerve must receive the contribution from lateral cord. Though a mention of this contribution is made by almost all standard text books of anatomy ^[1,2] but at the same time its incidence was not mentioned. According to Hollinshead ^[2] the contribution from lateral cord to ulnar nerve may be in the form of a small branch which is sometimes known as lateral root of ulnar nerve.

Communications between median nerve and musculocutaneous nerve are not infrequent and awareness of such type of variations is essential clinically to avoid misinterpretation of the scenario in case of nerve injuries.

The MCN injury proximal to the MCN-MN communication can lead to an unexpected weakness of the forearm flexor muscles and thenar muscles with clinical signs like seen in a MN injury at the level of the arm. Furthermore, the MN injury proximal to the MN-MCN communication can lead to a clinical presentation characterized by functional preservation of forearm and hand muscles innervated by MN. ^[3]

MATERIALS AND METHODS

90 upper limbs obtained from 45 cadavers allotted for routine dissection

every year to Under Graduate students were studied over a period of 5 years consecutively from 2010 to 2015 in Dr. PSIMS and RF and N.R.I Medical Colleges. During axilla dissection exposure of Brachial plexus was done. This was followed by the study of lateral cord, its 2 terminal branches the musculocutaneous nerve and lateral root of median nerve. Variations were observed in the mode of termination of lateral cord into 3 branches or it directly continued without any division in considerable number of specimens in this study. Variations in the formation of ulnar nerve were also observed. Formation of ulnar nerve was by two roots where a small lateral root arising from lateral cord joins the medial root of ulnar nerve.

OBSERVATIONS/RESULTS

In the present study lateral root of ulnar nerve was observed in 10 out of 90 upper limbs (11.11%).

Table 1: Formation of ulnar nerve by 2 roots - lateral root & medial root

No of specimens	laterality
2	unilateral
4	bilateral

Broadly 2 different types of variations were observed in Median nerve and musculocutaneous nerve. One was communication between musculocutaneous nerve and median nerve which in another way can be described as formation of median nerve by 2 lateral roots and 1 medial root. This type of variation was observed in 19 out of 90 upper limbs.

Table 2 Formation of median nerve by 3 roots- 2 lateral roots and 1 medial root (or) communication between Musculocutaneous nerve and median nerve

No of specimens	laterality
2	unilateral
8	bilateral

Table 3 Fusion of Musculocutaneous nerve and median nerve (or) absence of Musculocutaneous nerve

Fusion of Musculocutaneous nerve and median nerve	No of specimens	laterality
partial	1	unilateral
Complete fusion	3	bilateral
	2	unilateral

Complete fusion of musculocutaneous nerve and median nerve which can also

be described as absence of musculocutaneous nerve was observed in 8 out of 90 upper limbs.

DISCUSSION

It was Martin [4] who first described a communication from the median nerve to the ulnar nerve and later Gruber [5] reported the similar communications. So Sonek et al [6] called these as “**Martin Gruber communication.**” However these were seen in the forearm and not from lateral root of median nerve to ulnar nerve in arm.

According to Doyle & Botte, [7] communicating ramus bringing fibres from C7 may arise not only from lateral root of median nerve but even proximal to it i.e. lateral cord, the anterior division of middle trunk or even middle trunk itself. Whatever may be the origin, this communicating ramus is termed as the lateral root of ulnar nerve. It usually joins the ulnar nerve at or distal to the inferior border of the subscapularis muscle & may provide innervations to flexor carpi ulnaris muscle.

The communicating ramus from the lateral root of the median nerve to the ulnar nerve or we can say lateral root of ulnar nerve has been reported earlier by Fazan et al [8] in 30% & Fuss [9] in 56% of their dissections. Fuss [9] further divided this lateral root of ulnar nerve into two Types viz type 1 & 2 depending upon whether it is accompanied by fibres of median nerve (type 1) or not (type 2). He also classified the lateral root into type a & b depending upon whether some fibres of medial root of median nerve pass behind the lateral root of ulnar nerve (type a) or all fibres of medial root of median nerve pass in front of lateral root of ulnar nerve (type b). He further emphasized that since the lateral root of ulnar nerve is seen in 56% of dissections, it should be considered as a normal entity & not a variation.

when compared to Fuss [9] classification the lateral root of ulnar nerve seen in the present study belong to Type 1, where the lateral root of ulnar nerve arises common with fibres of median nerve as a

communicating ramus from lateral root of median nerve and Type b nerve fibres of lateral root of ulnar nerve passed deep to the medial root of median nerve. The incidence of lateral root of ulnar nerve is in the present study is 11.11% (10 out of 90 upper limbs).

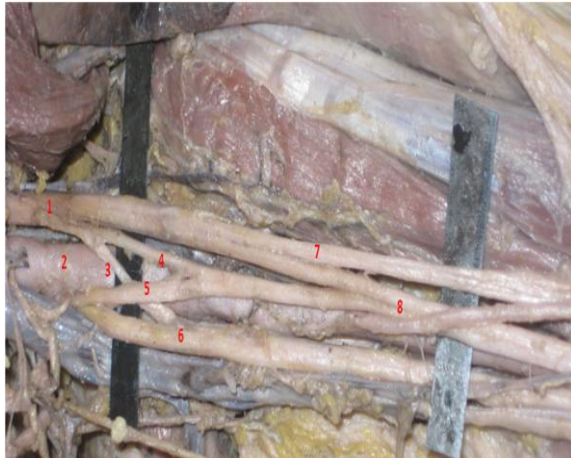

Fig: 1 1-lateral cord, 2-axillary artery, 3-lateral root of ulnar nerve (Fuzz Type I group b), 4-proximal root of median nerve, 5-medial root of median nerve, 7-musculocutaneous nerve, 8-communication of MCN with MN (Kaur & Singla Type 2 Group B)

There is lot of discrepancy in the description of variations of median nerve formation and its communication with musculocutaneous nerve among different authors. In standard text books it is simply described that if the lateral root of median nerve is small, the musculocutaneous nerve (C5, 6, 7) connects with the median nerve in the arm but the incidence was not stated. [1] The observations in the present study affirm the above said fact and the incidence of such communication with musculocutaneous nerve associated with a small lateral root was found to be 21.1% (19/90).

Regarding the variations of median nerve some authors describe that median nerve formation is duplicated because of presence of upper and lower lateral roots joining the medial root in front of axillary and brachial arteries, another group [10,11] describe that median nerve is formed by 3 roots of which 2 roots take origin from lateral cord [11] and many authors describe the same variation in a different way considering the upper lateral root as lateral root of median nerve and lower lateral root

as communication of median nerve with musculo cutaneous nerve. [11-18]

Eglseder and Goldman [11] also found that the median nerve was formed of two lateral roots in 14% of their specimens.

Uzun et al [12] found that the median nerve was formed by three branches coming from the lateral cord of the brachial plexus and one branch coming from the medial cord of the brachial plexus.

Kerr [13] reported a communicating branch between the median and musculocutaneous nerves.

Kosugi et al [14] reported supernumerary head of biceps brachii muscle and an interconnecting branch between the median and the musculocutaneous nerves.

Kaus and Wotowicz [15] also found a communicating branch between the median and the musculocutaneous nerves.

Venierotos and Anagnostopoulou [16] reported three types of communications between the median and musculocutaneous nerves.

In type one, the communication was observed proximal to the site of entry of the musculocutaneous nerve into the coracobrachialis muscle, While in type two the communication was present distal to the site of entry.

In type three the nerve and the communicating branch did not pierce the muscle.

In the present study in all cases except one the communication was proximal to the muscle entry and type 3 was not found. Complete fusion between the median and the musculocutaneous nerves and absence of MCN observed in the present study were not mentioned by the above author.

Iwamoto et al, [17] Eglseder and Goldman [10] and Uzun [11] et al also found communicating branches between the median and the musculocutaneous nerves.

Le Minor (1990) described five types of variations: [18]

Type 1: There is no communication between the MN and MCN.

Type 2: The fibres of medial root of MN pass through the MCN and join the MN in the middle of the arm.

Type 3: The lateral root fibres of MN pass through the MCN and after some distance, leave it to form the root of the MN.

Type 4: The MCN fibres join the lateral root of the MN and after some distance the MCN arise from the MN.

Type 5: The MCN is absent and the entire fibres of MCN pass through lateral root and fibres to the muscles supplied by MCN branch out directly from MN.

All except Type 3 of Le Minor variations were found in the present study.

Table4: Comparison of incidence of communication between median and musculocutaneous nerves

S. No.	Name of the study	Incidence of communication between median nerve and musculo cutaneous nerve in %
1	Kerr ^[13]	0.57% (1/175)
2	Sunderland and Marshall ^[19]	24%
3	Iwamoto et al ^[17]	from 0% to 30%
4	Kaus and Wotowicz ^[15]	57% (43/75)
5	Eglseder and Goldman ^[11]	36%
6	Venierotos and Anagnostopoulou ^[16]	28% (22/79)
7	Present study	21.1%

Another study involving dissection of ten cadavers, mentioned failure of separation of musculocutaneous nerve from the median nerve and the latter therefore gave off the branches that should arise from musculocutaneous nerve, namely branches to coracobrachialis, biceps brachii and major part of brachialis.^[20]

Complete absence of musculocutaneous nerve was reported by many authors. In a study conducted in 100 cadavers incidence was in 15 cases and in 3 cases associated with additional head of biceps brachii was reported.^[21]

Beheiry dissected 60 arms and noted absence of the nerve in only one of them (1.7%).^[22] Prasada Rao and Chaudhary^[23] did not find this nerve in 8% of the 24 arms they dissected. Sometimes the absence of this nerve is only apparent. Nakatani et al. published a report on three cases in which the lateral fasciculus, median nerve and musculocutaneous nerve were wrapped in a single sheath of conjunctive tissue. After removal of this sheath, the musculocutaneous and median nerves were separated out.^[24]

Splitting of median nerve in the arm was reported by Avinash et al.^[26] where Musculocutaneous nerve arose from the lateral aspect of median nerve and after supplying biceps brachii and brachialis

muscles continued as lateral cutaneous nerve of the forearm. In the present study similar type of splitting was seen in the middle one third of arm where the musculocutaneous nerve supplies biceps and brachialis muscles and continues as lateral ante brachial cutaneous nerve.

Table5: Comparison of incidence of absence of musculocutaneous nerve

S. no	Author	Incidence of absence of musculocutaneous nerve
1.	L. Arora , R. Dhingra ^[21]	15 /100
2.	Beheiry ^[22]	1/60
3.	Prasada Rao and Chaudhary ^[23]	2/24
4.	Budhiraja et al ^[25]	13/116
5.	Present study	8/90

Many workers have classified these communications in different ways; Recently Kaur & Singla^[27] have provided the most elaborated classification as under-

Type I: No communication i.e.; normal.

Type II: Some fibres of lateral root of median nerve pass through musculocutaneous nerve and join the median nerve at different levels in the form of communicating ramus.

Group A: A communicating ramus leaves musculocutaneous nerve immediately after the later is formed so that it gives appearance of trifurcation of lateral cord into musculocutaneous nerve and two lateral roots.

Group B: The communicating ramus leaves musculocutaneous nerve before it pierces coracobrachialis (All flexor muscles supplied by musculocutaneous nerve)

Group C: The communicating ramus leaves musculocutaneous nerve after it has pierced coracobrachialis. (All flexor muscles supplied by musculocutaneous nerve before the origin of communicating ramus)

Type III: All fibres of lateral root of median nerve pass with musculocutaneous nerve. The median nerve is just continuation of medial root only. However the musculocutaneous nerve after supplying flexors of forearm gives lateral root of median nerve to join the same.

In other words the lateral root arises distal to origin of muscular branches from musculocutaneous nerve.

Type IV: Whole of lateral cord continues as lateral root of median nerve ie. Musculocutaneous nerve joins lateral root of median nerve and after some distance musculocutaneous nerve arises from the median nerve.

Group A: Musculocutaneous nerve arises from median nerve proximal to muscular branches for flexors of arm which are thus supplied by musculocutaneous nerve.

Group B- Musculocutaneous nerve arises from median nerve after the former had supplied muscles of forearm. Then the musculocutaneous nerve continues only as lateral cutaneous nerve of forearm.

Type V: Complete fusion of musculocutaneous and median nerve at different levels.

Group A: Musculocutaneous nerve is altogether absent with all its fibres passing through lateral Root of median nerve. All branches of musculocutaneous nerve come from median nerve.

Group B: Musculocutaneous nerve supplies coracobrachialis and then completely fuses with Median nerve. Rest of its branches comes from median nerve.

Group C: Musculocutaneous nerve supplies all flexors of arm and then fuses with median nerve. The lateral cutaneous nerve of forearm comes from median nerve.

Type VI: The communicating ramus arises in lower one-third of arm after musculocutaneous nerve has supplied all flexors of arm. It crosses the elbow joint and reaches forearm where it joins median nerve.

Group A: The communicating ramus joins median nerve without piercing pronator teres.

Group B: The communicating ramus joins median nerve after piercing pronator teres.

Table 6: Incidence of Kaur & Singla [27] Types of communications in the present study

Type of communication	No of specimens	Percentage
Type 1 (normal)	63	70%
Type 2	19	20%
Group A	6	6.6%
Group B	12	13.3%
Group C	1	1.1%
Type 3	Not seen	-
Type 4 Group A	1	1.1%
Type 5	7	7.7 %
Group A	6	6.6%
Group B	1	1.1%
Type 6	Not seen	-

Type3 and Type 6 of Kaur & Singla [27] were not seen in the present study.

Figures 2 to 7 - showing various types of Communications between median & Musculocutaneous Nerves.

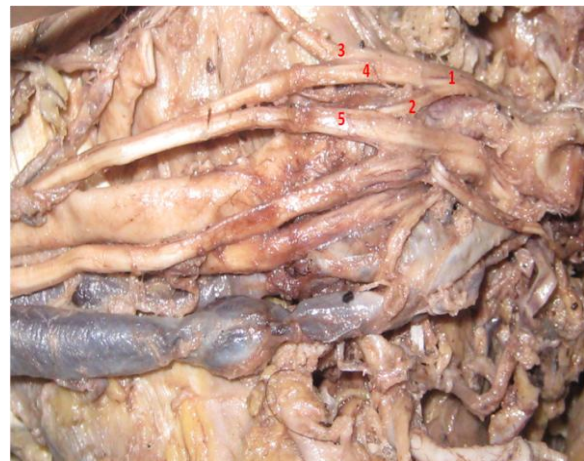

Fig 2: Type 2 Group A: 1-Lateral cord, 2-lateral root of median nerve, 3-MCN, 4-communicating ramus, 5-Median nerve.

According to one author [28] all the limbs with communicating ramus from lateral root of Median nerve to ulnar nerve necessarily has a fusion between musculocutaneous & median nerve but the reverse ie., 'the limbs which have fusion (or communicating ramus) between Musculocutaneous & median nerve also

have a communicating ramus from lateral root of Median nerve to ulnar nerve' is not true. Similar type of observation was also found in the present study.

The upper limb buds lie opposite the lower five cervical and upper two thoracic segments. The ventral primary rami of the spinal nerves C4 - T2 penetrate into the mesenchyme of limb bud. The early contact between nerve and muscle cells is a prerequisite for their complete functional differentiation. [29] several signaling molecules and transcription factors like brain-derived neurotropic growth factor, neutrin-1, neutrin-2, c-kit ligand, etc are involved in the initiation and progress of this process and misexpression of these factors particularly at the time of differentiation of brachial plexus can result in abnormalities in the formation and distribution of nerve fibres. [30,31]

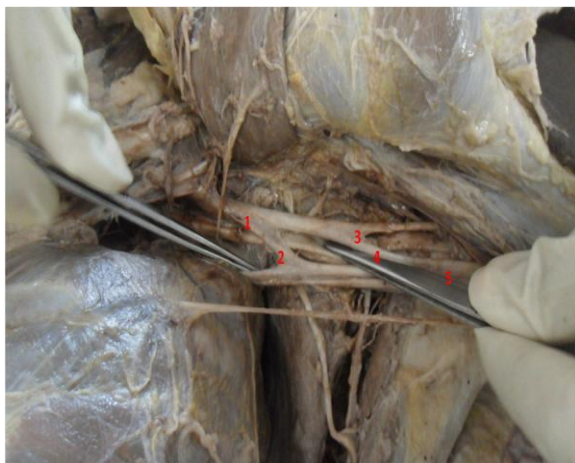


Fig 3: Type 2 Group B: 1-Lateral cord, 2-lateral root of median nerve, 3-MCN, 4-communicating ramus, 5-Median nerve.



Fig 4: Type 2 Group C: 1-Lateral cord, 2-lateral root of median nerve, 3-MCN, 4-communicating ramus, 5-Median nerve.

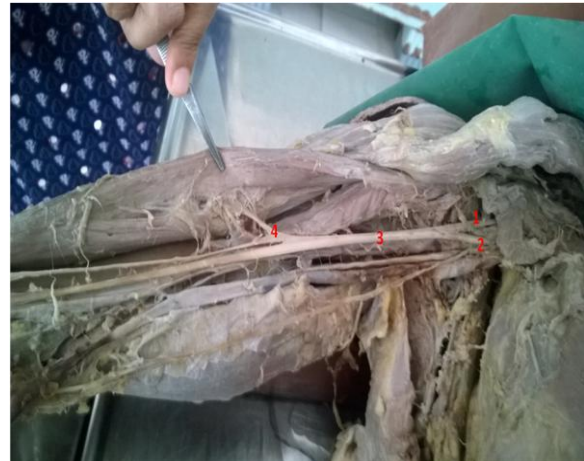

Fig5: Type 4-group A: 1&2 -lateral root & medial root of median nerve, 3-median nerve with fibres of MCN, 4-MCN separated from median nerve, gives muscular branches to biceps, brachialis and continues as lateral cutaneous nerve of forearm.

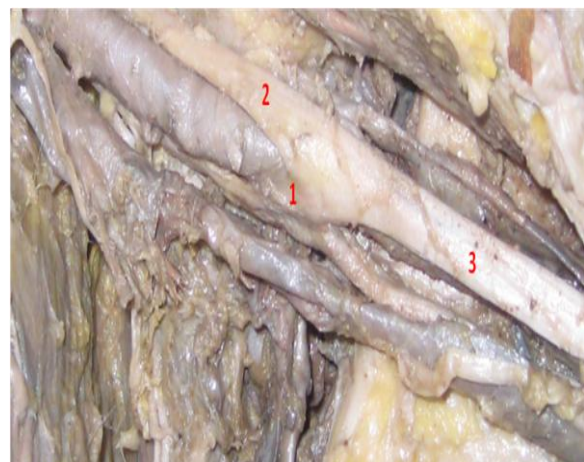


Fig6: Type 5-group A: 1-medial root, 2-lateral root of median nerve, 3-Median nerve with completely fused MCN

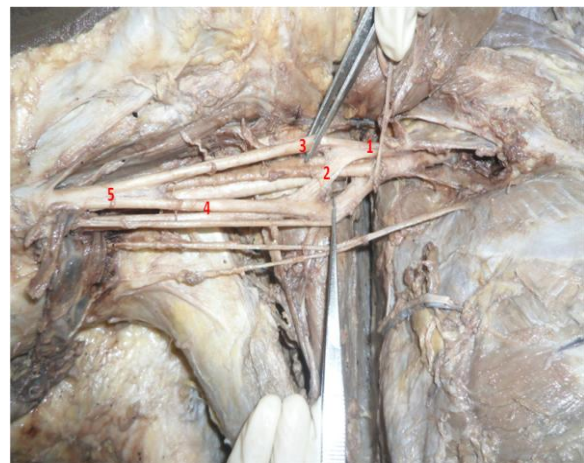

Fig7: Type 5-group B: 1-Lateral cord, 2-lateral root of median nerve, 3-MCN with branches to coracobrachialis, 4- Median nerve, 5-complete fusion of MCN and MN.

In the peripheral nerve surgery, especially in nerve transfers techniques, a good knowledge of the MCN-MN communications is required. The MCN has

been successfully used as a receiver nerve to the recovery of elbow flexion. [32,33]

The MCN-MN communication should be considered for clinical examination of nerve injuries at the axilla and the arm, as well as in the surgical procedures to this region like the neuromuscular flaps, peripheral nerve repair or even for the nerve blocks at the upper extremities in anaesthetic practice. The MCN or MN injuries proximal or distal to the communicating branches could determine beneficial or deleterious modifications in the function and movement of the upper extremity. [34-36]

CONCLUSION

Communications between Median nerve and Musculocutaneous nerve are not infrequent. Many authors have classified these communications and the in present study the observations were compared with 3 types of classifications given in literature. Formation of median nerve as direct continuation of medial root Type3 [18,27] and communications in the distal one third of arm Type 6 [27] were not seen in the present study. The knowledge is essential for clinicians, surgeons and orthopedicians in understanding and in interpretation of nerve injuries in arm.

Abbreviation: MCN - Musculocutaneous nerve.

REFERENCES

1. Standring S, ed. Gray's Anatomy. The Anatomical Basis of Clinical Practice. 40th Ed., Edinburgh, Churchill Livingstone. 2009; 780, 821-822.
2. Hollinshead WH. Anatomy for surgeons .In: General Survey of the Upper Limb. 2nd ed. New York, Harper and Row, 1985; Vol (3): 236-40.
3. H. El Falougy, P. Selmeciova, E. Kubikova, J. Stenova, Z. Haviarova The variable communicating branches between musculocutaneous and median nerves: a morphological study with clinical implications Bratisl Lek Listy, 114 (5) (2013), pp. 290-294.
4. Martin R. Tal om Nervus alimanna Egenskaper I Maniskans Kropp. Las Salvius, 1763.
5. Gruber W. Ueber die Verbindung des Nervus medianus mit dem Nervus ulnaris am Unterame des Menschen um der Säugethiere. Archives of Physiology 1870; 37 (2): 501-522.
6. Sonek WA, Francx MM, Engels MM. Innervation anomalies in upper and lower extremities: potential clinical implications, how to identify with electrophysiologic techniques. Electromyogr Clin Neurophysiol 1991; 31: 67-68
7. Doyle JR and Botte MJ. Brachial plexus. In: Surgical Anatomy of the Hand and Upper Extremity. Lippincott, Williams & Wilkins, 2003; 204.
8. Fazan VPS, Amadeu ADS, Caleffi AL, Filho OAR. Brachial plexus variations in its formation and main branches. Acta Cir Bras 2003; 18 (5): 1-8.
9. Fuss FK. The lateral root of the ulnar nerve. Acta Anat (Basel). 1989; 134(3): 199-205.
10. Sargon M, Uslu S, Celik H, et al. A variation of the median nerve at the level of the brachial plexus. Bull de l Assoc des Anatom 1995; 79:25-6.
11. Eglseeder E, Goldman M. Anatomical variations of the musculocutaneous nerve In the arm. Am J Orthop 1997;26:777-80
12. Uzun A, Leonard L, Seelig J. A variation in the formation of the median nerve: communicating branch between the musculocutaneous and the median nerve in man. Folia Morphol 2001;60:99-101
13. Kerr A. The brachial plexus of nerves in man, the variation in its formation and branches. Am J Anat 1918; 23:285-95.
14. Kosugi K, Shibata S, Yamashita H. Supernumerary head of biceps brachii and branching pattern of the musculocutaneous nerve in Japanese. Surg Radiol Anat 1992; 14:175-85.
15. Kaus M, Wotowicz Z. Communicating branch between the musculocutaneous and median nerves in human. Folia Morphol 1995; 54:273-7.
16. Venierotos D, Anagnostopoulou S. Classification of communications between the musculocutaneous and median nerves. Clin Anat 1998; 11:327-31.
17. Iwamoto S, Kimura K, Takahashi Y, et al. Some aspects of communicating Branch between the musculocutaneous and median nerves in man. Okajimas Folia Anat Jpn 1990; 67:47-52.
18. Le Minor JM. A rare variant of the median and musculocutaneous nerve in man. Arch Anat Histol Embryol.1990; 73:33-42.
19. Sunderland S, Marshall R. The intraneural topography of circumflex, musculocutan-

- eous and obturator nerve. *Brain* 1959; 82:116-29.
20. Guha R, Palit S. A rare variation of anomalous median nerve with absent musculocutaneous nerve and high up division of brachial artery. *J Interacad* 2005; 9: 398-403.
 21. L. Arora, R. Dhingra, Absence of musculocutaneous nerve and accessory head of biceps brachii: a case report .*Indian J Plast Surg* July-December 2005 Vol 38 Issue 2, pg144-46.
 22. Beheiry EE. Anatomical variations of the median nerve distribution and communication in the arm. *Folia Morphol (Warsz)*. 2004; 63(3):313-8.
 23. Prasada Rao PV, Chaudhary SC. Absence of musculocutaneous nerve: two case reports. *Clin Anat*. 2001; 14(1):31-5.
 24. Nakatani T, Mizukami S, Tanaka S. Three cases of the musculocutaneous nerve not perforating the coracobrachialis muscle. *Kaibogaku Zasshi*. 1997; 72(3):191-4.
 25. Virendra Budhiraja, Rakhi Rastogi, Ajay Kumar Asthana *et al*Concurrent variations of median and musculocutaneous nerves and their clinical correlation– a cadaveric study, *Italian Journal of Anatomy and Embryology*, 2011, Vol . 116, n. 2: 67-72.
 26. Avinash A., Bhardwaj R., Prakash R, Bilateral symmetrical dual origin of musculocutaneous Nerve. *J. Anat. Soc. India*, 2006, vol. 55, n. 2: 56-59.
 27. Kaur N and Singla RK. Different types of communications between musculocutaneous & median nerve- A cadaveric study in north Indian population.*CIB Tech J Surg* 2013; Vol. 2 (1): 21-28.
 28. Priti Chaudhary et al., Communicating ramus from lateral root of Median nerve to Ulnar nerve and fusion of Musculocutaneous nerve & Median nerve- a conjunction or co-incidence?- *Int J Anat Res* 2013, 02:93-99. ISSN 2321-4287.
 29. Saddler TW. *Langman's Medical Embryology*. 10th Ed., Philadelphia, Lippincott Williams and Wilkins. 2006; 146-147.
 30. Satyanarayana N, Vishwakarma N, Kumar GP, Guha R, Dattal AK, Sunitha P. Rare variations in the formation of median nerve - embryological basis and clinical significance. *Nepal Med Coll J*. 2009; 11: 287-290.
 31. Satyanarayana N, Guha R, Sunitha P, Reddy GN, Praveen G, Datta AK. A rare variation in the formation of the lower trunk of the brachial plexus its embryological basis and clinical importance - a case report. *J Coll Med Sci Nepal*. 2010; 6: 49-52.
 32. Merrell GA, Barrie KA, Katz DL, Wolfe SW. Results of nerve transfer techniques for restoration of shoulder and elbow function in the context of a meta-analysis of the English literature. *J Hand Surg Am*. 2001; 26(2):303-14.
 33. Yang LJ, Chang KW, Chung KC. A systematic of nerve transfer and nerve repair for the treatment of adult upper brachialplexus injury. *Neurosurgery*. 2012; 71(2):417-29.)
 34. M. Loukas, H. Aqueelah Musculocutaneous median nerve connections within proximal and distal to the coracobrachialis muscle *Folia Morphol (Warsz)*, 64 (2) (2005), pp. 101-108.
 35. C. Bhattarai, P.P. Poudel Unusual variation in musculocutaneous nerves in Nepalese Kathmandu Univ Med J, 7 (4) (2009), pp. 408-410.
 36. Y. Laburthe - Tolra Bases anatomiques des lésions opératoires du nerf musculo - cutané dans la chirurgie de l'épaule *Chirurgie*, 120 (3) (1995), pp. 171-176.

How to cite this article: Parimala NBS. A study of communications of ulnar, median and musculocutaneous nerves. *Int J Health Sci Res*. 2016; 6(4):160-167.
