

Original Research Article

Role of Imaging & Endovascular Intervention in Acute Non-Variceal Gastrointestinal Bleeding

Rammurti S¹, Sarita Sharda²

¹MD (Radiology), MAMS, FICR, Professor & Head, Department of Radiology & Imageology, Nizam's Institute of Medical Sciences, Hyderabad, Telangana, India.

²DNB (Radiology), Nizam's Institute of Medical Sciences, Hyderabad, Telangana, India.

Corresponding Author: Sarita Sharda

Received: 07/02/2016

Revised: 20/02/2016

Accepted: 24/02/2016

ABSTRACT

Objectives: The purpose of this study was to evaluate the effectiveness of angiography and embolotherapy in diagnosis and treatment of acute non variceal gastrointestinal bleed.

Methods: Between May 2009 to April 2014, 64 patients with complaints of acute non-variceal gastrointestinal bleed and subjected to digital subtraction angiography (DSA) ± intervention were included in the study. Embolization was performed of either the pseudo aneurysm or the involved branch artery by using pushable or detachable platinum coils. These patients were followed for a period of 3 months to evaluate the short term efficacy of therapeutic intervention. MDCT/CT Angiography (CTA) wherever available was analysed to evaluate its efficacy in diagnosing and detecting the source of bleeding.

Results: 54 males and 10 females with age range from 10 to 75 years were subjected to conventional angiography (DSA) ± intervention. The source of bleeding was detected by DSA in 44 patients and it was negative in remaining 20. 38 patients had visceral artery pseudo aneurysms, 4 had tumour blush, 1 had angiodysplasia and 1 had superior mesenteric artery thrombosis. MDCT/CTA was available in 33/38 patients with pseudo aneurysms & it could successfully detect 31/34 pseudo aneurysms (2 pseudo aneurysms in 1 patient). Coil embolization was attempted in 30 patients of pseudo aneurysms with success in 29.

Conclusion: CT angiography can be considered as first-line diagnostic imaging modality in patients presenting with acute non-variceal gastrointestinal bleeding. DSA remains the gold standard for precisely localizing the source of active bleeding and provides minimally invasive transcatheter treatment with reduced morbidity, mortality and hospital stay.

Keywords: Digital subtraction angiography, DSA, Embolization, Pseudoaneurysms, Interventions, CT Angiography.

INTRODUCTION

Non-variceal GI Bleeding remains a common and challenging emergency. Upper GI bleeding has an annual incidence of 100 to 200 cases per 100,000, whereas the annual incidence rate of lower intestinal bleeding is estimated to be 20 to 30 cases per 100,000 populations at risk. ^[1]

Causes of Non-variceal GI Bleeding: Upper GI Bleeding: ^[2]

Diagnosis	Incidence [%]
Peptic ulcer	20 - 50
Mallory-Weiss tear	15 - 20
Erosive gastritis/Duodenitis	10 - 15
Oesophagitis/Oesophageal ulcer	5 - 8
Malignancy	1 - 2
Angiodysplasia/Vascular malformations	5
Other	5

Lower GI Bleeding: [3]

Diagnosis	Incidence [%]
Colonic diverticulosis	20 - 55
Angiodysplasia	3 - 40
Neoplasms	8 - 26
Acute colitis	6 - 22
Benign anorectal lesions	9 - 10

Investigations:

- Upper GI Bleeding - Upper G I Endoscopy, CT Abdomen, CT Angiography, Digital Subtraction Angiography (DSA), Nuclear Scintigraphy
- Lower GI Bleeding - Colonoscopy, CT Abdomen, CT Angiography, DSA, Nuclear Scintigraphy

Definitive Management:

- Endoscopic
- Embolization
- Surgery

Role of Angiography:

Catheter-directed Angiography

Angiography can be used for accurate localization as well as treatment of both upper and lower gastrointestinal bleeding. Angiographic evaluation is indicated in the setting of an acutely unstable patient, after a negative or failed endoscopic evaluation, or as a first-line examination for lower gastrointestinal hemorrhage.

• Diagnostic indications:

1. Localizing study or following radionuclide study in the lower GI tract;
2. In upper GI tract, when the diagnosis remains in doubt and patient continues to bleed, bleeding recurs or the site is inaccessible to endoscopy.

• Therapeutic indications (for embolization) :

1. Continued bleeding after therapeutic endoscopy.
2. Active bleeding demonstrated during angiography as contrast extravasation

Sensitivity ranges between 63-90% and 40-86% for upper GI and lower GI bleed respectively and a specificity of up to 100% for both. [4,6] Can detect bleeding rates faster than 0.5 - 1.0ml/min. [5] Increased

accuracy for detecting a bleeding source if there is active bleeding. The use of carbon dioxide (CO₂) as the contrast agent and provocative measures such as direct arterial infusion of vasodilators, thrombolytics, or anticoagulants may increase the sensitivity of selective catheter angiography. Extravasation of contrast material into the bowel lumen is pathognomonic for active gastrointestinal hemorrhage. Indirect signs include detection of pseudoaneurysm, arteriovenous fistula, hyperemia, neovascularity, and extravasation of contrast material into a confined space. [4] Therapeutic angiography (intra-arterial vasoconstrictors or embolization) can represent a definitive treatment or a temporary measure to allow for elective, rather than emergent surgery.

• Limitations:

1. Relative contraindications: severe coagulopathy, congestive cardiac failure, recent myocardial infarct, renal insufficiency, and pregnancy.
2. Complication rate of 2-4%.

Role of Embolization:

Transcatheter arterial embolization as treatment of choice in non-variceal gastrointestinal bleeding is increasingly being used after failed primary endoscopic treatment. Embolization of the bleeding vessel is the mainstay of transcatheter treatment for non-variceal gastrointestinal bleeding, and high technical success rates (angiographic cessation of bleeding) of 91%–100% have been reported. [6,7] Clinical success rates (cessation of bleeding for 30 days) of 68%–82.5% for upper gastrointestinal bleeding [8,9] and 81%–91% for lower gastrointestinal bleeding [7,10] have been reported. Transcatheter arterial embolization is a valuable minimally invasive method in the treatment of early rebleeding and does not involve a high risk of treatment associated complications.

In patients with acute lower gastrointestinal bleeding, colonoscopy is the initial test of choice. But when colonoscopy gives indeterminate results or cannot be performed, either radionuclide imaging or

angiography is indicated. The two major options for angiographic therapy of lower GI bleeding are vasopressin infusion and transcatheter embolization. Vasopressin now is rarely used in modern angiographic practice, since it requires monitoring in an intensive care unit, the catheter position must be maintained for several hours, and it occasionally causes significant complications, including arrhythmias, cardiac ischemia, intestinal ischemia, and cerebral edema.

Transcatheter embolization of an arterial bleeding site is accomplished by placing a micro catheter in the arterial branch leading to the site of extravasation. Platinum microcoils then are deployed from the catheter tip, blocking the feeding artery branch and reducing blood pressure at the site of bleeding. Other common embolic agents include polyvinyl alcohol particles, gelfoam, n-butyl cyanoacrylate glue, and embucrylate tissue adhesive. Microcoil embolization is typically preferred within the lower gastrointestinal tract, whereas controversy exists regarding the optimal agent within the upper gastrointestinal tract. In fact, combinations of different embolic agents may be more effective than embolization with a single agent in the upper gastrointestinal tract. [9]

Aims and Objectives

- To study the role of MDCT in diagnosing and detecting the site of active bleeding in acute non variceal gastrointestinal bleed.
- To study the effectiveness of angiography and embolotherapy in diagnosis and treatment of acute non variceal gastrointestinal bleed.
- To assess the immediate and short term (3 months) success of the interventions and to evaluate the incidence of re-bleed.

MATERIALS AND METHODS

The study is carried out in the Department of Radiology and Imageology & Surgical Gastroenterology, Nizam's Institute of Medical Sciences, Hyderabad.

Data of 64 patients who presented with acute non variceal gastrointestinal bleeding and subjected to DSA ± intervention was evaluated over a period of five years (May 2009 to April 2014). MDCT/ CT Angiography wherever available was analysed to evaluate its efficacy in diagnosing and detecting the source of bleeding. Cases were selected irrespective of age and sex. These cases were referred from Departments of Surgical and Medical Gastroenterology for imaging and intervention. Informed consent of the subjects was obtained in writing for their inclusion in the study. Standard proforma was used for recording individual case data. These patients were followed for a period of 3 months to evaluate the short term efficacy of therapeutic intervention.

Inclusion Criteria:

- Proven cases of acute non variceal gastrointestinal bleed with
 - Limitations on endoscopic diagnosis or management
 - Post operative cases where surgical management was limited
 - Iatrogenic complications resulting in gastrointestinal bleed.

Exclusion Criteria:

- Patients with variceal gastrointestinal bleed.
- Patients not willing to give the written consent were excluded from the study.

Methodology

Pre-treatment clinical evaluation for each patient included recording the presenting signs, symptoms and reports of relevant haematological procedures including coagulation profile and renal parameters. Subsequently all the patients underwent visceral angiography study on Digital Subtraction Angiography System, Axiom Artis FA Platinum (Siemens Medical Systems, Erlangen, Germany). Most of the patients underwent therapeutic procedure of embolization. MDCT including CTA, wherever available was analysed for its ability to diagnose and localize the source of bleeding.

Angiography was performed by transfemoral arterial access using 18 gauge needle and Seldinger technique. A 0.035" guide wire was advanced through the needle and directed into the abdominal aorta under fluoroscopic guidance. A 4 or 5 Fr calibrated pigtail catheter was advanced over the wire and positioned in the abdominal aorta at the level of L1 vertebral body. Flush aortogram was performed in the AP projection. Selective injections of celiac axis, SMA and IMA were obtained. Once the bleeding source was identified angiographically, sub selective cannulation of the involved branch artery was done using a microcatheter (Progreat/ 2.7-2.9F/ Terumo or Echelon-10/eV3) which was advanced coaxially through the indwelling 4 or 5-French catheter over a compatible micro guidewire. Check arteriogram was done to localize the arterial branch feeding the pseudo aneurysm or feeding the tumour. Attempts were made to position the catheter as close to the bleeding site as possible under auto map guidance. Embolization was performed of either the pseudo aneurysm (endosaccular embolization) or the involved branch artery depending upon the collateral circulation to the organ concerned by using pushable or detachable platinum coils of different dimensions based upon the size of the sac and neck of pseudoaneurysm.

Technical success was defined as cessation of bleeding as seen on

Etiology of Pseudo aneurysms:

Site of Aneurysm	Pancreatitis	Trauma (blunt injury)	Iatrogenic trauma	Idiopathic
Splenic artery (n=15)	13 (87%)	-	-	2 (13%)
Hepatic artery (n=10)	-	6 (64%)	4 (36%)	-
GDA(n=9)	5 (56%)	-	3 (33%)	1 (11%)
Inf. PDA(n=2)	2 (100%)	-	-	-
Supraduodenal branch of hepatic artery (n=1)	-	-	-	1 (100%)
Iliocolic branch of SMA (n=1)	-	-	-	1 (100%)

MDCT/ CTA findings

MDCT/CTA was available in 33 out of the 38 patients with pseudo aneurysms. MDCT/ CTA could successfully detect 31 out of the 34 pseudo aneurysms (two pseudo aneurysms in one patient) accounting for 91% true positivity. However it was false

angiography. Clinical success was defined as cessation of bleeding without further endoscopic, radiological or surgical intervention.

RESULTS

From May 2009 to April 2014, 64 patients who presented with acute non variceal gastrointestinal bleeding and subjected to conventional angiography (DSA) ± intervention were evaluated. Of the total 64 patients, 54 were male (84%) and 10 were females (16%).The age ranged from 10 to 75 years with a mean age of 37 years and a median of 37 years.

Site of Gastrointestinal Bleeding

61 (95%) presented with upper GI bleed and rest three (5%) presented with lower GI bleed.

Etiology of Gastrointestinal Bleed

DSA could identify etiology of gastrointestinal bleeding in 44 patients, it was however normal in rest of the 20 patients.

Etiology	No. Of Cases
Visceral artery pseudoaneurysms	38 (86.4%)
Tumour	4 (9.1%)
Angiodysplasia	1 (2.27%)
Superior Mesenteric Artery(SMA) thrombosis	1 (2.27%)

Location of Pseudoaneurysms:

Visceral Artery Pseudoaneurysms (VAA)	No. of cases
Splenic artery	15 (38%)
Hepatic artery	10 (28%)
Gastroduodenal artery (GDA)	9 (23%)
Inferior pancreaticoduodenal artery (Inf.PDA)	2 (5%)
Supraduodenal branch of hepatic artery	1 (3%)
Iliocolic artery branch of SMA	1 (3%)

negative in rest three patients (9%), all the three pseudo aneurysms (two involving GDA and one involving splenic artery) were small in size.

Tumours

Out of the 4 tumours, three were Gastrointestinal Stromal Tumours (GIST)

and the other was pancreatic tumour (Recurrent inflammatory my fibroblastic tumour).

Therapeutic Interventions (Figures 1-3)

39 pseudo aneurysms in 38 patients; 1 patient had two hepatic artery pseudo aneurysms (Figure 1)

Coil embolization in Pseudoaneurysms	Successful	Failed
Attempted (n=30)	29(97%)	1 (3%) due to distal migration of coils in a case of splenic artery pseudo aneurysm
Deferred (n=9)	-	-

In 9 patients with pseudo aneurysms, therapeutic intervention was not undertaken due to various causes. Five patients had financial constraints. There was technical limitation to coil embolization in two pseudo aneurysms (one was splenic and one was hepatic). In one patient, there was self occlusion of the involved artery (splenic) (Figure 4). Another patient with splenic artery pseudo aneurysm due to pancreatitis was too sick during angiogram study and he had to be taken for emergency surgery.

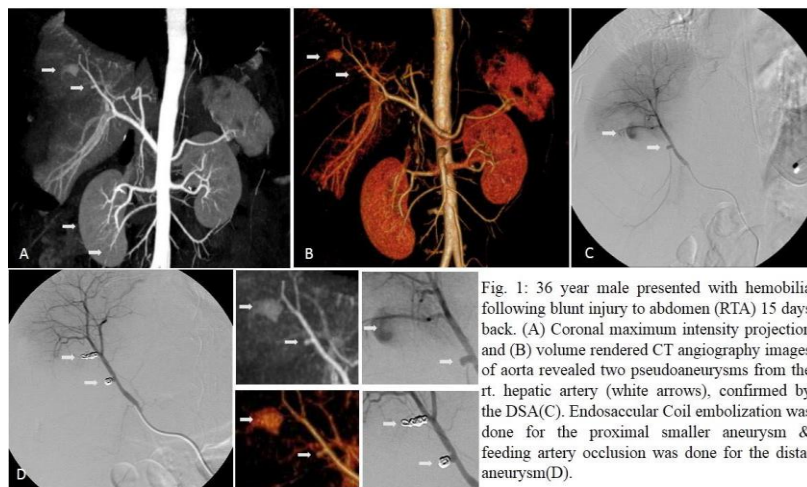


Fig. 1: 36 year male presented with hemobilia following blunt injury to abdomen (RTA) 15 days back. (A) Coronal maximum intensity projection and (B) volume rendered CT angiography images of aorta revealed two pseudoaneurysms from the rt. hepatic artery (white arrows), confirmed by the DSA.(C). Endosaccular Coil embolization was done for the proximal smaller aneurysm & feeding artery occlusion was done for the distal aneurysm(D).

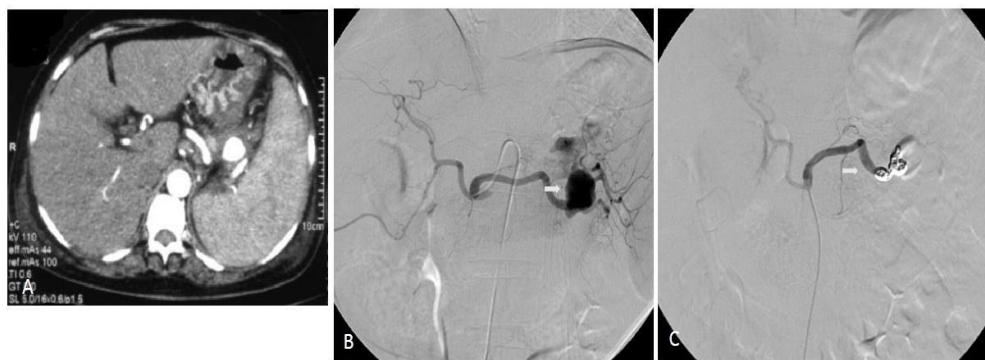

Figure 2: 45 year female known case of acute pancreatitis presented with hematemesis and melena. CT Angiogram (A) revealed splenic artery pseudoaneurysm confirmed by DSA (B). Post coil embolization check angiogram (C) reveals obliteration of flow across the aneurysm.

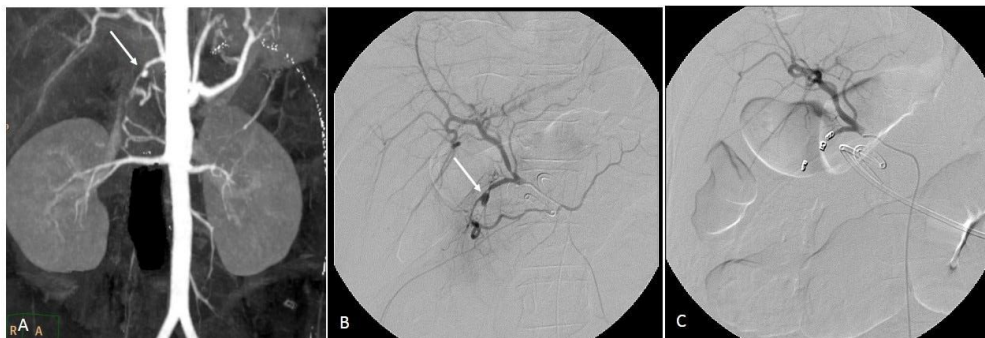


Figure 3: 35 year male, a known case of acute pancreatitis presented with melena. (A) CT Angiogram (MIP) revealed a pseudoaneurysm arising from GDA (white arrow), confirmed by DSA (B). Coil embolization was done proximal and distal to the neck of the aneurysm. Post Coil embolization check angiogram (C) reveals no flow across the embolized segment.

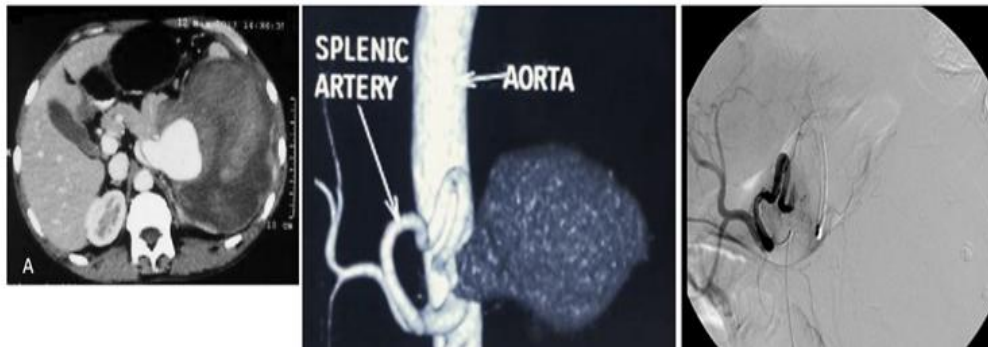


Figure 4: A 38 year male presented with melena. CECT abdomen (A) revealed large pseudoaneurysm arising from splenic artery, confirmed by (B) Volume rendered projection. DSA (C) reveals spontaneous occlusion of the parent artery with non-opacification of the aneurysm

Tumour (n=4)	Preoperative particulate embolization using PVA particles (300-500 μ) followed by operation	Other
GIST (n=3)	2	Radiotherapy
Recurrent myofibroblastic tumour of pancreas (n=1)	1	-

PVA= Polyvinyl alcohol

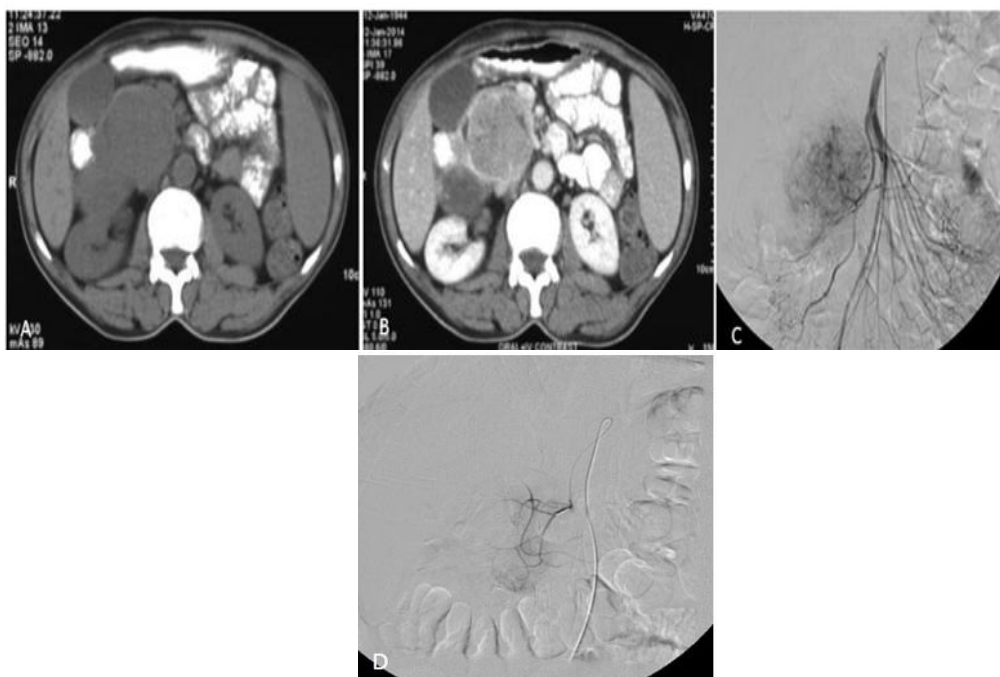


Figure 5: 70 year male with melena. CECT Abdomen (A) & (B) reveals hypodense enhancing lesion abutting 2nd part of duodenum. DSA (C) reveals moderately vascular lesion with feeders from SMA. Pre-operative particulate embolization (D) with significant flow reduction. Surgically proven GIST from the duodenum.

Complications

No major immediate or short term (3 months) complications were observed in 29 of visceral artery aneurysms that underwent technically and clinically successful embolization.

Follow Up

All the patients who were subjected to therapeutic intervention were followed up for a mean period of 3 months, most of them on OPD basis and the rest were contacted through telephonic conversation. None of

the patients with successful coil embolization of pseudoaneurysms had further episode of gastrointestinal bleeding (100 %).

DISCUSSION

In our study 61 (95%) patients presented with upper GI bleeding and 3 (5%) with lower GI bleeding. In a study by Yap et al [11] out of the 95 patients (male: female ratio = 53:42, mean age 62 years) that underwent transcatheter arterial

embolization (TAE) of acute gastrointestinal (GI) bleeding at their institute between 2002 and 2010, seventy-six of 95 (80 %) patients had upper GI bleeds and 19/95 (20 %) patients had lower GI bleeds.

In our study out of the 64 patients, source of bleeding was detected by DSA in 44 patients (68.7%) and it was negative in remaining 20 patients (31.3 %). Kim et al [12] evaluated the incidence of angiographically negative acute arterial upper and lower gastrointestinal (GI) bleeding where in the angiographies revealed a negative bleeding focus in 75 of 143 (52%) patients.

Visceral artery aneurysm was the cause of bleeding in 38 patients (86%). The incidence of involvement of various visceral arteries by aneurysms in our study is well in accordance with the literature where in splenic artery involvement is described to be the most common. In a retrospective study by Ferrero et al [13] wherein they reviewed the visceral artery aneurysms between 2000 and 2010 treated at their centre, out of the total 32 patients (17 males; mean age: 64.7 [range: 18-85] years), the site of aneurysmal disease was splenic artery (18), hepatic artery (5), superior mesenteric artery (3), pancreaticoduodenal artery (3), celiac axis (2), and gastro duodenal (1).

The increase in the hepatic artery aneurysms in our study as compared to other studies could be probably attributed to the underlying cause being trauma (7 out of 11), since our hospital is tertiary care centre for trauma related services.

Of the 39 pseudo aneurysms, the underlying etiology was pancreatitis in 20 where in splenic artery was involved in 13 patients (65%), GDA in 5 patients(25%) and inferior pancreatic duodenal artery in 2 patients (10%). The findings in our study are in accordance with the literature. In a study by Boudghène et al [14] wherein they retrospectively examined the arterial lesions in 104 cases (87 men, 17 women; age range, 21–80 years; mean, 48 years) related to pancreatitis, the various arteries involved were - splenic (42%), the gastro duodenal

(22%), and the small pancreatic arteries (25%).

Independent of the etiology, the natural history of most VAA aneurysms appears to be expansion and eventual rupture, with life threatening consequences. The frequency of hepatic and splenic aneurysm rupture may be as high as 1 in 5 patients, and 5% to 10% of patients with pancreatitis will experience VAA ruptures(29). If pseudo cysts are present, the rate rises to 20%(29). The mortality after rupture has been up to 35% for hepatic aneurysms and 50% for gastro duodenal aneurysms. [15] Because of the unpredictable course of these lesions, an aggressive therapeutic approach is indicated.

MDCT/CTA was available in 33 out of the 38 patients with pseudo aneurysms and it could successfully detect 31 out of the 34 pseudo aneurysms (two pseudo aneurysms in one patient) suggesting a true positivity of 91%. However it was false negative in rest three patients accounting for 9% and all these three pseudo aneurysms (two involving GDA and one involving splenic artery) were small in size.

As per a meta-analyses regarding the accuracy of computed tomography (CT) angiography in the diagnosis of acute gastrointestinal (GI) bleeding by Ming wu et al [16] where in 9 studies with 198 patients from January 1995 to December 2009 were evaluated, CT angiography showed pooled sensitivity of 89% (95% CI: 82%-94%) and specificity of 85% (95% CI: 74%-92%).

The only case wherein coil embolization was not successful in our study was in a 15 year old boy who presented with acute non-variceal upper gastrointestinal bleed and was diagnosed to have splenic artery aneurysm on CECT abdomen, the underlying cause of which could not be identified. DSA revealed the same finding as that of CECT abdomen. Attempt was made to embolize the aneurysm, but there was distal migration of coils and procedure was thus abandoned. The patient left the hospital against medical advice and was then lost to follow up.

In a study by Fankhauser et al [17] they reviewed their 10-year experience (June 1999 to June 2009) with the minimally invasive methods (MIM) of treating VAA. MIM was attempted in 185 aneurysms in 176 patients. Initial intervention was successful in 98% of aneurysms. Sixty-three (34%) aneurysms were located in the splenic artery, 56 (30%) in the hepatic, 28 (15%) in the gastro duodenal, 16 (8.6%) in the pancreatic duodenal, six (3.2%) in the superior mesenteric, four (2.1%) in the gastric, four (2.1%) in the celiac, four (2.1%) in the gastroepiploic, two (1%) in the inferior mesenteric, and one (0.5%) in the middle colic artery.

In our study, GIST was responsible for gastrointestinal bleeding in three cases, one each in duodenum, ileum and rectum. Particulate embolization using PVA particles (300 to 500 microns) was done in two patients with obliteration of tumour blush on check angiogram. These patients subsequently underwent curative resection of tumours. Concerning the hemorrhagic potential of GIST, some authors have already reported high incidences of presentation with bleeding, 87% of duodenal GISTs and 64% of other small bowel GISTs. Other locations like gastric, rectal or colonic are associated with less than 45% incidence of bleeding. [18]

Another tumour which was responsible for acute non-variceal GI bleed in our study was a 10 year old boy who presented with malena. CECT abdomen revealed hyper vascular lesion in pancreatic head. DSA revealed hyper vascular tumour with feeders from SMA which were embolized using PVA particles. The patient continued to bleed and underwent resection of tumour which turned out to be inflammatory myofibroblastic tumour.

Inflammatory myofibroblastic tumors (IMT's) are rare solid lesions that occur primarily in visceral and soft tissue. Most frequently they occur in the first two decades of life. The most common localizations of IMTs have been reported in

lung, mesentery and omentum. Only 29 cases of pancreatic inflammatory myofibroblastic tumors have been reported so far with age ranging from 2.5 to 70 years and 60% being located in the pancreatic head. [19] The tumour in pancreas is known to present with anemia in 20% cases. [20]

CONCLUSION

1. CT angiography (CTA) can be considered as a first-line diagnostic imaging modality in patients presenting with acute non-variceal gastrointestinal bleeding.
2. CTA not only detects the source of bleeding, but also identifies the underlying etiology of the same.
3. It provides the anatomy of arterial system, necessary guidance for DSA and subsequent therapeutic interventions.
4. DSA remains the gold standard for precisely localizing the source of active bleeding and provides minimally invasive transcatheter treatment with reduced morbidity, mortality and hospital stay.
5. Endovascular treatment of visceral artery aneurysms is the ideal method of management in surgically hard-to-access intrapancreatic and peripancreatic territories especially in hostile environments of pancreatitis and abdominal sepsis.

REFERENCES

1. Longstreth GF. Epidemiology of Hospitalization for Acute Upper Gastrointestinal Hemorrhage: A Population--Based Study. *Am J Gastroenterol.* 1995; 90(2).
2. Ferguson CB, Mitchell RM. Non-variceal upper gastrointestinal bleeding. *Ulster Med J. Ulster Medical Society;* 2006; 75(1):32.
3. Laing CJ, Tobias T, Rosenblum DI, Banker WL, Tseng L, Tamarkin SW. Acute gastrointestinal bleeding: emerging role of multidetector CT angiography and review of current

- imaging techniques. *Radio Graphics* 2007; 27(4):1055–1070.
4. Lee EW, Laberge JM. Differential diagnosis of gastrointestinal bleeding. *Tech VascInterv Radiol*. Elsevier; 2004; 7(3):112–22.
 5. Baum ST. Arteriographic diagnosis and treatment of gastrointestinal bleeding. *Abram's Angiogr Interv Radiol* 2nd edn Lippincott Williams Wilkins, Philadelphia. 2006; 488.
 6. Vernava III AM, Moore BA, Longo WE, Johnson FE. Lower gastrointestinal bleeding. *Dis colon rectum*. Springer; 1997; 40(7):846–58.
 7. Kuo WT, Lee DE, Saad WEA, Patel N, Sahler LG, Waldman DL. Superselectivemicrocoil embolization for the treatment of lower gastrointestinal hemorrhage. *J VascIntervRadiol*. Elsevier; 2003; 14(12):1503–9.
 8. Defreyne L, Vanlangenhove P, Decruyenaere J, Van Maele G, De Vos M, Troisi R, et al. Outcome of acute nonvariceal gastrointestinal haemorrhage after no therapeutic arteriography compared with embolization. *EurRadiol*. Springer; 2003; 13(12):2604–14. 97
 9. Aina R, Oliva VL, Therasse É, Perreault P, Bui BT, Dufresne M-P, et al. Arterial embolotherapy for upper gastrointestinal hemorrhage: outcome assessment. *J VascInterv Radiol*. Elsevier; 2001; 12(2):195–200.
 10. Funaki B, Kostelic JK, Lorenz J, Ha T Van, Yip DL, Rosenblum JD, et al. Super selective micro coil embolization of colonic hemorrhage. *Am J Roentgenol*. Am Roentgen Ray Soc; 2001; 177(4):829–36.
 11. Yap FY, Omene BO, Patel MN, Yohannan T, Minocha J, Knuttinen MG, et al. Transcatheter embolotherapy for gastrointestinal bleeding: A single center review of safety, efficacy, and clinical outcomes. *Dig Dis Sci*. Springer; 2013; 58(7):1976–84.
 12. Kim JH, Shin JH, Yoon H-K, Chae EY, Myung S-J, Ko G-Y, et al. Angiographically negative acute arterial upper and lower gastrointestinal bleeding: incidence, predictive factors, and clinical outcomes. *Korean J Radiol*. 2009; 10(4):384–90.
 13. Ferrero E, Ferri M, Viazzo A, Robaldo A, Carbonatto P, Pecchio A, et al. Visceral artery aneurysms, an experience on 32 cases in a single center: treatment from surgery to multilayer stent. *Ann Vasc Surg*. Elsevier; 2011; 25(7):923–35.
 14. Boudghène F, L'Herminé C, Bigot J-M. Arterial complications of pancreatitis: diagnostic and therapeutic aspects in 104 cases. *J VascInterv Radiol*. Elsevier; 1993; 4(4):551–8.
 15. Gabelmann A, Görlich J, Merkle EM. Endovascular treatment of visceral artery aneurysms. *J Endovasc Ther*. 2002; 9(1):38–47.
 16. Wu L-M, Xu J-R, Yin Y, Qu X-H. Usefulness of CT angiography in diagnosing acute gastrointestinal bleeding: a meta-analysis. *World J Gastroenterol WJG*. Baishideng Publishing Group Co., Ltd.; 2010; 16(31):3957.
 17. Fankhauser GT, Stone WM, Naidu SG, Oderich GS, Ricotta JJ, Bjarnason H, et al. The minimally invasive management of visceral artery aneurysms and pseudoaneurysms. *J Vasc Surg*. Elsevier; 2011; 53(4):966–70.
 18. Vilallonga R, Sanchez JL, Armengol M. Gastrointestinal Stromal Tumor: Cause of Gastrointestinal Bleeding. *Gastroenterol Res*. 2010; 3(2):93–5.
 19. Tomazic A, Gvardijancic D, Maucec J, Homan M. Inflammatory myofibroblastic tumor of the pancreatic head—a case report of a 6 months old child and review of the

literature. Radiol Oncol. 2015 Sep;
49(3):265–270.
20. Pungpapong S, Geiger XJ,
Raimondo M. Inflammatory

myofibroblastic tumor presenting as
a pancreatic mass: a case report and
review of the literature. Jop. 2004;
5(5):360–7.

How to cite this article: Rammurti S, Sharda S. Role of imaging & endovascular intervention in acute non-variceal gastrointestinal bleeding. Int J Health Sci Res. 2016; 6(3):43-52.

International Journal of Health Sciences & Research (IJHSR)

Publish your work in this journal

The International Journal of Health Sciences & Research is a multidisciplinary indexed open access double-blind peer-reviewed international journal that publishes original research articles from all areas of health sciences and allied branches. This monthly journal is characterised by rapid publication of reviews, original research and case reports across all the fields of health sciences. The details of journal are available on its official website (www.ijhsr.org).

Submit your manuscript by email: editor.ijhsr@gmail.com OR editor.ijhsr@yahoo.com