

Case Report

Xanthogranulomatous Salpingo-Oophoritis Presenting as Tubo-Ovarian Mass- A Case Report with Brief Review of Literature

Swati Sharma^{1*}, Priyanka Phadnis^{2*}, Ranjini Kudva^{3*}, Manna Valiathan^{4*}, Jyothi Shetty^{3**}

¹Associate Professor, ²Junior Resident, ³Professor, ⁴Professor and Head,

*Department of Pathology, Kasturba Medical College, Manipal University, Manipal, Karnataka, India.

**Department of OBG, Kasturba Medical College, Manipal University, Manipal, Karnataka, India.

Corresponding Author: Swati Sharma

Received: 21/01/2016

Revised: 15/02/2016

Accepted: 16/02/2016

ABSTRACT

Xanthogranulomatous salpingo-oophoritis is a rare form of chronic granulomatous inflammation with many etiologic factors implicated in the pathogenesis. On radiology its presents as well defined solid mass mimicking malignancy. Grossly the mass shows yellowish necrotic material and on microscopy the affected organ has disorganization and infiltration with focal or sheets of foam cells admixed with chronic inflammatory cells such as lymphocytes, plasma cells, occasional neutrophils with or without multinucleated or Touton giant cells. The awareness of this inflammatory lesion among clinicians and the pathologists can prevent misdiagnosis and radical surgery.

Key words: xanthogranulomatous, oophoritis, tubo-ovarian.

INTRODUCTION

Xanthogranulomatous inflammation is a rare form of chronic inflammation causing destruction to the normal tissues of affected organs. On histology, it is characterized by the presence of a large number of lipid-containing macrophages with an admixture of lymphocytes, plasma cells, neutrophils and at times multinucleated giant cells. There is no minimal amount requirement for the histiocytes to make this diagnosis. Most common affected organ described is kidney followed by gall bladder. Other organs where xanthogranulomatous inflammation has been reported include stomach, anorectal region, bone, urinary bladder, testis and epididymis. Female genital tract involvement is relatively uncommon and is mostly confined to the endometrium, however rare involvement of the vagina, cervix, fallopian tube and ovary has been

documented. Clinically it forms mass like lesion in the pelvic cavity and causes invasion of the surrounding tissues. Only a few cases of xanthogranulomatous salpingo-oophoritis have been reported in literature. (1-3)

CASE REPORT

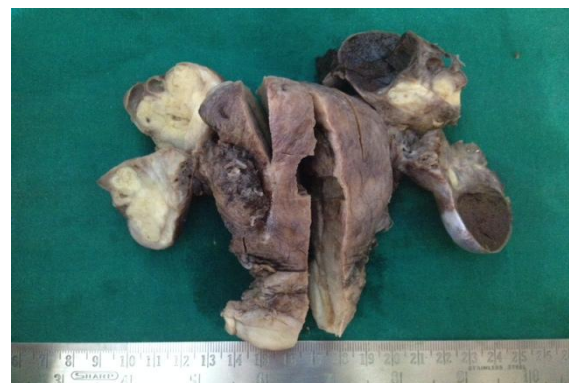

Fig 1: Left tubo-ovarian mass measured 4x4x4 cm with yellow solid and cystic cut surface. Right ovary with solid yellow areas. Endomyometrium, right fallopian tube and fibroid were unremarkable

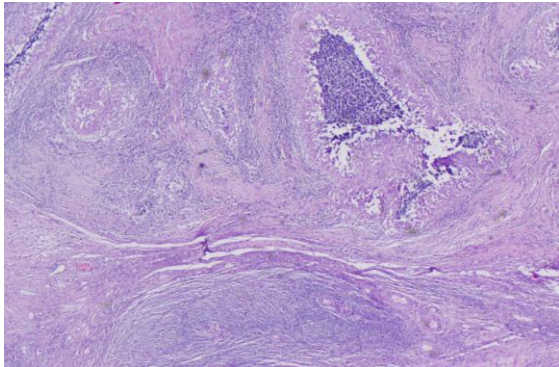


Fig 2: Replacement of normal ovarian parenchyma with large granuloma H&E X20

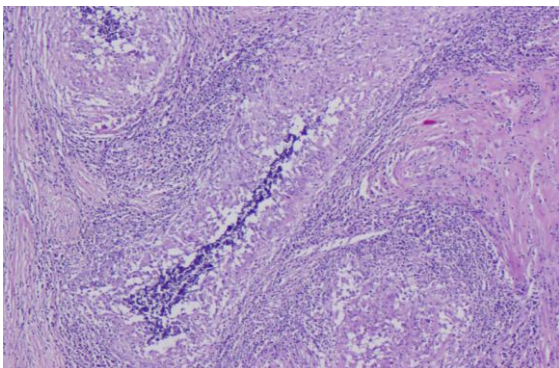


Fig 3: Sheets of foamy macrophages along with multiple granulomas with central necrosis H&E X40

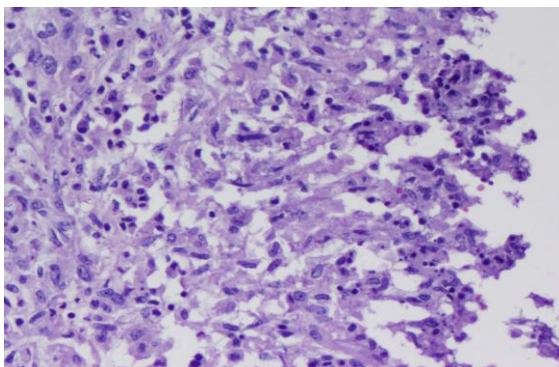


Fig 4: Granulomas composed of epithelioid cells, langhans and multinucleated giant cells, cuff of lymphocytes with central necrosis H&E X200

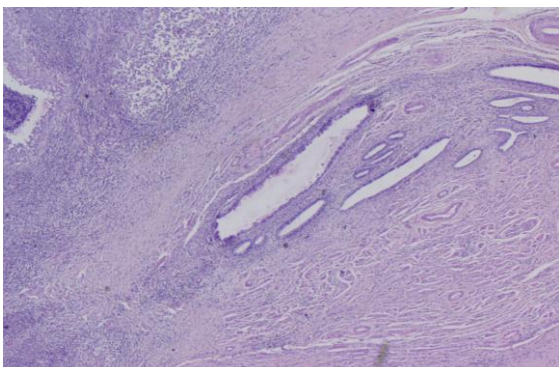


Fig 5: Focally preserved ovarian parenchyma and entrapped tubal tissue H&E X20

pain in the lower abdomen and discharge per vaginum since 15 days. She had one episode of high grade fever initially but subsided on its own. Discharge per vaginum is profuse and foul smelling. She had irregular menstrual cycles since 2-3 months. She has been married since 23 years and last child birth was 17 years back by caesarian section and tubal sterilization had been done. She had undergone myringoplasty of the left ear 1.5 years back. There was no history of tuberculosis infection in the family. On examination she had pallor. Per abdomen, midline vertical subumbilical scar with incisional hernia measuring 4x 3cm seen. Per speculum cervix and vagina were healthy and white discharge was noted. Per vaginum uterus was bulky. On ultrasound abdomen uterus measured 10x 8x 7 cm with a posterior myometrial fibroid measuring 6.2x 5.7 cm. Cystic lesion in the left adnexae measuring 5.3x 4.4 cm with hypoechoic areas and calcifications. She was planned for laparoscopic total abdominal hysterectomy and repair of incisional hernia. Intraoperative in view of multiple adhesions, appendicectomy and cholecystectomy were also done. Grossly left tubo-ovarian mass measured 4x4x4 cm with yellow solid and cystic cut surface. Right ovary showed focal solid yellow areas. Endomyometrium, right fallopian tube and fibroid were unremarkable (Fig 1). On histology the sections from left adnexal mass showed sheets of foamy macrophages along with multiple granulomas composed of epithelioid cells, langhans and multinucleated giant cells, cuff of lymphocytes with central necrosis and calcific deposits. Focally preserved ovarian parenchyma and entrapped tubal tissue were also seen (Fig 2,3,4,5). Right sided ovary also showed granulomas, hemorrhagic corpus luteal cyst, corpus albicans, follicular cyst and inclusion cysts. Acid fast stain, periodic acid-schiff and grams stain done for tuberculosis, fungal infection and actinomycosis were negative. A diagnosis of xanthogranulomatous salpingo-oophoritis was given. The gall bladder and appendix

A 44 year old lady to the gynecology outpatient department with the complains of

were unremarkable. Patient is on regular follow up.

DISCUSSION

Kunakemakorn first described xanthogranulomatous inflammation of serosa of uterus, left fallopian tube and ovary in his report of inflammatory pseudo tumor in the pelvis in the year 1976. ⁽⁴⁾ Bacterial infections, immunosuppression, chronic inflammatory conditions, luminal obstruction, endometriosis, leiomyoma, abnormal lipid metabolism, ineffective antibiotic therapy, ineffective clearance of bacteria by phagocytes and chronic irritation of the urachal remnant have been implicated in its pathogenesis. ⁽⁵⁾ The most accepted theory is of infection which is supported by clinical evidence of infection and growth of certain bacteria such as *Escherichia coli*, *Bacteroides fragilis*, *Proteus vulgaris* and *Salmonella typhi* from the tissue culture. However, it is difficult to explain the excessive amount of foamy macrophages containing lipids by the theory of infection exclusively. ^(1,2) Singh UR et al ⁽⁶⁾ have described xanthogranulomatous oophoritis as a complication of typhoid.

The average age of presentation is 38.5 years and ranges between 23 to 72 years. The youngest case reported was of 18 years. The clinical presentation includes fever, abdominal mass, pain in the abdomen, menorrhagia, anemia and anorexia. Gynecological examination reveals adnexal mass with tenderness. Laboratory tests may show elevated ESR and raised white blood cell count. Contrast-enhanced CT shows complex solid-cystic lesions with thick enhancing walls and variably enhancing solid intramural nodules, hence mimicking ovarian neoplasm. ^(2,7)

Grossly the affected ovary is usually enlarged and the size varies from 3-17 cm. The normal ovarian parenchyma is replaced by tumor like yellow colored nodular mass, occasionally cystic due to liquefactive necrosis. The inflammation may extend beyond the ovary and involves the neighboring organs commonly fallopian

tube as well as adjacent pelvic peritoneum resulting in adhesions, hereby making the lesion suspicious for malignancy. The characteristic histology shows sheets of foamy histiocytes, ill formed granulomas, multinucleated giant cells and inflammatory cells. This fibrous organization of the chronic inflammatory process is probably responsible for the pseudotumoral appearance on gross examination. Differential diagnosis includes both non-neoplastic and neoplastic conditions. Non-neoplastic conditions include tuberculosis and fungal infections which can be ruled out by performing special stains or by culture. Because of the presence of foamy histiocytes, malakoplakia may also to be considered in the differential diagnosis. According to Wather, ⁽⁸⁾ malakoplakia and xanthogranulomatous inflammation share a common pathogenetic mechanism. Malakoplakia characteristically shows the cytoplasmic concentric calcific bodies known as Michaelis- Gutmann bodies which are absent in xanthogranulomatous inflammation. Neoplastic conditions include lymphoma or leukemia, malignant small cell tumor and sclerosing stromal tumor. ^(2,7) However, microscopy along with special stains confirms the diagnosis. Frozen section may also be used and is very helpful diagnostic modality in cases where xanthogranulomatous inflammation mimics a neoplasm. On, immunohistochemistry histiocytes are positive for CD68. ⁽⁷⁾

Granulomatous salpingo-oophoritis in surgical pathology practice in developing countries may be seen in many other conditions most common being tuberculosis. Others include a foreign body reaction to suture material introduced at a previous operative procedure, associated Crohn's disease, previous diathermy, a necrotizing reaction following previous surgery, endometriosis and bacterial tubo-ovarian abscess. In few cases no cause could be attributable for the granulomatous inflammation and small cortical granulomas in the ovary are seen called as idiopathic granulomas. ⁽⁹⁾ Our case had history of tubal

ligation 17 years back at the time of last child birth. We also noted a suture material in the section of the adnexal mass with foci of calcifications. There was no history of tuberculosis, any other surgery, endometriotic focus. Also the acid fast stain, fungal and bacterial stains were negative. She was not evaluated for abnormality in the lipid metabolism.

Treatment of choice for xanthogranulomatous salpingo-oophoritis is salpingo-oophorectomy. Antibiotic therapy has been tried earlier but it has not been successful in reducing ovarian mass. (2,7) Patients with pelvic inflammatory disease, endometriosis, leiomyomas and intra uterine contraceptive device should be followed up because of their close association with xanthogranulomatous inflammation. Our case also had associated leiomyoma.

CONCLUSION

Xanthogranulomatous inflammation of the female genital tract is rare and ovarian involvement as such is further rarer. Xanthogranulomatous salpingo-oophoritis mimics ovarian malignancy clinically and on radiology. It may cause diagnostic dilemma even to the pathologist because of the rarity of this condition. Preoperative frozen section and precise histopathological examination may enlighten the inflammatory pathology of the lesion and help in preventing radical surgeries.

REFERENCES

1. Zhang X, Dong H, Zhang L, Desouki MM, Zhao C. Xanthogranulomatous

- Inflammation of the Female Genital Tract: Report of Three Cases. *Journal of Cancer*. 2012;3:100-6
2. Date S, Sulhyan K, Badge S, Gosavi A, Ramteerthkar N. Xanthogranulomatous oophoritis : Case Report. *Indian Journal of Basic & Applied Medical Research* 2013;7(2):745-9
3. Shashikala K, Sharmila PS, Sushma T A, Francis P. Ovarian haemangioma with synchronous xanthogranulomatous inflammation-a rare pathological finding. *Int J Health Sci Res*. 2013;3(5):116-9
4. Kunakemakorn P, Ontai H. Pelvic inflammatory pseudotumor: A case report. *Am J Obstet Gynecol*. 1976; 26: 286-7
5. Yener N, Ilter E, Midi A. Xanthogranulomatous salpingitis as a rare pathologic aspect of chronic active pelvic inflammatory disease. *Indian J Pathol Microbiol*. 2011 Jan-Mar;54(1):141-3
6. Singh UR, Revathi G, Gita R. Xanthogranulomatous oophoritis: an unusual complication of typhoid. *J ObstetGynaecol (Tokyo)* 1995. 1995 Oct; 21(5): 433-6
7. Gupta N, Gupta C. Xanthogranulomatous oophoritis-masquerading as ovarian neoplasm: report of two cases. *Annals of Pathology and Laboratory Medicine* 2015;2(1): C 24-7
8. Walther M, Glenn JF, Vellios F. Xanthogranulomatous cystitis. *J Urol*, 1985;134: 745-6
9. McCluggage WG, Allen DC. Ovarian granulomas: a report of 32 cases. *J ClinPathol* 1997;50:324-7

How to cite this article: Sharma S, Phadnis P, Kudva R et al. Xanthogranulomatous salpingo-oophoritis presenting as tubo-ovarian mass- a case report with brief review of literature. *Int J Health Sci Res*. 2016; 6(3):316-319.
