

Original Research Article

A Research Analysis on Pregnancy Tumor - Correlation with Pyogenic Granuloma

Navjot Singh Sasan¹, Rahul Kaul², Parul Jain², Paras Angrish², Kashika Arora², Sagar Lahu Pable²

¹Junior Resident (Non-Academic), Department of Prosthodontics, Indira Gandhi Govt. Dental College, Jammu Jammu and Kashmir, India.

²Junior Resident, Department of Pedodontics and Preventive Dentistry, Dr. R.Ahmed Dental College and Hospital, Kolkata, India.

Corresponding Author: Rahul Kaul

Received: 08/11/2015

Revised: 23/12/2015

Accepted: 04/01/2016

ABSTRACT

Objectives: There is an ongoing debate regarding the clinical term “Pregnancy Tumor”- whether it should be used or not. Based on its clinical appearance and histological findings, few investigators consider it to be just a representation of pyogenic granuloma, whereas others believe it to be a distinct lesion due to the influence of female sex hormones. To explicate this issue, a study was undertaken to determine whether a significant correlation exists between pregnancy tumor and pyogenic granuloma.

Materials and Methods: 18 cases that were clinically diagnosed as pregnancy tumors and 20 cases of pyogenic granulomas of non-pregnant individuals were selected as study group and control group respectively. All the clinical presentation and routine H & E stained histopathology of both the groups were studied.

Results: The results indicated that there is a progressive increase in the incidence of pregnancy tumor as the gestation period proceeds and also there is significant similarity between pregnancy tumor and pyogenic granuloma of young non-pregnant females and significant difference between pregnancy tumor and pyogenic granuloma of males and elderly non-pregnant females.

Conclusion: The study supports the concept that pregnancy tumor should be separated from pyogenic granuloma and should be considered as a distinct lesion. It also suggests the role of female hormones in the development of the lesion.

Keywords: pregnancy tumor, pyogenic granuloma.

INTRODUCTION

Pregnancy Tumour is a clinical term that is used to describe a reddish swelling, usually an epulis in pregnant women. [1] It is often nodular and / or ulcerated, that bleeds easily, usually presents as a single localized lesion but may be multiple. Pregnancy tumour is commonly seen in the oral cavity but may be found on the skin also. [2,3] When it occurs in the oral cavity; the gingiva is the common site of occurrence and is rarely found in other sites. [2,4,5] Recurrence of

the lesion after excision is common during pregnancy and also most of the times partial or complete regression of the lesion is common after childbirth. [2,6]

There is controversy regarding the usage of the term ‘Pregnancy Tumor’. Many authors consider it as a form of pyogenic granuloma because of its similar clinical and histopathological presentation. However some authors believe that this lesion is unique because of influence of female sex hormones in the pathogenesis and also it’s unique biological behaviour.

[1] The present study was undertaken to investigate the features of the clinically diagnosed pregnancy tumors and correlate its clinical presentation and histopathological features with that of pyogenic granulomas in non-pregnant individuals.

MATERIALS AND METHODS

18 cases that were clinically diagnosed as pregnancy tumor were selected from the records of Govt. Dental College, Srinagar. 20 cases of pyogenic granuloma with complete clinical details were also selected as the control group. All

the clinical data were collected and 5 μ m thin sections were obtained from the paraffin blocks of these cases, which were stained with routine H & E, stains and histopathologically examined.

RESULTS

All the 18 cases of pregnancy tumours were located on the gingiva. Among these, 5 cases had the lesion occurring in the maxillary anterior region, 5 cases in the maxillary posterior region, 5 cases in the mandibular posterior region and 3 cases had the lesion occurring in the mandibular anterior region (Table-II).

Table-I: Control Group

Sl.No	Age/ Sex	Site	Size	Ulcer	Vascularity	Inflammatory cells
1	20/F	Tongue	1-3 cm	+	Moderate	Moderate
2	28/F	Gingiva: Upper Posterior	1-3 cm	+	Moderate	Moderate
3	26/F	Gingiva: Lower Posterior	1-3 cm	-	High	Moderate
4	25/F	Gingiva: Upper Posterior	1-3 cm	+	Moderate	Moderate
5	22/F	Gingiva: Lower Anterior	1-3 cm	-	Moderate	Moderate-High
6	30/F	Gingiva: Upper Posterior	< 1 cm	+	High	Moderate
7	24/F	Gingiva: Upper Anterior	< 1 cm	+	Moderate	High
8	32/F	Gingiva: Upper Posterior	< 1 cm	+	Moderate-High	High
9	31/F	Buccal Mucosa	< 1 cm	-	Moderate-High	Minimum
10	26/F	Gingiva: Lower Anterior	1-3 cm	+	Moderate	Moderate
11	32/M	Gingiva: Lower Posterior	1-3 cm	-	High	Moderate
12	33/F	Gingiva: Upper Posterior	< 1 cm	+	Moderate-High	High
13	34/F	Gingiva: Lower Anterior	< 1 cm	+	Moderate	High
14	35/M	Gingiva: Lower Anterior	< 1 cm	-	Moderate-High	Minimum
15	65/F	Buccal Mucosa	1-3 cm	+	Moderate	High
16	65/F	Gingiva: Lower Anterior	< 1 cm	-	Moderate	High
17	60/M	Palate	1-3 cm	-	Moderate	High
18	55/M	Tongue	1-3 cm	-	Moderate	High
19	58/M	Gingiva: Lower Posterior	1-3 cm	+	Moderate-High	High
20	42/M	Gingiva: Upper Anterior	1-3 cm	+	High	Moderate-High

Table-II: Study Group

Sl.No	Age	Site - Gingiva	Size	Month of gestation	Ulcer	Vascularity	Inflammatory cells
1	21	Upper Anterior	1-3 cm	9	+	High	Moderate
2	33	Upper Posterior	1-3 cm	9	+	High	Moderate-High
3	28	Lower Posterior	1-3 cm	6	+	Moderate	Minimum-Moderate
4	28	Lower Posterior	1-3 cm	8	-	High	Moderate
5	25	Lower Posterior	1-3 cm	9	-	Moderate-High	Minimum-Moderate
6	30	Lower Posterior	1-3 cm	5	+	High	Moderate
7	33	Lower Anterior	1-3 cm	8	-	Moderate-High	Moderate
8	32	Upper Anterior	1-3 cm	9	-	Moderate-High	Moderate
9	26	Upper Posterior	1-3 cm	9	-	High	Minimum
10	28	Upper Posterior	1-3 cm	9	+	High	Moderate-High
11	35	Upper Posterior	1-3 cm	9	-	High	Moderate
12	33	Upper Anterior	1-3 cm	5	-	Moderate-High	Minimum
13	28	Upper Posterior	< 1 cm	6	-	Moderate	Minimum
14	28	Lower Posterior	< 1 cm	9	+	High	Minimum-Moderate
15	26	Upper Anterior	< 1 cm	7	+	High	Moderate
16	23	Lower Anterior	< 1 cm	9	-	Moderate-High	Minimum
17	23	Lower Anterior	< 1 cm	5	+	Moderate-High	Moderate
18	25	Upper Anterior	< 1 cm	6	-	Moderate-High	Moderate

Out of 20 cases in the control group (Table- I), 15 cases were noted on the gingiva, 2 each on the tongue and

buccal mucosa and 1 on the palate. In the gingival lesions, 2 were present in the maxillary anterior region, 5 each from the

mandibular anterior and maxillary posterior and 3 from mandibular posterior region.

Mean age of the patients having pregnancy tumour (Table-II) at the time of excision was 28 years with the age ranging between 21-35 years, whereas in the pyogenic granuloma non- pregnant cases (Table- I), the mean age was 37 years with the age ranging from 20-65 years. The trimester of pregnancy in which the lesions occurred was also noted. 12 cases were in their 3rd trimester and 6 cases were in their 2nd trimester of pregnancy (Table-II). In the control group (pyogenic granuloma non- pregnant cases), 14 patients were females and 6 were males (Table- I).

Size of the lesion was less than 3 cm in all the cases, out of which 6 pregnancy tumors (Table-II) and 8 pyogenic granulomas i.e., control group (Table- I) measured less than 1 cm in size. It is interesting to note that bleeding was positive in 10 cases of pregnancy tumors whereas only 4 cases of pyogenic granulomas had complained of bleeding. Tenderness was positive sign in 12 cases of pregnancy tumors and only 4 cases of pyogenic granulomas were tender.

Histopathological examination of pregnancy tumors and pyogenic granulomas revealed that both had similar finding. However, only 8 pregnancy tumors (Table-II) and 12 pyogenic granulomas (Table- I) showed surface ulceration. Endothelial lined capillary proliferation was high in 9 cases, moderate to high in 7 cases and moderate in 2 cases of pregnancy tumors (Table-II), whereas in the non-pregnant pyogenic granuloma (control) group, high vascularity was seen in 4 cases, moderate to high in 5 cases and moderate in remaining 11 cases (Table- I). However inflammatory cells were found in both study and control groups. Acute inflammatory cells were located mainly at the ulcerated areas and chronic inflammatory cells in non-ulcerated and deeper areas. However, inflammatory cells were less in pregnancy tumors compared

to that of pyogenic granulomas in non-ulcerated cases and deep areas of ulcerated cases.

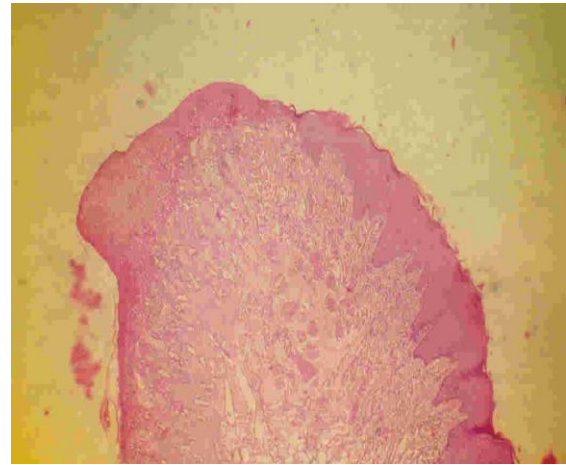


Figure-1: Histopathology of pregnancy tumor showing ulcerated surface and numerous vascular proliferation. [H & E, original magnification X 40].

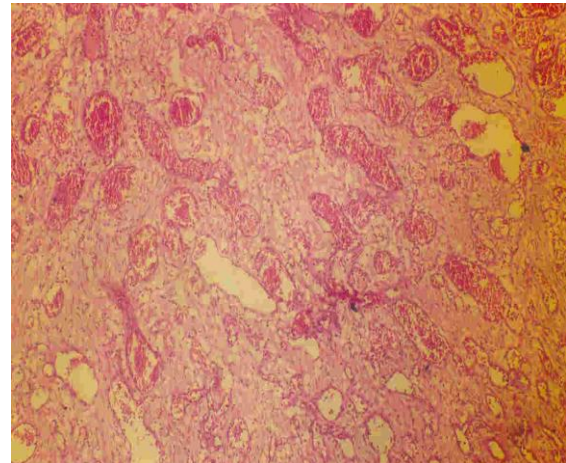


Figure-2: Histopathology of pregnancy tumor showing high amount of neovascularity and minimal inflammatory cells. [H & E, original magnification X 100].

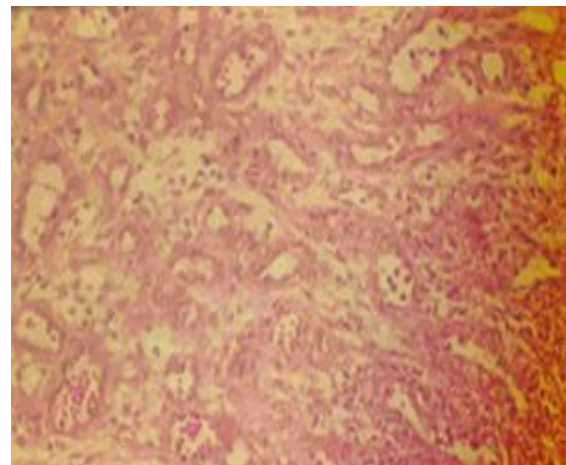


Figure-3: Histopathology of pregnancy tumor showing moderate vascularity and few inflammatory cells. [H & E, original magnification X 400].

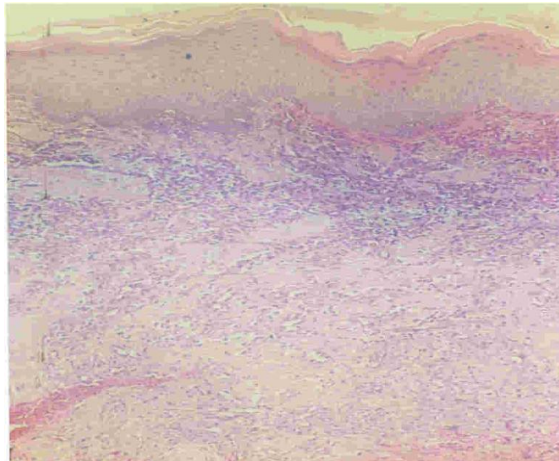


Figure-4: Histopathology of pyogenic granuloma showing non-ulcerated epithelium and high amount of inflammatory component and moderate vascularity. [H & E, original magnification X 40].

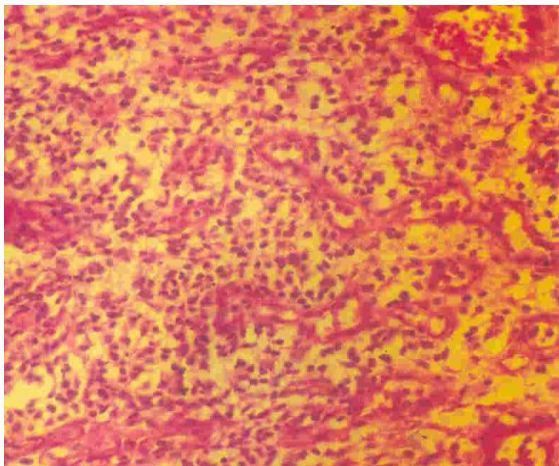


Figure-5: Histopathology of pyogenic granuloma showing high amount of inflammatory component and high vascularity. [H & E, original magnification X 400].

DISCUSSION

Localized gingival hyperplasia accompanying gestation has been termed as pregnancy tumor and it usually regresses after childbirth. [7] The most common intraoral site is gingiva, but can occur on the lip, buccal mucosa, palate and tongue. Extraoral sites include skin of upper and lower extremities, head, and face, mucous membrane of nose, eyelids and genitalia. [8]

Many authors suggest that some form of chronic low-grade irritation as the inciting factor, which is enhanced by female sex hormones, is responsible for pregnancy tumor. [6,9] It is considered that estrogen is responsible for the induction of neovascularity in pregnancy tumor. It has been observed clinically that alteration of

estrogen and progesterone concentration have occasionally induced a hyperemic gingivitis in girls at puberty [10] and women taking contraceptives. [9,11] The gingiva may be subjected to even higher level of these hormones. [13] There is also an increased risk that the circulating hormones will help promote the growth of certain bacteria and plaque, which causes inflammation. During pregnancy, the concentrations of estrogen and progesterone rise steadily until childbirth, which suggests that the incidence of pregnancy tumor should also increase as the level of these hormones increases. [14] Likewise, our study showed that 12 out of 18 cases (i.e., 66.66%) had the lesion in their 3rd trimester of which 9 cases (i.e., 75%) were in their 9th month of gestation.

Some authors also suggest the role of placental hormones as an added impact in the pathogenesis of pregnancy tumors. The three major hormones produced by the placenta are progesterone, estrogen and human chorionic gonadotropin. [12]

Histopathologically, pregnancy tumor shows proliferation of capillaries with prominent endothelial cells embedded in edematous gelatinous stroma in a characteristic lobular configuration. Epithelium is commonly eroded. A dense infiltrate and granulation tissue with PMN's may be present. [2] Pyogenic granuloma and pregnancy tumor had similar histological findings. However, our study showed more vascular proliferation and less inflammatory cells as compared to that of pyogenic granuloma of non-pregnant individuals. A similar histopathological picture was also seen in non-pregnant young females suggesting a similar pathologic process as pregnancy tumor, which supports the role of hormones.

Treatment protocol for pregnancy tumor as proposed by some investigators suggest that the lesion should not be excised during pregnancy unless it causes functional and esthetic problems, as it resolves after childbirth; however, the

lesions that do not resolve after parturition should be excised. [1]

CONCLUSION

The present study supports the concept that pregnancy tumor should be considered as a distinct lesion from other pyogenic granulomas. However, pyogenic granuloma of young females that are similar to pregnancy tumors, supports the hypothesis that the lesion being formed due to the influence of female hormones in the presence of irritation (i.e., pregnancy tumor and pyogenic granuloma of non-pregnant young females) are different from pyogenic granulomas only caused by local irritation and trauma without the role of female hormones. A study comprising of a larger sample of pyogenic granuloma may help in this context.

REFERENCES

1. Daley TD, Nartey NO, Wysocki GP. Pregnancy tumor: an analysis. *ORAL SURG ORAL MED ORAL PATHOL.* 1991 Aug; 72(2): 196-9.
2. Shafer WG, Hine MK, Levy BM. Bacterial, viral, mycotic diseases. In: Saunders WB. *A textbook of oral pathology.* 4th ed. Philadelphia: 1983; 361.
3. Macleod RI, Soames JV. Epulides: a clinicopathological study of a series of 200 consecutive lesions. *Br Dent J* 1987; 163: 51-3.
4. Crich WA. Pregnancy tumor: a report of a case. *J Can Dent Assoc* 1950; 16: 304-5.
5. Eversole LR, Rovin S. Reactive lesions of the gingiva. *J Oral Pathol.* 1972; 1: 30-8
6. Tervahartiala B, Ainamo J. The development during pregnancy of pyogenic granulomas superimposed upon a congenital haemangioma: a case report. *J Periodontol* 1989; 6: 358-61.
7. Wang PH, Chao HT, Lee WL, Yuan CC, Ng HT. Severe bleeding from a pregnancy tumor: a case report. *J Reprod Med* 1997 Jun; 42(6): 359-62.
8. Hatziotis J, Banayi E. Pregnancy tumor of the tongue. *J Am Dent Assoc* 1963; 67: 443-4.
9. Pearlman BA. An oral contraceptive drug and gingival enlargement: the relationship between local and systemic factors. *J Clin Periodontol* 1974; 1: 47-51.
10. Ziskin DE. Effects of certain hormones on gingival and oral mucous membranes. *J Am Dent Assoc* 1938; 25:422-6.
11. Mussalli NG, Rosamund MH, Johnson NW. Oral pyogenic granuloma as a complication of pregnancy and the use of hormonal contraceptives. *Int J Gynaecol Obstet* 1976; 14: 187-91.
12. Simpson ER, MacDonald PC. Endocrine physiology of the placenta. *Ann Rev Physiol* 1981; 43: 163-88.
13. Evans JJ, Wilkinson AR, Aickin DR. Salivary estriol concentrations during pregnancies, and a comparison with the plasma estriol. *Clin Chem* 1984; 30: 120-1.
14. Fox SI. In: Brown Wm C. *Human physiology*, 2nd ed. Dubuque, Iowa; 1987.

How to cite this article: Sasan NS, Kaul R, Jain P et al. A research analysis on pregnancy tumor-correlation with pyogenic granuloma. *Int J Health Sci Res.* 2016; 6(2):208-212.
