

Original Research Article

Ultrasonographic Assessment of Agenesis of Palmaris Longus Muscle in South Indian Population

Najma Mobin

Assistant Professor, JSS University, Medical Faculty, JSS Medical College, Department of Anatomy, S S Nagara, Mysore, Karnataka State, India.

Received: 15/01/2016

Revised: 23/01/2016

Accepted: 25/01/2016

ABSTRACT

The Palmaris longus muscle is now being used widely as the most suitable autograft material for various reconstructive surgeries. Keeping this in view the present work was undertaken. A cross sectional descriptive study was done by Ultrasonographic method wherein 240 medical and paramedical students (133 females and 107 males), aged between 18-21 years, from various parts of south India were clinically tested for the presence or absence of the muscle using 10-12MHz US linear probe. It was noted that there was absence of the muscle unilaterally mostly left sided (non dominant hand) and bilaterally was predominantly seen in females compared to the males. It was observed that the total percentage of agenesis out of 240 subjects was 16.66%. In females right sided agenesis was 6.0 %, left sided agenesis was 12.0% and bilaterally it was 3.75%. Total agenesis in females was 18.0%. In males right sided agenesis was 5.6%, left sided agenesis was 9.34% and bilaterally it was 1.86%. Total agenesis in males was found to be 14.95%. Many studies on agenesis of Palmaris longus muscle have been done by dissection and clinical methods, but detection of the presence or absence of muscle through ultrasound is very rare to find in the literature. Ultrasound is a highly suitable and confirmed method of detecting the absence of the muscle for pre-operative planning of reconstructive surgeries and is less expensive than MRI. Any associated muscle anomalies leading to nerve compression at the wrist can also be detected simultaneously. This will also heighten awareness among the radiologists.

Key words: Agenesis of Palmaris longus; Palmaris longus muscle; Tendon grafting.

INTRODUCTION

The Palmaris longus muscle is a small fusiform muscle of the forearm present in the superficial compartment. It takes origin from the medial epicondyle of the humerus and gets inserted into the apex of the palmar aponeurosis; it is supplied by the median nerve. It is a weak flexor of the forearm, its main function being anchoring of the skin and fascia of the hand ^[1] It is the most variable muscle in the body, its absence was reported as early as 1559, it was absent in 7.7% of cases, absent on the right side in 4.5% and absent on the left side in 5.2% out of 800 cases, it was absent more often in females and on the

left side in both sexes ^[2] In 1999, it was found that the Palmaris longus tendon was subjected to a wide range of variations, hence, the identification and determination of its length and thickness was of importance for the pre-operative planning of ligament reconstructive surgery. Thirty healthy volunteers between the age group of 6 - 50 years were examined using high resolution 10-12MHz US probes. The length and thickness of the tendon was determined. Ultrasound was highly suitable for identification of Palmaris longus tendon and aids the pre-operative planning of ligament reconstruction ^[3] In 2000, four cases of the median nerve

compression due to reversed Palmaris longus muscle were identified. MRI was done which showed an anomalous muscle in each case that had been missed initially. All the four patients were free of pain after simple excision of the anomalous muscle. Awareness of muscle anomalies at the wrist on MRI is essential in evaluating patients with nerve compression at the wrist. This will also heighten awareness among the radiologists. [4]

MATERIALS AND METHODS

In the present study a total of 240 medical and paramedical students

belonging to various parts of South India, 133 females and 107 males between the ages of 18-21 years were assessed by using high resolution 10-12MHz US probes. All the subjects were right handed. Informed consent from the students was taken along with the approval from the institution to conduct the study. Information regarding the gender, age, region to which they belong and handedness was collected prior to the study. Exclusion criteria included hand and wrist deformities, history of previous hand and wrist injuries or surgeries.

OBSERVATIONS AND RESULTS

Table 1: Frequency of agenesis of Palmaris longus by Ultrasound method

Gender	Right side		Left side		Bilateral absence	Total agenesis
	Present	Absent	Present	Absent		
Females (133)	120 (90.22%)	8 (6.0%)	112 (84.2%)	16 (12.0%)	5 (3.75%)	18.0%
Males (107)	99 (92.5%)	6 (5.6%)	95 (88.7%)	10 (9.34%)	2 (1.86%)	14.95%

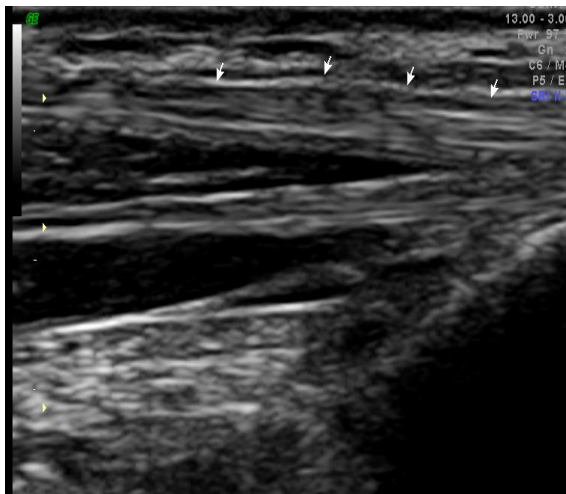


Figure 1: Arrows indicating the presence of Palmaris longus muscle, using ultrasound method (10-12 MHz linear probe).

It was observed that the total percentage of agenesis out of 240 subjects was 16.66%. In females right sided agenesis was 6.0%, left sided agenesis was 12.0% and bilaterally it was 3.75%. Total agenesis in females was 18.0%. In males right sided agenesis was 5.6%, left sided agenesis was 9.34% and bilaterally it was 1.86%. Total agenesis in males was found to be 14.95%. All the subjects tested were right handed. It was noted that there was absence unilaterally mostly left sided (non dominant hand) and bilaterally was

predominantly seen in females compared to the males. The observations made following Ultrasonographic tests suggest that the Palmaris longus muscle present in the dominant right hand which is involved in more motor activity compared to the left, is less likely to get degenerated than the left side which is the non-dominant hand due to disuse. Overall agenesis of Palmaris longus was found to be comparatively high in South Indian population, more so in females compared to the males, and left sided agenesis was found to be more in females compared to the bilateral agenesis.

DISCUSSION

Though the Palmaris longus muscle has no functional importance, because of the very well developed flexors taking over its function, it is the best graft material that can be used for various reconstructive surgeries. It is used in emergency reparative surgeries like opponensplasty procedures, in median and ulnar nerve palsies, hand and wrist deformities, ten do Achilles reconstruction, [5] reconstruction of

maxillo-facial surgeries, [6] in leprosy - correction of hand and finger deformities, [7] repair of ruptured tendons in rheumatoid arthritis, [8] Camitz Palmaris longus abductorplasty for severe thenar atrophy secondary to carpal tunnel syndrome, [9] lip augmentation procedures [10] and correction of ptosis in children. [11] In 1975, it was revealed that there was an increased incidence of absence of the Palmaris longus muscle in patients suffering from manic-depressive psychosis and endogenous depression, it was stated that the defect was genetically determined, inherited in a monofactorial way, and determined by an autosomal gene of a dominant character with incomplete penetrance. The absence of the Palmaris longus muscle was a dominant trait, its presence a recessive trait. [12] The Palmaris longus has a highly variable prevalence in different ethnic populations. It was studied that the African American population had a statistically significantly lower rate of absent Palmaris longus (4.5%) and Asians (2.9%) compared to the Caucasians having unilateral absence of 16% and bilateral absence of 9%, with males being more affected. [13] A prospective study done in Andhra population showed that the overall agenesis in both sexes was 264 out of 942 (28.0%), out of which 40.2% was seen in females and 14.7% in males with the ratio of 3:1. Unilateral absence was seen in 70.5% and bilateral absence was seen in 29.5%. Left side agenesis was seen in 51.6% and right side in 48.4% subjects. [14] In another study done in eastern Nepal, the overall incidence of agenesis was 11.8% with bilateral absence of 3.5% and unilateral absence of 8.2%. [15]

CONCLUSION

From this study we can conclude that the incidence of agenesis by Ultrasonography is quite high in south Indian population compared to the other regions of India. The Palmaris longus muscle which was once thought to be a vestigial and degenerating structure can

now be used as an autograft material for various reconstructive surgeries, without producing any residual defects in the donor. It is imperative for the surgeons to know the local incidence of agenesis before planning for tendon grafting, thus this study gives an accurate idea to the surgeons working in this region their likelihood of finding the tendon for grafting, by utilizing the Ultrasonography other associated anomalies leading to nerve compression disorders can also be detected simultaneously. Ultrasonography is the most suitable and reliable method to identify the Palmaris longus muscle compared to the cadaveric and clinical studies.

REFERENCES

1. William P L, Bannister L H, Martin, Berry. Gray's Anatomy. 39th edition, London: Elsevier Churchill Livingstone publisher, 2005 pp 876-877.
2. Bergmann R, Thompson S A, Afifi A K, Saadeh F A. A compendium of human anatomic variation. Baltimore, Munich, Urban and Schwarzenberg, 1988 pp 12-13.
3. Grechenig W, Clement H, Mayr J, Grechenig M. Ultrasound identification and size determination of the Palmaris longus tendon. Biomed Tech (Berl), 1999 Nov; 44(11):319-323.
4. Schuurman A H, Van G A P. Reversed Palmaris longus muscle on MRI: Report of four cases. Eur Radiol 2000; 10(8):1242-1244.
5. Isenberg J S, Fusi S. Immediate tendo Achilles reconstruction with composite Palmaris longus grafts. Ann Plastic Surgery, 1995; 34 (2):209-211.
6. Katou F, Shirai N, Kamakura S, Ohki H, Motegi K. Full thickness reconstruction of cheek defect involving oral commissure with forearm tendino-cutaneous flap. British Journal of Oral and Maxillofacial Surgery, 1996; 34 (1):26-27.
7. Malaviya G N. Palmaris longus-A muscle with multiple uses in leprosy

- affected hands. *Indian Journal of Leprosy*, 2003; 75(4):327-334.
8. Wehbe M A. Tendon graft donor sites. *Journal of Hand Surgery (American)*, 1992;17(6):11302.
 9. Terrono A L, Rose J H, Mulroy J, Millender L H. Camitz Palmaris longus abductorplasty for severe thenar atrophy secondary to carpal tunnel syndrome. *Journal of Hand Surgery (American)*, 1993; 18(2):204-206.
 10. Barry A D. Lip Augmentation using the Palmaris longus tendon. *Journal of Plastic and Reconstructive Surgery*, 1995; 95 (6):1108-1110.
 11. Dennis S C L, Joan S K N G, George P M C, Randa T H L I. Autogenous Palmaris longus tendon as frontalis suspension material for Ptosis correction in children. *American Journal of Ophthalmology*, 1998; 126:109-115.
 12. Michel F B, Shaw E F. Anatomical variations of the Palmaris longus causing carpal tunnel syndrome. *Journal of Plastic and reconstructive surgery*, 1978; 62:798-800.
 13. Ali M S, Mirna P, Cameron S F. The variation in the absence of the Palmaris longus in a Multiethnic population of the United States: An epidemiological study. *International Journal of Plastic surgery*, 2012; 10:1155.
 14. Devi S K, Sharmila B P, Susan J P. Incidence of agenesis of Palmaris longus in the Andra population of India. *Indian Journal of Plastic surgery*, 2011; 44(1):134-138.
 15. Ranjib J, Yogendra G, Rimu M. Absence of Palmaris longus: A study in Eastern Nepal. *American Journal of Public Health Research*, 2015; 3 (5A):88-90.

How to cite this article: Mobin N. Ultrasonographic assessment of agenesis of palmaris longus muscle in South Indian population. *Int J Health Sci Res*. 2016; 6(2):138-141.
