

Original Research Article

Corneal Higher Order Aberrations after Aspheric LASIK Treatment

Alpa Patel Nisarta¹, Dipan Desai², Kaushik Solanki³

¹DNB (Ophthalmology), Consultant Ophthalmologist, Aaditya Eye & Children Hospital, Vadodara, Gujarat.

²Director, Diva Eye Institute, Vadodara, Gujarat.

³Consultant Ophthalmologist, Diva Eye Institute, Vadodara, Gujarat.

Corresponding Author: Alpa Patel Nisarta

Received: 10/12/2015

Revised: 13/01/2016

Accepted: 20/01/2016

ABSTRACT

Aim: To Study the changes in corneal higher order aberrations after Aspheric LASIK treatment

Method: A prospective observational study of 100 eyes of 51 patients, with manifest refraction ranges from -1 to -10 D sphere and -0.5 to -4 Dcyl, underwent aspheric LASIK treatment. In all cases pre- and postoperative BSCVA, manifest refraction, topography, pachymetry and corneal wave front analysis were performed. Corneal higher order aberrations were measured in 6, 7 and 8 mm diameter.

Results: 2 months after LASIK surgery, mean manifest refraction spherical equivalent (MRSE) for all eyes was -0.0186 ± 0.3743 . At the end of 2 months, UCVA $\geq 20/20$ was achieved in 80%, $\geq 20/25$ in 93% and $>20/30$ in 100% of eyes. No eye had lost two or more lines after surgery. Mean increase in total corneal higher order aberrations was 0.3446 ± 0.2175 ($P < 0.0001$), increase in Corneal Spherical Aberration was 0.3284 ± 0.1390 , which were statistically significant ($P < 0.0001$) (in 6mm optical diameter). The Change in Corneal RMS (HOA) value was $0.3446 \pm 0.2175 \mu\text{m}$ at 6, $0.549 \pm 0.3143 \mu\text{m}$ for 7 and $0.8212 \pm 0.610 \mu\text{m}$ for 8 mm analyzing diameter.

Conclusion: There was a mild induction of corneal higher order aberrations after Aspheric LASIK. But this increase was less than those induced by Conventional LASIK treatment. Also there is a change in Aberration magnitude increased with the increase in analysis diameter. This occurs due to local curvature changes from Optical Zone to Transition Zone and from Transition Zone to non treated cornea. Aspheric LASIK treatment is an excellent treatment giving a good quality of vision in compare to standard LASIK treatment.

Keywords: Corneal higher order aberrations, Aspheric LASIK, Optical zone, Transition zone.

INTRODUCTION

A normal cornea has a curve which is steeper in the center and flatter peripherally. This is called a prolate shape. In myopia, cornea is flattened centrally after the laser treatment and becomes oblate. The oblate cornea has increased higher order spherical aberrations and produces symptoms like decreased contrast sensitivity, ghost images, blurring, etc and though the patient can read 20/20, the quality of vision is typically unsatisfactory. Standard LASIK and the

tissue saving algorithm are known to cause spherical aberration. This leads to a qualitative loss of vision with increased glare and haloes and reduced contrast sensitivity in low light conditions. The cause has been identified as the induced change in corneal asphericity. The shape of the cornea changes from a prolate asphere to an oblate asphere. To deal with this, a newer algorithm has been designed. This new treatment modality is referred to as Aspheric LASIK. ⁽¹⁾

Aspheric treatment has a unique algorithm that treats cornea in such a way, that prolate shape is maintained and introduction of spherical aberrations is minimized. This ablation algorithm reduces the abrupt dioptric change and sudden curvature changes in the corneal surface, and thus cornea is smoothed into an aspheric flattening more or less like in the normal cornea. ⁽²⁾ Although LASIK may result in good objective outcome measured by correction of the spherocylindrical refractive error, some patients complained of a decrease in visual performance with dissatisfaction with postoperative vision. This quality of vision is mostly affected by higher order aberrations. ⁽³⁾ The analysis of the total aberrations of the eye provides the most direct and complete measurement of retinal image quality, and therefore can be directly related to visual performance.

S. Marcos et al ⁽⁴⁾ showed high correlations between corneal aberrations and visual performance.

Some comparative studies stated that the amount of HOA induction is more with Conventional LASIK treatment than with Aspheric LASIK treatment, which affects patient's quality of vision. The purpose of this study was to evaluate the changes in corneal higher order aberration after Aspheric LASIK treatment using Schwind Laser platform.

MATERIALS AND METHODS

A prospective observational study of 100 eyes of 51 patients, (2 patients had unilateral refractive error) with refractive error ranging from -1Dsph to -10Dsph with -0.50D to -4.00D of astigmatism, who underwent Aspheric LASIK treatment, was performed. No patient was lost to follow up.

Inclusion criteria:

1. Age \geq 20 yrs
2. Refractive error stable for last 1 year

3. Refractive error ranging -1.0 Dsph to -10 Dsph and -0.50 D to -4.0D astigmatism
4. Discontinued soft contact lenses for at least a week (for soft contact lens) or 2 months (for gas permeable contact lenses) prior to preoperative examination.

Exclusion criteria:

1. Calculated postoperative corneal bed thickness less than 265 μ m after ablation
2. Preoperative central corneal thickness of less than 475 μ m
3. Prior ophthalmic surgery
4. Abnormal corneal topography
5. Pregnancy
6. Ophthalmic disease/pathology/corneal opacity.

Preoperative evaluation included the measurement of distance uncorrected visual acuity (UCVA), (Snellen chart), best spectacle-corrected visual acuity (BSCVA), Manifest refraction, evaluation of anterior segment, tear film break up time, corneal topography (Keratron Scout), ultrasound pachymetry, (Pacsan 300AP, Sonomed Inc) dilated fundus examination (Indirect ophthalmoscopy using +20D lens). The same examinations, with the exception of dilated fundus examination, were performed at 1st week, 4th weeks, 8th weeks postoperatively. The quality of vision was assessed using a questionnaire that was designed for the specific needs of this study. Patients were asked to rate the presence or absence of each visual complaint at baseline before the Aspheric LASIK treatment and at 2 months postoperatively.

All treatments were simulated and the final data was prepared using the Schwind ORK CAM Software. Schwind ORK cam software is a treatment planning software that allows the surgeon to modify various parameters, including optical zone, transition zone, laser energy and treatment profile, amount of corneal irregularity. All ablations were done by using aspheric ablation profile and calculated using the

ORK CAM software. Aspheric ablations profiles are not based on the Munnerlyn proposed profiles and go beyond that by adding some aspheric characteristics to balance the induction of spherical aberration. Excimer laser system ablates tissue by using 0.8 mm flying spot laser Gaussian beam profile.

In each eye LASIK treatment was performed using Aspheric ablation profile. Surgery was performed under topical anesthesia. The suction ring is applied centering the visual axis (center of the pupil) and the foot pedal is pressed to allow vacuum to build up and fix the globe. Intra-operative tonometry is performed with Barraquer's tonometer after putting a suction ring and increasing the pressure. The applanated area should be within the mire inscribed on it. It

indicates that, the IOP is above 65mm of Hg. The Carriazo Pendular microkeratome was used to create a superiorly hinged flap. The exposed corneal stromal surface is wiped dry with a cellulose sponge. Then, the red dots were focused and patient was asked to focus on central red blinking light. The laser treatment was then started with the eye tracker on. After completion of ablation, the stromal bed is wet with a drop of BSS or ringer lactate and the flap is repositioned with a firm stroke away from the hinge. The interface is irrigated to remove all the debris. The flap is smoothed by sweeping the cornea away from the hinge with a wet cellulose sponge. The edge is aligned following the proper alignment of the preplaced marks. A drop of antibiotic, NSAID and artificial tear are instilled.

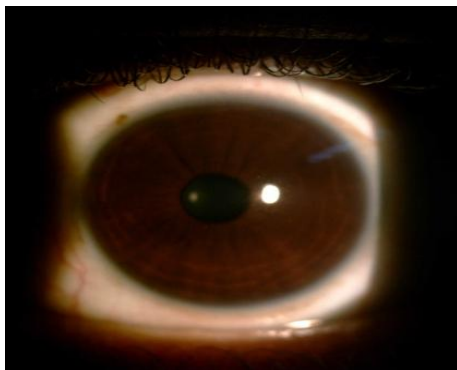


Figure: 1 (before LASIK procedure)

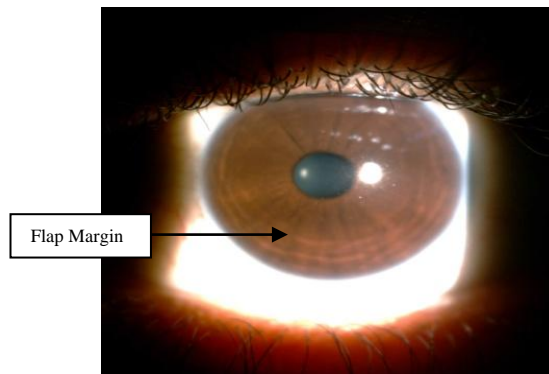


Figure: 2 (after LASIK procedure)

All the patients were prescribed topical antibiotics and steroid drops 4 times a day for 15 days and lubricating drops 4 times a day for 4 months. Routine postoperative examinations were scheduled at 1st week, 4th week and 8th week after surgery. All the patients came regularly for follow up. The UCVA, visual complaints, corneal Wave front aberrations measurement with corneal topographer were performed at each visit and any post operative complication was noted.

All data was carefully accumulated, arranged and assessed statistically to derive significant conclusion using appropriate statistical method. Refractive outcomes and change

in higher order aberrations were analyzed using Microsoft Excel software and SPSS version 17. The paired t test was used to determine statistically significant changes in higher order aberrations. P value <0.05 was considered statistically significant. Limitations of present study include short term follow up and lack of control group.

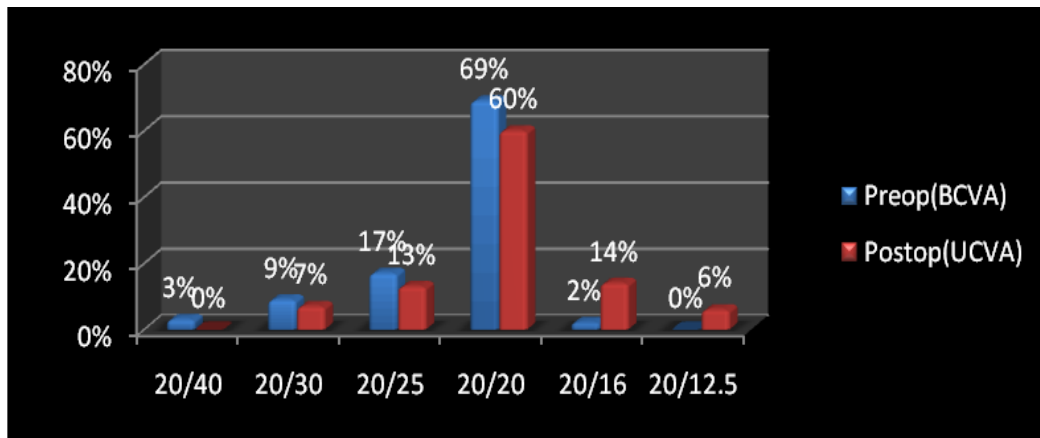
RESULTS

The mean age of the patients was 23.43 ± 2.64 years. Out of total 51 patients 35 (68.62%) were females and 16(31.37%) were males. F: M ratio was 1:0.45.

In the study, UCVA $\geq 20/20$ was achieved in 80% of eyes and UCVA $\geq 20/25$ was achieved in 93% of

eyes and >20/30 in 100% of eyes. No eye losses two or more lines after surgery. After 2 months postoperatively, mean

manifest refraction spherical equivalent (MRSE) for all eyes was -0.0186 ± 0.3743 .



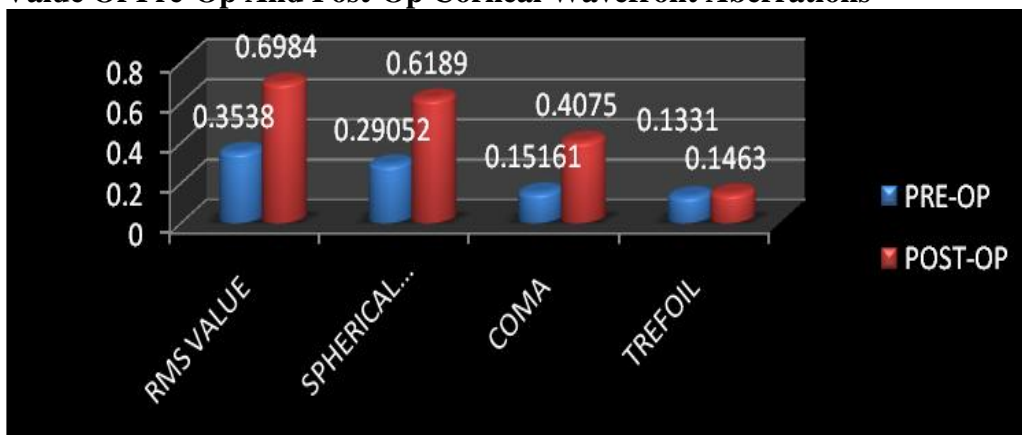
Mean Value Of Pre-Op And Post-Op Corneal Wavefront Aberrations

	RMS VALUE	SPHERICAL ABERRATIONS	COMA	TREFOIL
PRE-OP	0.3538 ± 0.0749	0.29052 ± 0.1077	0.15161 ± 0.0574	0.1331 ± 0.0712
POST-OP	0.6984 ± 0.2924	0.6189 ± 0.2468	0.4075 ± 0.3503	0.1463 ± 0.1021
P VALUE	<0.0001	<0.0001	<0.0001	=0.1416

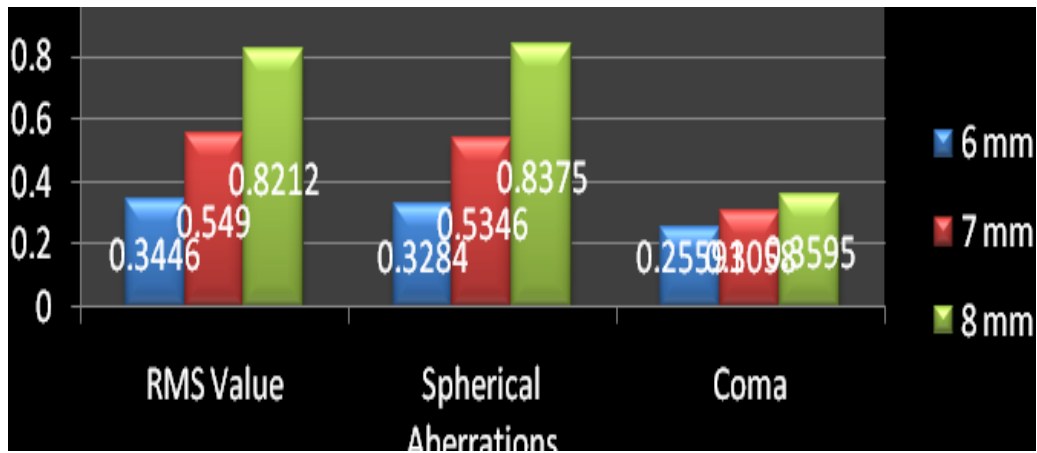
The mean preoperative and 2-month postoperative total Corneal higher order aberrations at 6-mm zone using Corneal Wavefront Analyzer were increased in 96(96%) eyes, decreased in 3(3%) eye and there was no change in 1(1%) eye. Mean root square (RMS) value for the total corneal higher order aberrations changed from $0.3538 \pm 0.0749 \mu\text{m}$ preoperatively to $0.6984 \pm 0.2924 \mu\text{m}$ 2 months postoperatively. The mean increase in

RMS value for corneal higher order aberrations was $0.3446 \pm 0.2175 \mu\text{m}$, which was statistically significant ($p < 0.0001$). Preoperatively, Mean Spherical aberration was 0.29052 ± 0.1077 . Postoperatively, the values were 0.6189 ± 0.2468 ($P < 0.0001$). Preoperatively, Mean Coma was 0.15161 ± 0.0574 . Postoperatively, the values were 0.4075 ± 0.3503 ($P < 0.0001$). Preoperatively, Mean Trefoil was 0.1331 ± 0.0712 . Postoperatively, the values were 0.1463 ± 0.1021 . ($P < 0.0001$)

Mean Value Of Pre-Op And Post-Op Corneal Wavefront Aberrations



Mean Difference In Rms Value, Spherical Aberrations And Coma Pre-Op And Post-Op In 6 Mm, 7 Mm And 8 Mm Analyzing Zone



Change In Corneal Rms Hoa was, $0.3446 \pm 0.2175 \mu\text{m}$ at 6 mm analyzing diameter, $0.549 \pm 0.3143 \mu\text{m}$ for 7 mm and $0.8212 \pm 0.610 \mu\text{m}$ for 8 mm analyzing diameter. The mean change in corneal spherical aberration was $0.3284 \pm 0.1390 \mu\text{m}$ at 6 mm analyzing diameter, $0.5346 \pm 0.3129 \mu\text{m}$ for 7 mm diameter and $0.8375 \pm 0.576 \mu\text{m}$ for 8 mm. For corneal Coma the change was $0.2559 \pm 0.2928 \mu\text{m}$ at 6 mm analyzing diameter, $0.3058 \pm 0.3190 \mu\text{m}$ for 7 mm and $0.3595 \pm 0.361 \mu\text{m}$ for 8 mm analyzing diameter.

DISCUSSION

Wave front, aspheric and conventional LASIK for the treatment of myopia and myopic astigmatism is safe and effective. Recent advances in excimer laser technology, such as the use of aspheric ablation profiles, incorporation of higher order aberration treatment, and eye trackers, have presumably led to better refractive outcomes and reduced higher order aberration induction postoperatively. (5)

100 eyes with simple myopia or myopic astigmatism were analyzed at 2 month post operatively. The study found that Aspheric LASIK treatments are safe and very predictable because UCVA $\geq 20/20$ was achieved in 80% of eyes and UCVA $\geq 20/25$ was achieved in 93% of eyes and $>20/30$ in 100% of eyes. No eye losses two or more lines after surgery.

According to Marcos et al, (6) in general, before myopic surgery, both components (Corneal aberrations and internal aberrations) contributed to the whole aberration with comparable amounts of aberrations-in some cases even balancing each other. Although the relative contribution of the internal optics is expected to be much lower after refractive surgery, interactions between corneal and internal optics may still play some role in determining the surgical outcome. A high degree of balance between corneal and internal aberrations in normal young eyes has been reported in previous studies. (7)

In present study, for 6 mm analysis diameter, there was an induction of Corneal Higher Order Aberrations (RMS Value) by 0.3446 ± 0.2175 , which was statistically significant ($P < 0.0001$). Regarding Spherical aberration, induction was 0.3284 ± 0.1390 , which was statistically significant ($P < 0.0001$). Mean increase in Corneal Coma was 0.2559 ± 0.2928 , which was also statistically significant ($P < 0.0001$). Mean increase in Corneal Trefoil was $0.0132 \pm 0.0309 \mu\text{m}$, which was not statistically significant ($P = 0.1416$).

On comparing present study with others, change in RMS Value for corneal higher order aberrations was $0.14 \pm 0.12 \mu\text{m}$ ($P < 0.0001$) in Maria Clara et al (8) study, which was statistically significant. Lee et al (9) found that after laser refractive surgery, anterior corneal aberration and

ocular aberration increased equally and showed statistically significant correlations.

Possible explanations for more increase in corneal higher order aberrations are

- 1) The refractive surgery induces changes only at the corneal level, whereas other internal structures are not expected to change.
- 2) The corneal front surface in the normal eye contributes approximately to half the total aberrations of the eye.
- 3) Creation of flap with Microkeratome.
- 4) Change in corneal biomechanics.
- 5) Reposition of flap can't be at molecular level.
- 6) Corneal epithelial remodeling after wound healing

But this increase in corneal higher order aberrations was less than those induced by conventional LASIK treatment. Corneal RMS changed from -0.16 mm to 2.04 mm, being statistically significant according Marcos, S., et al ⁽¹⁰⁾ study. Marcos et al ⁽¹⁰⁾ found that corneal aberrations increased statistically significantly after myopic LASIK surgery by a factor of 3.72 (corneal), on average. Mild induction in spherical aberrations was due to correction of myopia which always induces some spherical aberrations. The increase in spherical aberration can be partially explained by the biomechanical response, corneal epithelial remodeling, flap cut. This increase in spherical aberration was less than those induced by Conventional treatment.

Though the amount of corneal spherical aberration and asphericity are intrinsically related, the goal is always described in terms of changes in spherical aberration, because this is the factor related to the quality and sharpness of the retinal image. Furthermore, the main high order aberration effects post-op (coma and spherical aberration) are coming from decentration and «edge» effects, the strong local curvature change from Optical Zone to Transition Zone and from Transition Zone to non-treated cornea. Then it is

necessary to emphasize the use of large Optical Zones, covering the scotopic pupil size plus some tolerance for possible decentrations, and well defined smooth Transition Zones.

In present study, corneal higher order aberrations were measured at 6-mm pupil diameter. The optical zone diameter was 6.5 mm. Most spherical aberration induction occurs at the junction between the central treatment zone, transition zone and untreated zone. Some patients may have a scotopic pupil diameter greater than 6 mm; the values within a 6 mm zone may not correspond with the real-life visual function of the patient in terms of glare and halos. In order not to limit the topographic analysis to 6 mm, as this will omit the transition zone and untreated zone from the entire analysis, and it may miss the practical clinical point of the effect of changes in aberrations outside the 6 mm zone.

Therefore, in present study corneal wave front aberrations were measured in 6 mm, 7 mm and 8 mm, to include the ablation zone, transition zone and untreated zone. In present study, the change in aberration magnitude increased with the analysis diameter, because highest amount of aberrations occur at the junction of ablation zone, transition zone and untreated zone. This occurs due to the strong local curvature changes from Optical Zone to Transition zone and from Transition zone to non-treated cornea. So it is necessary to emphasize the use of large Optical Zones, covering the scotopic pupil size as with increasing analyzing zone there is more induction of HOAs.

In summary, Aspheric LASIK Treatment is a safe and effective surgery to correct refractive errors. In present study, we find that there was a mild induction of corneal higher order aberrations post operatively after Aspheric LASIK. But this increase in corneal higher order aberration was less than those induced by Conventional LASIK treatment. Also there is a change in Aberration magnitude

increased with the increase in analysis diameter. This occurs due to local curvature changes from Optical Zone to Transition Zone and from Transition Zone to non treated cornea.

CONCLUSION

Aspheric LASIK treatments give very good visual, optical, and refractive results for corrections of myopia and myopic astigmatism. Aspheric ablation profiles as demonstrated here, have therefore, the potential to replace currently used standard algorithms for corrections of non-customized myopic astigmatism.

REFERENCES

1. George Waring, Paul J. Dougherty, Arturo Chayet, - Topographically Guided LASIK for myopia using The NIDEK CXII Customized Aspheric Treatment Zone (CATZ) [American Ophthalmological Society; 105:240-248(2007)]
2. H V Nema, Nitin Nema. Diagnostic procedures in Ophthalmology. 2nd Edition. New Delhi: Jaypee Brothers Medical Publishers (P) Ltd; 2009
3. Holladay J, Janes J. - Topographic changes in corneal asphericity and effective optical zone after laser in situ keratomileusis. [Journal of Cataract and Refractive Surgery; 28:942-947(2000)].
4. S. Marcos, Aberrations and visual performance following standard laser vision correction. [Journal of Refract Surgery 18,596-601 (2001).]
5. Manoj S. Venkiteshwar, Dr. John Chang, Hong Kong. Zyoptix Personalized Aspheric Treatment (PAT) for LASIK Procedures [Internet] April 2008. Available from <http://www.jamesjlaux.com>
6. Marcos, S - Are changes in ocular aberrations with age a significant problem for refractive surgery? [Journal of refractive surgery, 18, 572-578(2002)].
7. Chi-xin Du, Ye Shen and Yang Wang- Comparison of high order aberration after conventional and customized ablation in myopic LASIK in different eyes of the same patient [Journal of Zhejiang University Sci B.;8(3): 177–180.(2007) (Pub med)]
8. Maria Clara Arbelaez, Camila Vidal- Six-month clinical outcomes in LASIK for high myopia with aspheric «aberration neutral» ablations using the AMARIS laser system [Journal of Emmetropia; 1: 111-116(2010)]
9. Lee J M, Lee DJ, Jung WJ, Park WC. - Comparison between anterior corneal aberration and ocular aberration in laser refractive surgery. [Korean Journal of Ophthalmology; 22:164-168(2008) (Pub Med)]
10. Marcos S, Barbero S, Llorente L, Merayo-Llolves J. - Optical response to LASIK surgery for myopia from total and corneal aberration measurements. [Invest Ophthalmol Vis Sci; 42:3349-3356(2001)]

How to cite this article: Patel AN, Desai D, Solanki K. Corneal higher order aberrations after Aspheric LASIK treatment. Int J Health Sci Res. 2016; 6(2):107-113.
