

Case Report

Completely Isolated Duplication Cyst (CIDC) in a New Born: A Case Report

A K Bansal^{1*}, Shamima^{2*}, Mamta Singh^{3**}, J K Singh^{4**}, Ajai Gopal^{5*}, Arpit Bansal^{6*}¹Director and Senior Laparoscopic Surgeon, ²HOD Pathology, ³Prof. Pathology, ⁴Assist. Prof. Pediatric Surgery,⁵Senior Pediatrician, ⁶Consultant Surgeon,

*Jeevan Jyoti hospital, Allahabad, UP, India.

**Moti Lal Nehru Medical College, Allahabad, UP, India.

Corresponding Author: Mamta Singh

*Received: 19/11/2015**Revised: 11/12/2015**Accepted: 16/12/2015*

ABSTRACT

Completely isolated duplication cysts (CIDC) involving the digestive tract are extremely rare variant of enteric duplication cyst. Clinically CIDC present either as vague, soft abdominal mass or acute abdomen due to volvulus, infection and/or perforation. It can be diagnosed by ultrasound and computed tomographic (CT) imaging as cystic lesion even in prenatal and perinatal period. The lesion can be tubular or cystic, sessile or pedunculated found in peritoneal or retroperitoneal region. Microscopically they are characterized by outer muscular and inner mucosal layer resembling any part of digestive tract; sometimes mucosa can show non-intestinal origin mucosal components. We are reporting a case of a new born presented with distension of abdomen and obstipation for two days. Computed tomographic imaging revealed an intra-abdominal cyst of approximately 12x7x7 cm in size vaguely occupying the region extending from right iliac fossa to left hypochondrium. Laparotomy was done under general anesthesia. One huge cyst was seen at ileocaecal junction in vicinity of mesentery of small intestine. The cyst was partly aspirated to reduce the size for easy excision. Grossly it was cystic with central narrowing, thin walled, filled with yellow brown turbid fluid and unremarkable mucosa. Microscopically it showed outer muscle wall and mucosa lined by both ectodermal and endodermal epithelium that is stratified squamous and villous columnar epithelium respectively. The presence of dual origin epithelium is still not explained by various theories which make it unique clinical and pathological entity.

Key words: Completely isolated duplication cysts, endodermal, ectodermal.

INTRODUCTION

The gastrointestinal duplications are rare congenital malformations but it's completely isolated variant is extremely rare. These cysts may be saccular or elongated cystic masses that contain redundant muscle layers along with mucosa. It can be seen in esophagus, stomach, small intestine or colon ^[1] though can occur in any part of gastrointestinal tract. Most common site of duplication

cyst is mesenteric side of small intestine.

^[2] This may be seen in patients with other developmental malformations. ^[3-5] The lining epithelium of the cyst resembles with that of digestive tract. The symptomatology depends on site and size; most common is intestinal obstruction with distention of abdomen, palpable mass and urinary symptoms. We present a case of twelve days old male who reported to hospital emergency for abdominal

distension, distress and obstipation since two days.

CASE REPORT

Presentation: A healthy baby at birth, delivered by normal vaginal delivery, weighing 2.9 kg, on twelfth day started showing distention of abdomen along with oliguria without defecation since two days. Clinical examination revealed prominent abdominal blood vessels and a large soft vague mass in abdomen. The infant was in distress but fully conscious.

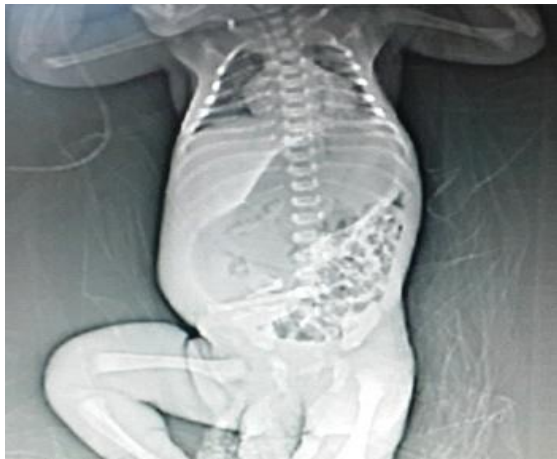


Figure 1 CT scan showing an intraperitoneal cyst

Intra-operative: Laparotomy was done under general anesthesia. It was a sessile cyst measuring 12x7x7 cm was on the mesenteric side of ileum and it was not communicating with the intestine (Figure 2). Fluid was partly aspirated to reduce the size of cyst for easy excision. There was no other abnormality seen in the vicinity. Cyst was removed and abdomen was closed.

Post-operative: After operation patient remained on ventilator for two days, on third day ventilator was removed but patient's oxygen supply was maintained. Patient was on glucose saline drip. The intestinal activity started within 24 hours and after 48 hours patient passed dark colored stool but developed fever with mild respiratory distress. The hematological investigation showed

The preoperative investigations showed normal hematological and biochemical values. Ultrasound showed a big abdominal cyst occupying left hypochondria upto right ileac fossa. Exact origin of the cyst could not be ascertained. CT scan showed a cystic mass, 12x7x7 cm in size partly filled with air and fluid on the right side of abdomen near ileo-caecal junction in vicinity of small intestine extending up to left hypochondrium (Figure 1). Radiologically it was diagnosed as a case of enteric duplication cyst.

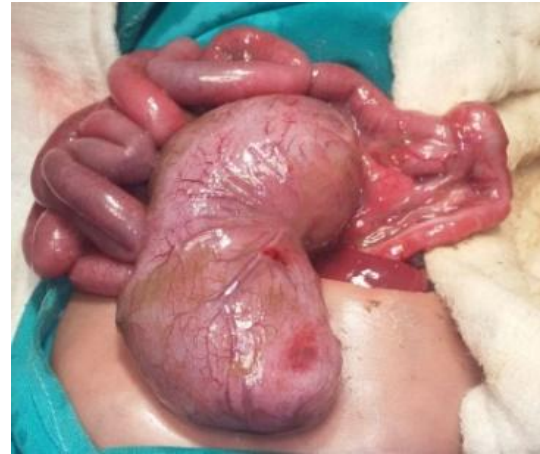

Figure 2 Cyst at mesenteric side of ileum

polymorphoneuclear leukocytosis followed by decrease in platelet count; hence platelet concentrate was transfused. Oxygen supply and saline drip continued along with a watch on body temperature with the treatment. On 4th post-operative day pus discharge was seen at suture site. Pus culture was done and most sensitive antibiotic was given parenterally while continuing oxygen and saline drip. On 10th day of operation baby was a febrile; nasal feeding was started and well tolerated followed by passing yellow colored stool. In subsequent days oxygen support and saline drip was discontinued and nasal feeding was replaced by oral feeding. On 20th day of operation patient was asymptomatic; his general condition and bowel habits were normal, was tolerating

feeds well. At the time (21th day) of discharge his weight was 2.75 kg.

Pathology report:

Gross: A formalin fixed cystic biopsy measuring 9x5x5 cm, cyst wall showed prominent blood vessels along with a small soft lymph node 0.5 cm in diameter attached to other side of cyst. In the middle the cyst was narrowed by 1 cm in width. On cutting it showed 0.5 cm thick cyst wall. The cyst was filled with yellow brown turbid fluid. The mucosa was unremarkable partly covered with thin mucoid material, the inner side of cyst showed an angulation in the middle at narrowing of the cyst. Representative sections were processed for histology.

Microscopy: The wall of the cyst showed smooth muscle layer covered by two type

of epithelium (Figure 3). The epithelium of intestinal type showed intestinal villi (Figure 3, blue arrow) along with moderate atrophy (flattening) at places with loss of villi. The villi showed columnar epithelium with goblet cells. At places the mucosal cells changed from low columnar to cuboidal type. A transition was seen between villous epithelium and squamous epithelium (Figure 3, black arrow) covering an area of cyst inner lining. In this area cyst was lined by pseudo stratified squamous epithelium. Small pouches lined by squamous epithelium (Figure 4, black arrow) and low columnar epithelium were also seen in muscle layer (Figure 4).

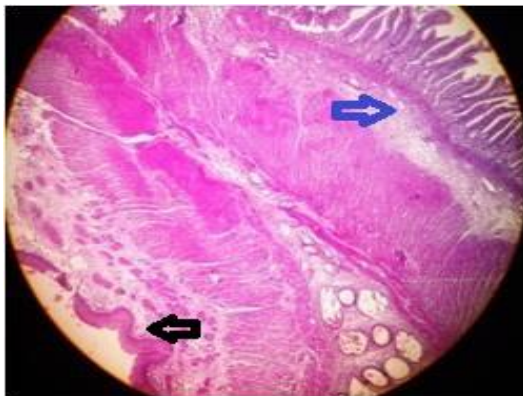


Figure 3 (H&E, 40X) Dual lining of endodermal cyst

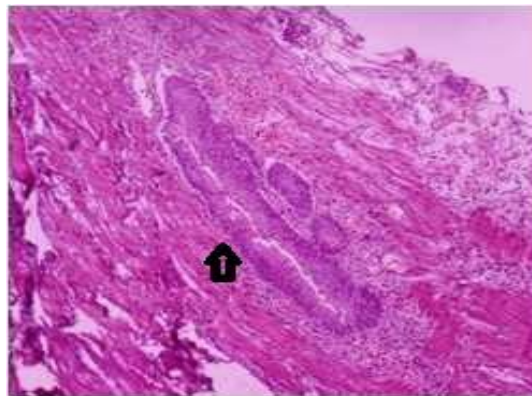


Figure 4 Pouch lined by stratified squamous epithelium

The lymph node showed evidence of sinus catarrh. The histological findings were consistent with the diagnosis of enteric duplication cyst. There was no evidence of any neoplastic or dysplastic lesion in the biopsy. Since there was no communication with gastrointestinal tract therefore the final diagnosis of CIDC was confirmed.

DISCUSSION

Enteric duplication cysts are rare malformations of the gastrointestinal tract, mostly they are in small intestine [2] and completely isolated duplication cysts are extremely rare enteric malformations having no communication with adjacent alimentary tract. [6] These cysts usually

show outer muscular layer and inner layer of gastrointestinal mucosa. Sometimes mucosa can show mucosal components of non-intestinal origin. [7] In the present case the sessile duplication cyst was present on the mesentery adjacent to small intestine and was not communicating with the adjacent gut.

During operation it was found distended and tense therefore 200 ml fluid was aspirated for easy excision. Histologically it showed both endodermal and ectodermal epithelial lining, at places small pouches of both type epitheliums were seen in muscle coat. These pouches could have been formed due to pressure of intracystic fluid on epithelium to dip down in muscle coat as happens in case of

Rokitansky pouches of chronic cholecystitis. Cysts lined with multiple types of non-intestinal epithelium have also been reported. [6,7]

Usually duplication cyst has got blood supply and smooth muscle wall from the adjacent intestinal segment. [2] Very rarely especially in completely isolated duplication cysts; it may have its own independent blood supply. [8] Sometimes they get blood supply from mesentery and may get detached from gut and present as mesenteric cyst. [6] Sometimes CIDC of the mesentery get blood supply from adjacent retro peritoneum rather than mesenteric vessels. This supports the view that part of embryonic gut must have sequestered during early embryonic life. [6] Though exact pathogenesis of duplication cyst is not known but there are many hypotheses like persistence of fetal enteric diverticula, intrauterine vascular occlusion or failure of intestinal recanalization. [9] The most accepted is about transition of the embryonal intestinal tract from solid to tubular state which occurs between 6 and 8 weeks of intra-uterine life, involves the coalescence of multiple vacuoles. The derangement of this may be responsible for the formation of the double walled intestinal cysts [4,10] as seen in the present case.

Clinically CIDC present either as vague, soft abdominal mass or acute abdomen due to volvulus, intussusceptions, infection, perforation and pressure effect on adjacent organs especially on bowel causing obstruction. [11,12] Though malignancies like squamous cell carcinoma, adenocarcinoma and carcinoid tumors have also been reported in these cases. [8,13]

The new born presented with distension, obstipation, oliguria and soft vague abdominal mass. This could be due to the pressure effect of cyst on viscera including bowel. The treatment of choice for enteric duplication cyst is surgical

excision with anastomosis. [2] Since blood supply of cyst and enteric muscle wall is common therefore part of adjacent normal intestine is also resected along with excision of duplication cyst. [14]

In our case it was a sessile cyst without pedicle, so the patient was saved from danger of torsion at pedicle. The duplication cyst was not communicating with intestine and did not share the blood supply with gastrointestinal tract; therefore excision of bowel was not required. Excision of the completely noncommunicating duplication cyst was done with good recovery.

CONCLUSION

In clinical practice knowledge of various presentations of duplication cysts for early and accurate diagnosis is the most important requirement for timely and appropriate surgical treatment to gain good outcome.

REFERENCES

1. Stanley L Robbins, Vinay Kumar, Ramzi S Cotran. Robins & Cotran Pathologic Basis of Disease, 8th edition. Philadelphia. Elsevier. 2010.
2. IsrarZahir, Shazia Yusuf, FareenZada et al, Case Report Duplication Cyst in a New Born. International Journal of Pathology; 2010; 8(2): 84-86.
3. A.Dutheil-Doco, H. D. Le Pointe, M. Larroquet, et al, "A case of perforated cystic duplication of the transverse colon," Pediatric Radiology, 1998; 28 (1): 20-22.
4. R. L. Teele, C. I. Henschke, and D. Tapper, "The radiographic and ultrasonographic evaluation of enteric duplication cysts," Pediatric Radiology, 1980; 10 (1): 9-14.
5. V. Dombale, B. V. Patil, S. A. Kadam et al, "Enteric duplication cyst of caecum presenting with intestinal obstruction-a case report," Journal of Krishna Institute of Medical Sciences University, 2012; 1 (2): 147-149.
6. Menon P, Rao KL, Vaiphei K. Isolated enteric duplication cysts. J Pediatr Surg. 2004;39:E5-7.

7. Jessika Leigh Baumann and Charmi Patel, Enteric Duplication Cyst containing Squamous and Respiratory Epithelium: An Interesting case of Typically Paediatric Entity Presenting in an Adult Patient. Case Report in Gastrointestinal Medicine, 2014.
8. M. Prada Arias, F. García Lorenzo, M. Montero Sánchez et al, "Enteric duplication cyst resembling umbilical cord cyst," Journal of Perinatology, 2006; 26 (6), 368–370.
9. S. O. Choi, W. H. Park, and S. P. Kim, "Enteric duplications in children-an analysis of 6 cases," Journal of Korean Medical Science, 1993;8(6):482–487.
10. J. L. Bremer, "Diverticula and duplications of the intestinal tract," Archives of Pathology & Laboratory Medicine, 1994; 38: 132–140.
11. Nitin Pant, Jitendra K. Grover, et al, Completely isolated enteric duplication cyst associated with a classic enterogenous duplication cyst, J Indian Assoc Pediatr Surg. 2012; 17(2): 68–70.
12. M. I. Otter, C. G. Marks, and M. G. Cook, "An unusual presentation of intestinal duplication with a literature review," Digestive Diseases and Sciences, 1996; 41 (3): 627–629.
13. G. Blank, A. Königsrainer, B. Sipos et al, "Adenocarcinoma arising in a cystic duplication of the small bowel: case report and review of literature," World Journal of Surgical Oncology, 2012; 10 (55).
14. P. Srivastava, A. N. Gangopadhyay, V. Kumar et al, "Noncommunicating isolated enteric duplication cyst in childhood," Journal of Pediatric Surgery, 2009; 44 (7): E9–E10.

How to cite this article: Bansal AK, Shamima, Singh M et al. Completely isolated duplication cyst (CIDC) in a new born: A case report. Int J Health Sci Res. 2016; 6(1):545-549.

International Journal of Health Sciences & Research (IJHSR)

Publish your work in this journal

The International Journal of Health Sciences & Research is a multidisciplinary indexed open access double-blind peer-reviewed international journal that publishes original research articles from all areas of health sciences and allied branches. This monthly journal is characterised by rapid publication of reviews, original research and case reports across all the fields of health sciences. The details of journal are available on its official website (www.ijhsr.org).

Submit your manuscript by email: editor.ijhsr@gmail.com OR editor.ijhsr@yahoo.com