

Case Report

Comparison of Various Techniques for Gingival Depigmentation: Report of 3 Cases

Deepthi K^{1*}, Sarita Joshi Narayan^{2**}, Umesh Yadalam^{3**}, Vaibhavi Joshipura^{4**}

¹Senior Lecturer, ²Professor and Head, ³Professor, ⁴Professor and Principal,
*Dept of Periodontics, KLE Society's Institute Of Dental Sciences, #20, Yeshwanthpur Suburb, Opposite CMTI,
Tumkur Road, Bangalore 500092, Karnataka, India.

**Department of Periodontics, Sri Rajiv Gandhi College of Dental Sciences, Bangalore.

Corresponding Author: Deepthi K.

Received: 05/11/2015

Revised: 28/12/2015

Accepted: 28/12/2015

ABSTRACT

Background: The colour of the gingival is determined by several factors including the number and size of blood vessels, epithelial thickness, quality of keratinization and the pigments within the epithelium. Melanin, carotene, reduced haemoglobin and oxy haemoglobin are the main pigments contributing to the normal colour of the oral mucosa. The gingival are the most frequently pigmented intra oral tissues. Gingival hyper pigmentation may cause esthetic problems and embarrassment, especially in patients with a gummy smile. Various techniques have been used for gingival depigmentation – laser, electro cautery, chemicals, abrasion burs, scraping, and excisional method.

In the present case report scalpel, electro cautery, and diode laser has been tried for depigmentation, which are simple, effective, and yield good results, along with good patient satisfaction.

Method: The study included 3 patients with a split mouth technique. Laser technique has been used for all 3 patients and it has been compared over other 2 technique such as scalpel, and electro cautery method. All procedures were performed under local anaesthesia. Visual analogue scale (VAS) was given for all 3 patients. Patients were reviewed at the end of 1st week, 6 months and 1 year.

Result: Results were satisfactory. Healing was uneventful and required no supportive therapy for all 3 techniques. None of the patient exhibited signs of inflammation or discomfort during 1st week of treatment. Patient reported with no pain on using laser method. Patient experienced slight to moderate pain on scalpel and electro cautery method

Conclusion: From the present case report we can conclude that depigmentation procedure was successful in all 3 techniques and the patient was comfortable during and after the surgeries and with a satisfied result.

Depigmentation using Laser was having less bleeding, less painful, quicker to perform and healing was uneventful

Key words: Depigmentation, Repigmentation, Laser, Electrocautery, Excisional method & Visual analogue scale.

INTRODUCTION

Physiological pigmentation of the mucosa is clinically manifested as multifocal or diffuse melanin pigmentation which is variable in different ethnic groups. Melanin pigmentation is not pathology were in it can perceive as poor

aesthetics. Patients consider their black gums as unaesthetic it doesn't represent a medical problem. Pigmentation is aggravated in patients with a "gummy smile" or excessive gingival display while smiling. [1]

Etiology- [2]

Physiologic oral pigmentation

Pathologic oral pigmentation

- Exogenous
 - Coloring agent in food
 - Tobacco
 - Metallic pigmentation
 - Amalgam tattoo
- Endogenous
 - Addison's disease
 - Peutz Jeghers Syndrome
 - Albright Syndrome

Gingival depigmentation is a periodontal plastic surgical procedure whereby the gingival hyper pigmentation is removed or reduced by various techniques.

Indication for depigmentation depends on the individual persons for improved aesthetics.

Various techniques to remove gingival hyper pigmentation are- [4]

- Excisional method using blade
- Electro surgery
- Cryosurgery
- Abrasion with diamond bur
- Various types of lasers
- Chemical method
- Free gingival graft
- Gingivectomy has been used for cosmetic therapy.

CASE REPORTS

The present case report is to compare Laser with Electrocautery and Excisional method using a blade. And also to determine which method is ease to perform and acceptable to patients

MATERIALS AND METHODS

Patients are recruited from Department of Periodontics, Sri Rajiv Gandhi College of Dental Sciences, and Bangalore. A Split mouth design was planned to compare Laser with Electrocautery and excisional method using blade. And pain was measured using Visual analogue scale (VAS) and

repigmentation was assessed at 6 months and one year.

Inclusion criteria:

- Age group 25-35 years

Exclusion criteria:

- Systemic diseases
- Pathologic hyper pigmentation
- Improper wound healing
- Smoking habits

Procedure:

3 patients with a chief complaint of black discoloration of gums had reported to Department of Periodontics, Sri Rajiv Gandhi College of Dental Sciences and hospital Bangalore. The procedure was explained to the patients and written consent was obtained. A complete medical, family history and blood investigations were carried out to rule out any contraindication for surgery. Local anaesthesia was infiltrated in the maxillary and mandibular anterior region from premolar to premolar (Lignocaine with adrenaline in the ratio 1:100000 by weight). Laser (diode laser, Frequency - 49 Hz, Power-2.5W, and Pulsating mode) was used for all 3 patients and Electrocautery (Loop electrode, Power of electrode was set at 2 W) or blade (No. 15 BP blade which is placed parallel to gingival surface) was used on the other side of the arch. Pressure was applied with sterile gauze soaked in local anaesthetic agent to control haemorrhage during the procedure. After removing the entire pigmented epithelium and a thin layer of connective tissue with the laser, Electrocautery and blade, the exposed surface were irrigated with saline. Care was taken to see that all remnants of the pigment layer were removed. The surgical area was covered with a periodontal dressing. The patient was reviewed at the end of 1 week and 6 months.

Case 1- Age 28 yr, female: Depigmentation was done on maxillary arch, where excisional method was done on 1st quadrant and laser was done on 2nd quadrant.

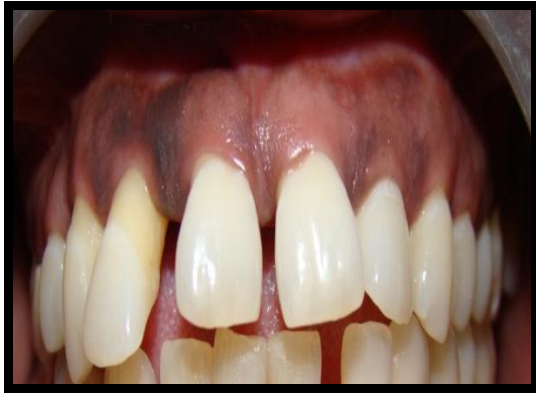

Figure 1- pre op pic

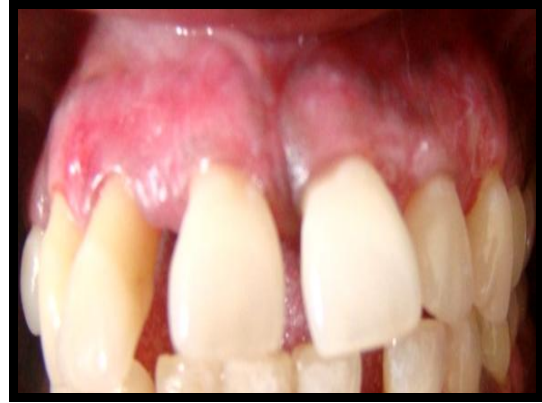

Figure 2- 1 week post op pic

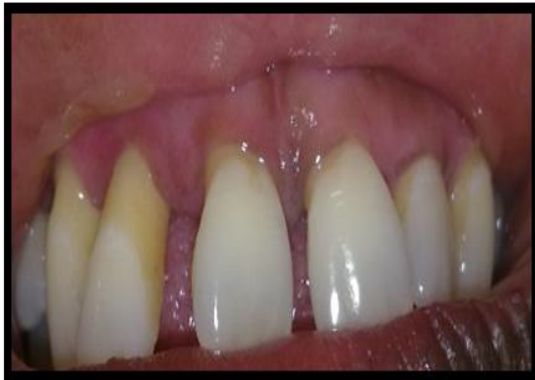

Figure 3 - 6th month follow up

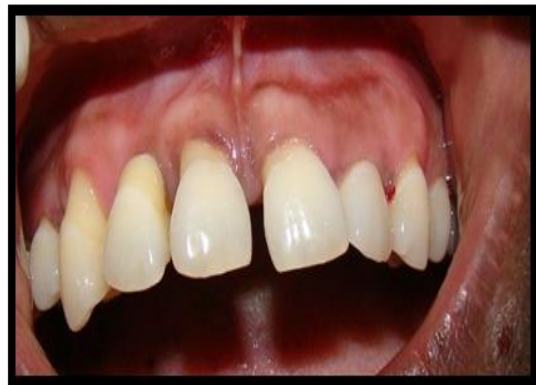

Figure 4- 1 year follow up

Case 2 – Age 28 yrs, Female:
Depigmentation was done on mandibular arch, were laser was done on 4th quadrant

and Electrocautery was done on 3rd quadrant

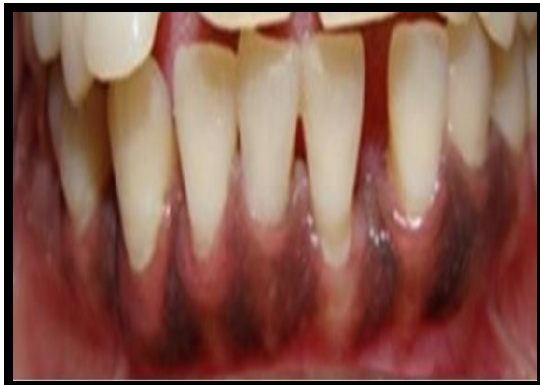

Figure 5- Pre op pic

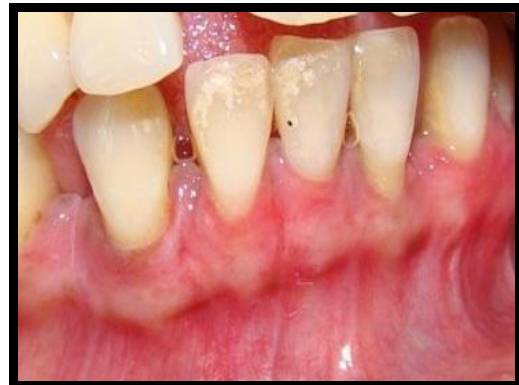

Figure 6 - 1 week post op

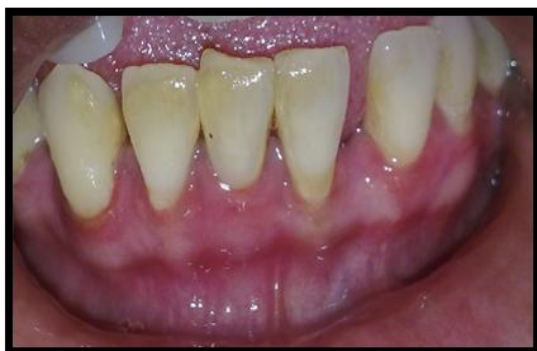

Figure 7- 6th month follow up

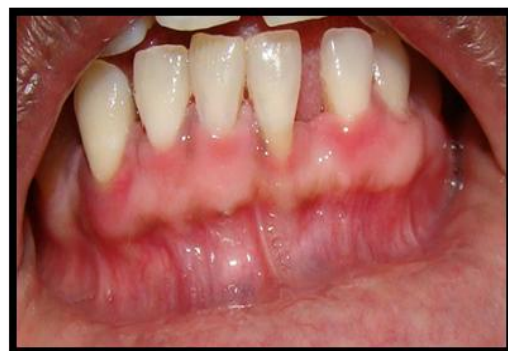

Figure 8 - 1 year follow up

Case 3 – Age 30 yrs, female : Depigmentation was done on maxillary arch, where excisional method was done on

1st quadrant and laser was done on 2nd quadrant

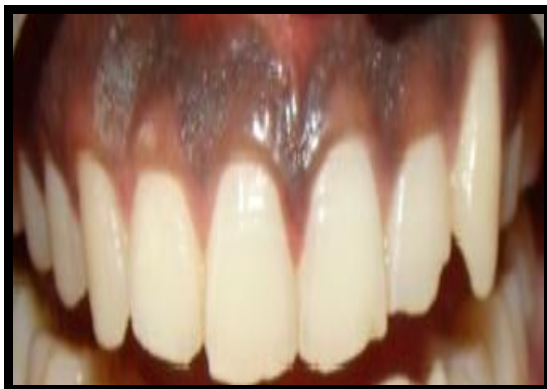

Figure 9- Pre op pic

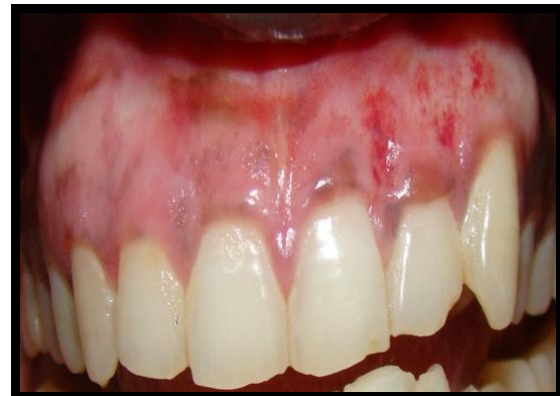

Figure 10- 1 week post op pic

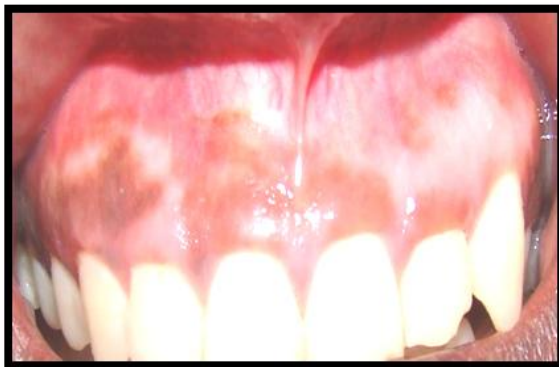


Figure 11- 6th month follow up

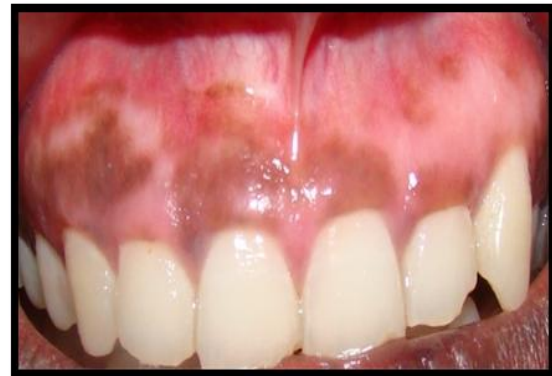

Figure 12- 1 year follow up

RESULTS

Table1- Result showing the difference between 3 different techniques in the case report.

Information	Case 1	Case 2	Case 3
Age	28	28	30
Sex	Female	Female	Female
Split mouth design	Laser v/s Excisional	Laser v/s Electrocautery	Laser v/s Excisional
Pain /discomfort (VAS)	Laser- (VAS- 0) Excisional- (VAS- 3±1)	Laser- (VAS- 0) Electrocautery – (VAS – 4±1)	Laser- (VAS- 0) Scrape – (VAS- 3±1)
Patient acceptance	Laser better than excisional	Laser better than Electrocautery	Laser better than excisional
Repigmentation (after 6 months)	No repigmentation	No re pigmentation	More re pigmentation
Repigmentation (after 1 year)	Slight re pigmentation	Slight pigmentation	More re pigmentation

The result, suggest that pain was less when laser was used as compared to both Electrocautery and excision. Patient acceptance was better when laser was used as compared to excision and Electrocautery. Healing after 1 week was uneventful for all 3 techniques and repigmentation after 6 months for all 3 techniques.

DISCUSSION

Oral pigmentation is seen in all ethnic groups. There are no significant

differences in oral pigmentation between males and females.

Physiologic pigmentation is genetically determined, but the degree of pigmentation is partially related to mechanical, chemical, and physical stimulation. [4,5]

The gingival hyper-pigmentation is caused by excessive melanin deposition mainly located in basal and supra basal cell layer of the epithelium.

The various technique described in this article-

Laser

Electrocautery

Excisional method using blade

'LASER' is an acronym for Light Amplification by Stimulated Emission of Radiation. The commonly used high power lasers CO₂ and Nd: YAG are capable of excellent soft tissue ablation, and have an adequate haemostatic effect. As such, these lasers have been generally approved for soft tissue management in Periodontics and oral surgery.

Diode laser light at 800–980 nm is poorly absorbed in water, but highly absorbed in haemoglobin and other pigments. Diode laser is FDA approved oral soft tissue surgery in 1995; laser is an excellent soft tissue surgical laser, indicated for cutting and coagulating gingiva and oral mucosa, and for soft tissue curettage or sulcular debridement. The advantages of diode lasers are the smaller size of the units as well as the lower financial costs compared to other lasers.^[6]

Electrocautery requires more expertise. Prolonged or repeated application of current to tissue induces heat accumulation and undesired tissue destruction. Contact with periosteum or alveolar bone and vital teeth should be avoided.^[7] Patients complain of more pain with Electrocautery than laser

Scalpel surgical technique is highly recommended as there are no constraints.^[8] It is known that the healing period for scalpel wounds is faster than other techniques.

However, scalpel surgery may cause bleeding during and after the procedure. Depigmentation with lasers achieves good results, but there is a need for sophisticated and expensive equipment. On the other hand it is almost painless compared to other two techniques.

Repigmentation is described as spontaneous and has been attributed to the activity and migration of melanocytic cells

from surrounding areas.^[9] In the present case, certain localized areas of repigmentation were seen at the end of 6 month. The case is being followed up to estimate further the extent and rate of repigmentation. Limitation of this study larger sample size is required to differentiate which technique is better than other.

CONCLUSION

From the present case series we can conclude that depigmentation procedure was successful in all 3 techniques and the patient was comfortable during and after the surgeries and with a satisfied result.

Depigmentation using Laser was having less bleeding, less painful, quicker to perform and healing was uneventful.

REFERENCES

1. H Sanjeevini, pudakalkatti P, BG Soumya et al. Gingival de pigmentation: 2 case reports. World Journal of Medical Pharmaceutical and Biological Sciences 2012; 2:1-4.
2. Azzeh MM. Treatment of gingival hyperpigmentation by Erbium- Doped: yttrium, Aluminium, and Garnet laser for esthetic purposes. J Periodontol 2007; 78:177-184.
3. AK Kanakamedala, A Geetha, T Ramakrishnan, et al. Management of gingival hyper pigmentation by the surgical scalpel technique- Report of 3 cases. J Clin Diagn Res 2010; 4:2341-2346.
4. Dummett, C.O. Oral pigmentation. First symposium of oral pigmentation. J Periodontal 1960; 31:356.
5. Cicek Y, Ertas U. The normal and pathological pigmentation of oral mucous membrane: a review. J Contemp Dent Pract 2003; 15;4:76-86.
6. Atsawasuman P, Greethong K, Nimmanon V. Treatment of gingival hyperpigmentation for esthetic purpose by Nd; YAG Laser: report of 4 cases. J Periodontol 2000; 71:315-321.
7. Ozbayrak S, Dumla A, Ercalik - Yalcinkaya S. Treatment of melanin

- pigmented gingiva and oral mucosa by CO2 laser. Oral Surg Oral Med Oral Pathol Oral Radiol Endod 2000; 90: 14-15.
8. Almas K, Sadig W. Surgical treatment of melanin- pigmented gingiva; an esthetic approach. India J Dent Res 2002; 13:70-73.
9. Mokeem SA. Management of Gingival Hyperpigmentation by Surgical Abrasion: Report of Three Cases. Saudi Dent J 2006; 18:162-166.

How to cite this article: Deepthi K, Narayan SJ, Yadalam U et al. Comparison of various techniques for gingival depigmentation - report of 3 cases. Int J Health Sci Res. 2016; 6(1):530-535.

International Journal of Health Sciences & Research (IJHSR)

Publish your work in this journal

The International Journal of Health Sciences & Research is a multidisciplinary indexed open access double-blind peer-reviewed international journal that publishes original research articles from all areas of health sciences and allied branches. This monthly journal is characterised by rapid publication of reviews, original research and case reports across all the fields of health sciences. The details of journal are available on its official website (www.ijhsr.org).

Submit your manuscript by email: editor.ijhsr@gmail.com OR editor.ijhsr@yahoo.com