

Original Research Article

Study of Laparoscopic Appendicectomy in Complicated Appendicitis

Dr. B. Hemashankara Rao¹, Dr. RV Srinivasarao²

¹Associate Professor, ²Assistant Professor,
Department General Surgery, MIMS (Maharagah's Institute of Medical Sciences).
Vizianagaram, Andhra Pradesh, India.

Corresponding Author: Dr. B. Hemashankara Rao

Received: 06/10/2016

Revised: 27/10/2016

Accepted: 04/11/2016

ABSTRACT

Background: Complicated appendicitis is associated with an increased risk for postoperative complications and has been considered a relative contraindication of laparoscopic appendectomy.

Objective: To make awareness and to provide satisfactory results of laparoscopy in complicated appendicitis.

Methodology: The study consists of 30 patients who have undergone laparoscopic appendectomy at MIMS (Maharagah's Institute of Medical Sciences). The study population was enrolled after fulfilling the selection criteria from OPD (Out Patient Department) of General Surgery Due consideration of was given to match the variables like age, sex, duration of symptoms etc., to the possible extent. Informed consent was taken from all the patients who are involved in this study. Patients diagnosis was based on clinical findings, blood counts, and abdominal sonography.

Results: Thirty patients underwent laparoscopic appendectomy for complicated appendicitis. Of the 30 patients, mass with perforated appendix cases are 18, gangrenous appendix are 6, mass in right iliac fossa only one case. Post operation wound infection rate is very less, moderate wound infection is observed only in 4 cases (8%) and remaining 26 cases (92%) did not develop any wound infection.

Conclusions: The present study proved that laparoscopic appendectomy is the BEST approach in complicated appendicitis.

Keywords: Appendicectomy, Appendicitis, Laparoscopy and Surgery.

INTRODUCTION

Appendicitis is the commonest abdominal surgical emergency in the world. It can occur at any age, though it is rare under the age of five years. ^[1] The commonest problem causing lot of suffering, pain and morbidity. Most commonly patients present with symptoms like pain, vomiting and fever delay may lead to complications like appendicular abscess/mass, gangrene, perforation and peritonitis. Surgery is the main stay of treatment. ^[2]

Laparoscopic surgery is a less morbid procedure that usually results in an uneventful postoperative recovery for many

surgical procedures. ^[3] The distinguishing features of a laparoscopic approach over conventional open approach include shorter hospital stay, quicker return to activity, reduced pain, and better cosmesis. ^[4] These potential patient benefits coupled with superior outcomes have facilitated the adoption of laparoscopic approach as the gold standard for surgical procedure. However, the role of laparoscopy in appendectomy has remained it might be consensus yet. ^[5]

Laparoscopic appendectomy has rapidly developed in recent years. Since Semm published the first complete removal

of the appendix via laparoscopic surgery in 1983 and Schreiber performed the first laparoscopic appendectomy in a patient with acute appendicitis in 1987, laparoscopic appendectomy has been included in practically all hospitals worldwide as the usual procedure in emergency departments. [6] Laparoscopic appendectomy has several advantages over the open approach, such as less surgical trauma, a better postoperative recovery, exploration of the entire abdominal cavity (especially in obese patients and women at a fertile age. [7] A quick return to normal patient activity, and a better cosmetic outcome. The tendency toward reduced patient morbidity after surgery has enabled the development of techniques requiring an increasingly less invasive access to the operating field. [8] Over the last decade, surgeons in a bid to be less invasive and provide greater comfort to patients, have developed means of access to the abdominal cavity with less surgical trauma such as natural-orifice transluminal endoscopic surgery and single-incision laparoscopic surgery. Appendicitis remains the most common intraabdominal surgical pathology. [9] Conventional management involves open appendectomy (OA), a simple operation that carries minimal morbidity. Although laparoscopic appendectomy (LA) has been described for 20 years, recent studies shows pediatric surgeons have shown some reluctance to accept its routine use because of perceived lack of significant benefit. Moreover, the safety of LA in appendicitis still remains research is going on. [10]

Minimal invasive surgery has had a considerable impact on common surgical techniques and has almost replaced established operative procedures such as in cholecystectomy. The laparoscopic approach for the treatment of acute appendicitis is becoming very popular. [11] The main advantage of the laparoscopic surgery in abdominal surgery is related to the avoidance of a laparotomy wound and its infection, less pain, short stay in hospital, early return to normal work and cosmosis.

[12] The role of laparoscopic appendectomy remains the best as many researchers have suggested that overall morbidity is very less depending upon the degree of appendicitis. In cholecystectomy has emerged as the clear gold standard, so also in appendicitis. [13]

The aim of the present work is study of laparoscopic appendicectomy in complicated appendicitis in a teaching hospital. Another objective of this study is to make awareness and to clear some of the issues and to provide satisfactory results of laparoscopy in complicated appendicitis.

MATERIALS AND METHODS

The study consists of 30 patients who have undergone laparoscopic appendectomy at MIMS (Maharagah's Institute of Medical Sciences). The study population was enrolled after fulfilling the selection criteria from OPD (Out Patient Department) of General Surgery Due consideration of was given to match the variables like age, sex, duration of symptoms etc., to the possible extent. Informed consent was taken from all the patients who are involved in this study. Patients' diagnosis was based on clinical findings, blood counts, and abdominal sonography.

Inclusion criteria

Appendicular abscess/non palpable mass, gangrenous appendix, perforated appendicitis, appendicitis with peritonitis, appendicitis with dense adhesions.

Exclusion criteria

Laparoscopic appendectomy without any complication, suspicion of malignancy, and pregnant with complicated appendicitis.

Data was collected on combining the clinical examination; pre operative findings as well post operative recovery and incidence of complications during 3 months follow up. For this study patients age, sex, history of previous abdominal surgery, concomitant illness and chronic medication usage etc. were recorded. Pre operative right lower quadrant pain, right lower quadrant tenderness, nausea, vomiting, anorexia and fever, leucocytosis, urine examination and

ultrasonography of abdomen were recorded. Post operatively early and late complications like-peritonitis, wound infection, intra abdominal abscesses, fistula formation, and appendicitis in the stump, port site hernia, adhesions leading to intestinal obstruction were recorded.

Statistical analysis

Using SPSS software version 16 statistical analyses was done. The Laparoscopic Appendicitis and Appendectomy analysis and variables were done using Students’ ‘t’ test.

RESULTS

Study consists of 30 patients who underwent laparoscopic appendectomy. Out of 30 patients, 17 patients were males (56%) and 13 patients were females (44%). The mean age of the patients in the groups was 24.28 ± 1.9 . All the patients have complained of abdominal pain, vomiting and fever. Less commonly constipation and diarrhea. All patients considered for this study had right iliac fossa tenderness (100%). Others sites of tenderness other than right iliac fossa were umbilical 8 (32%), epigastric 5 (20%), Lumbar 1(4%) and hypogastric 1(4%). Abdominal ultrasonography revealed abnormal pathology like inflamed appendix, paralytic ileus, minimal free fluid in RIF, early mass etc.

Table 1: Laparoscopic Appendectomy subjects Statistical Analysis

Characteristics	Mean \pm SD	SEM	t-Value	df	p-Value
Laprosopic Subjects	24.28 \pm 1.9	0.3469	69.9932	29	<0.0001

P value and statistical significance: The two-tailed P value is less than 0.0001

By conventional criteria, this difference is considered to be extremely statistically significant.

Confidence interval:

The actual mean is 24.2800

The difference between these two values is 24.2800

The 95% confidence interval of this difference:

From 23.5705 to 24.9895

Intermediate values used in calculations: $t = 69.9932$, $df = 29$, standard error of difference = 0.347

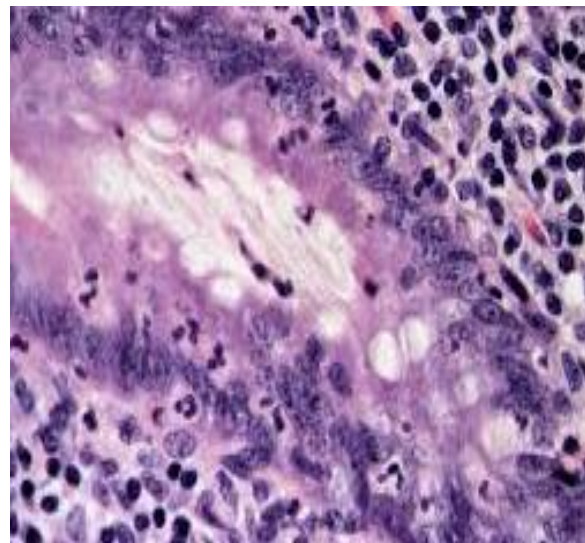


Figure 1: Histological picture of Appendicitis

Two of the study group patients had port site infection, treated with opening of the port site suture, dressing and antibiotics and increase in hospital stay. After post operation, oral feeds were resumed on an average in about two days.

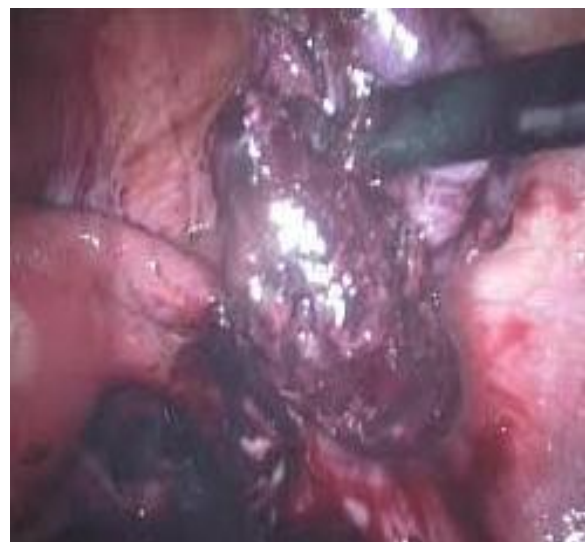

Figure 2: Gangrenous appendix picture

Patients were in hospital for a period of maximum of 3 days after laparoscopic surgery. During follow up for a period of 3 months complications like peritonitis, intra abdominal abscesses, fistula formation, stump appendicitis, burst of ports and adhesive intestinal obstruction were nil.

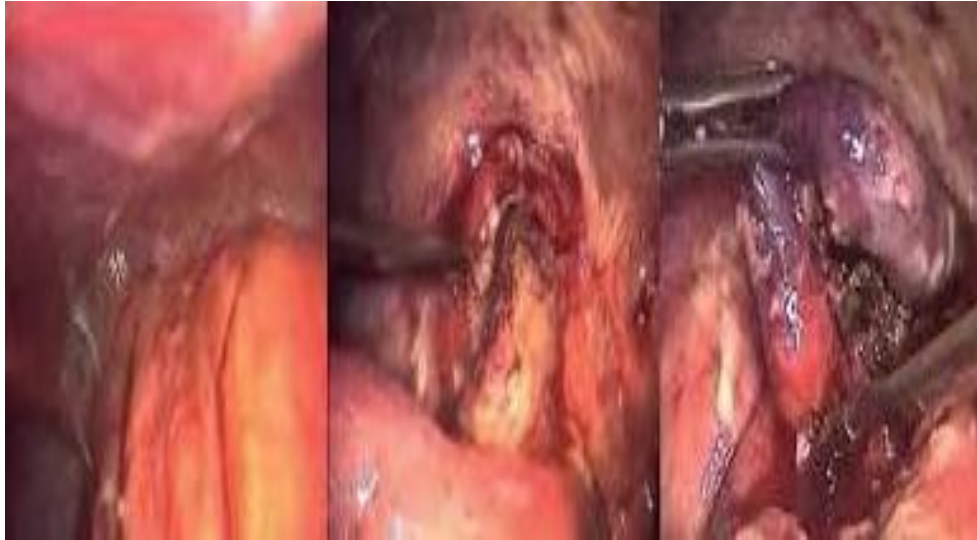

Figure 3: Appendicitis Picture

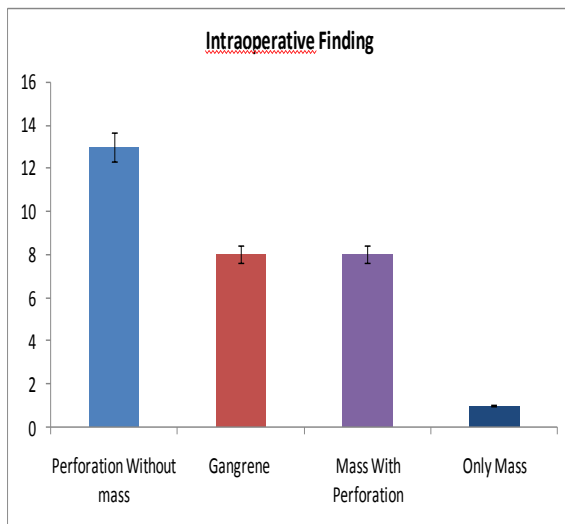


Figure 4: Shows Intra operative findings in Subjects

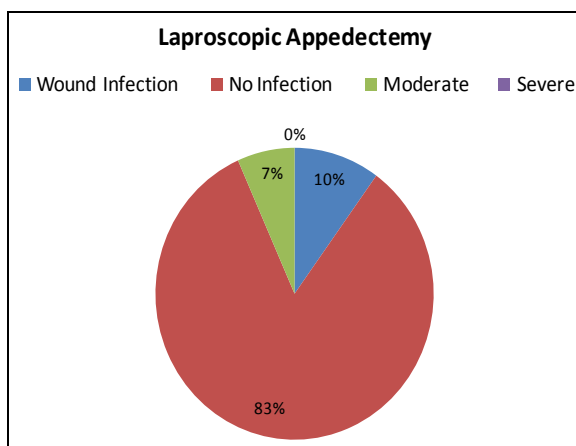


Figure 5: Shows Wound infection

DISCUSSION

Thirty patients underwent laparoscopic appendectomy for complicated appendicitis. Of the 30 patients, mass with

perforated appendix cases are 18, gangrenous appendix are 6, mass in right iliac fossa only one case. Post operation wound infection rate is very less, moderate wound infection is observed only in 4 cases (8%) and remaining 26 cases (92%) did not develop any wound infection.

Laparoscopic appendectomy gained lot of attention around the world. Laparoscopic appendectomy is very safe and effective and is excellent alternative for patients with acute appendicitis and wit its complications. Laparoscopy appendectomy is very widely available. Outcome measures primarily in terms of generalized peritonitis, wound infection, intra abdominal abscesses, fistula formation, stump appendicitis, port site hernia and adhesions leading to intestinal obstruction involved in the group were studied.

Present study comprises of 30 patients, of whom 9 patients presented with early mass and dense adhesions and none of the patients developed any complications like wound infection, intestinal obstruction during post operative and follow up period of three months. This was similar with PSP Senapathi et al who operated on appendicular mass 12 patients and generalized peritonitis 4 patients and outcome was without complications. Similar outcomes were also reported by BK Goh, LR Padankatti, R.Rai.

Laparoscopy initially was perfected by gynecologists. However, it became an integral part of general surgery in the mid-1980s, because it proved to be superior in the treatment of symptomatic cholelithiasis. Since then, surgeons have come up with an increasing number of procedures that can be performed by minimally invasive techniques. As such, laparoscopic appendectomy was described in 1983 by Semm.

Out of 30 cases 20 patients were presented with perforated appendix either at the base, tip or in the middle and 8 patients presented with gangrenous appendix and none of the patients had intra abdominal abscess and 2 patients with port site wound infection during the post operative period or during the 3 months follow up period. Frazee RC et al in his study, he reported that 5 of 19 patients with perforated appendix operated laparoscopically developed intra abdominal abscess and 2 (10%) patients developed wound infection. 15 gangrenous patients operated and 1 (7%) patient developed intra abdominal abscess. K Kathaouda et al reported 1 patient with intra abdominal abscess of 46 laparoscopic appendectomy cases and nil intra abdominal abscess patient in 60 perforated Patients. Pokala N et al had reported 6 cases of intra abdominal abscesses in 43 patients operated laparoscopically for gangrenous appendix.

Yao CC et al performed laparoscopic appendectomy in 10 patients with perforated appendix with local peritonitis and 15 cases of perforated appendix with diffuse peritonitis and 9 patients with appendicular abscesses. None of the patients had complications like peritonitis, adhesive intestinal obstruction or fistula formation and study correlates with our study.

Our study has close similarity with the study of Mohammed Saquib Mallik et al who operated upon 34 perforated, 12 gangrenous and 13 appendicular mass, total 59 and 4 (7.3%) patients developed port site infection. We have got similar results when compared with the Mohammed Saquib

study. We have studied 18 perforated (appendicular mass together with perforation 7), 6 gangrenous and 1 appendicular mass, total of 30 and we reported 2 (8%) patients with wound infection. Maria Manezes et al reported 15 (6%) cases of port site infection out of 250 cases who presented with appendicular perforation, abscesses and peritonitis. Stump appendicitis is also not seen in any one of our patients but which was reported and treated 1 each according to LK Shin and E Topal.

CONCLUSION

The study findings confirmed previous study results and clearly demonstrated superiority of laparoscopic appendectomy over open appendectomy, regardless of diagnosis appendicitis and severity of illness. On analyzing the data, we found satisfactory outcome with laparoscopic procedure in complicated appendicitis. Laparoscopic appendectomy has higher rates of success in complicated appendicitis like in early mass, perforated, gangrene appendicitis and with dense adhesions. Outcome parameters like peritonitis, fistula formation, intra abdominal abscesses, stump appendicitis and adhesive intestinal obstruction were nil except wound infection at the port site through which gangrenous and perforated appendix taken out which is of negligible significance. Our study certainly proved that every new emerging technology should be learned and practiced with dedication. The present study proved laparoscopic appendectomy is the best approach in complicated appendicitis.

ACKNOWLEDGEMENTS

Cooperation with Department of General Surgery, Maharajah's Institute of Medical Sciences, Nellimarla, Vizianagaram, Andhra Pradesh.

REFERENCES

1. D'Agostino J. Common abdominal emergencies in children. *Emergency*

- medicine clinics of North America. 2002; 20(1):139-53.
2. Philip M, Hemed E, Simeon S Variations in the Position and Length of the Vermiform Appendix in a Black Kenyan Population. *ISRN Anat.* 2014; 1(1):1-5.
 3. Flwers JL, Jacobs S, Cho E, Morton A, Rosenberger WF, Evans D, Imbembo AL, Bartlett ST. Comparison of open and laparoscopic live donor nephrectomy. *Annals of surgery.* 1997; 226(4):483.
 4. Tiwari MM, Reynoso JF, Tsang AW, Oleynikov D. Comparison of outcomes of laparoscopic and open appendectomy in management of uncomplicated and complicated appendicitis. *Annals of surgery.* 2011; 254(6):927-32.
 5. Kopelman Y, Lanzafame RJ, Kopelman D, Celik H, Cremins A, Jones KA, Harmanli O. Scientific papers. *J soc lapa sur.*; 17(2):171-360.
 6. Frutos MD, Abrisqueta J, Lujan J, Abellan I, Parrilla P. Randomized prospective study to compare laparoscopic appendectomy versus umbilical single-incision appendectomy. *A sur.* 2013; 257(3):413-8.
 7. Session I. Second International Congress of the European Association for Endoscopic Surgery (Em AES) Madrid, Spain, September 14-17, 1994 Oral Presentations. *Surg Endosc.* 1994; 8:935-74.
 8. Adhesions Cc, Polypropylene T. 17th International Congress of the European Association for Endoscopic Surgery (EAES) Prague, Czech Republic, 17-20 June 2009 Poster Presentations. *Surg Endosc.* 2010; 24:S62-156.
 9. Sarangi R, Mahajan K. Single-incision laparoscopic surgery (SILS): Current practice-based concerns. *The G R J.* 2012; 2(3):12-14.
 10. Meguerditchian AN, Prasil P, Cloutier R, Leclerc S, Péloquin J, Roy G. Laparoscopic appendectomy in children: a favorable alternative in simple and complicated appendicitis. *J peda sur.* 2002; 37(5):695-8.
 11. Graham NO, editor. Quality in health care: Theory, application, and evolution. Jones & Bartlett Learning; 1995; 22(5): 122-125.
 12. Khan N. Comparative Study between Laparoscopic Cholecystectomy vs Minimal Invasive Cholecystectomy 3-5 cm. *Ann. Pak. Inst. Med. Sci.* 2015; 11(3):119-23.
 13. Seamguardò Gs, Laparoscopic I. 2011 Scientific Session of the Society of American Gastrointestinal and Endoscopic Surgeons (SAGES) San Antonio, Texas, USA, 30 March-2 April 2011 Poster Presentations. *Surg Endosc.* 2011; 25:241-372.

How to cite this article: Rao BH, Srinivasarao RV. Study of laparoscopic appendicectomy in complicated appendicitis. *Int J Health Sci Res.* 2016; 6(12):41-46.
