

## Case Report

**Minimal Invasive Parasurgical Treatment in Recurrent Pilonidal Sinus**Jaiswal Ashwani Kumar<sup>1</sup>, Gupta Ajay Kumar<sup>2</sup>, chaturvedi Ashutosh<sup>3</sup>, Jaiswal Ruchi<sup>4</sup><sup>1</sup>Assistant Professor, Department of Shalya Tantra, Patanjali Bhartiya Ayurvedigyan Avum Anusandhan Sansthan, Haridwar, Uttarakhand-249402.<sup>2</sup>Associate Professor, PG Department of Shalya Tantra, Rishikul Campus (Haridwar) Uttarakhand Ayurved University, Uttarakhand.<sup>3</sup>Assistant Professor, Department of Panchakarma, Patanjali Bhartiya Ayurvedigyan Avum Anusandhan Sansthan, Haridwar, Uttarakhand-249402.<sup>4</sup>Internee, Rishikul Campus (Haridwar) Uttarakhand Ayurved University, Uttarakhand.

Corresponding Author: Jaiswal Ashwani Kumar

Received: 24/09/2016

Revised: 13/10/2016

Accepted: 15/10/2016

**ABSTRACT**

*Pilonidal sinus* is a common disease of the natal cleft in the sacrococcygeal region with weak hair accumulation occurring in the hair follicles, which can be chronic and undergo acute exacerbation. The patient presents with the complaints, which are characteristics of inflammation-a painful swelling, redness, local temperature raised or with a sinus discharge. In *Ayurvedic science Pilonidal sinus* is better correlated and treated as the *Nadi vrana*. *Acharya Sushruta* had explained *Shastra Chikitsa* with the intervention of *kshar sutra* as one of the treatment for *Nadi vrana*. This study elicits a case report of a recurrent *pilonidal sinus* treated by the intervention of *kshar sutra*, which cured and demolished the recurrence of the symptoms.

**Keywords:** *Pilonidal sinus, kshar sutra, Nadi vrana.*

**INTRODUCTION**

*Pilonidal* means nest of hair & is derived from the Latin words for hair (*pilus*) and nest (*nidus*).<sup>[1]</sup> The condition was first described by Herbert Mayo in 1833.<sup>[2]</sup> R.M. Hodges was the first to use the phrase *Pilonidal cyst* to describe the condition in 1880.<sup>[3]</sup> The incidence of *Pilonidal sinus* is approximately 26 / 100,000,<sup>[4]</sup> it is a benign disease that occurs in young adults in the age group of 15-30 years after puberty when sex hormones are known to affect pilosebaceous glands & change healthy body hair growth.<sup>[5]</sup> A *Pilonidal sinus* is a cyst or abscess near or on the natal cleft of the buttocks that often contains hair & skin debris. A *Pilonidal sinus* is usually painful but without draining, the patient might not feel pain. The etiology and pathogenesis of

*Pilonidal sinus* are not clear although the disease is thought to be related to the accumulation of weak and lifeless hair in the intergluteal region. Over time, foreign body reaction occurs, causing abscess and sinus formation. Obesity, trauma, local irritation and a sedentary life style are usually associated with *pilonidal sinus*. However collection of the lifeless hair depends on the anatomy of the intergluteal area and accompanying risk factors can lead to inadequate surgery and subsequent recurrence. The management of *Pilonidal sinus* is variable, contentious and problematic. A principle of treatment requires eradication of the sinus tract, complete healing & prevention of reoccurrence. Several techniques such as cryosurgery, Z-plasty procedure, lancing

under local anesthesia, vacuum assisted closure, excision with secondary healing, excision with primary closure, local flap surgery & Boschem procedure have been described by various authors.

In *Ayurveda* texts, no direct reference to *Pilonidal sinus* as a disease entity is found. However, *Acharya Sushruta* had described that hair can be a root cause [6] for the formation of a sinus, and also mentioned various methods of management including *agnikarma* and *kshar sutra*. [7]

### CASE REPORT

A 25 years old male reported to the surgery O.P.D. at *Rishikul Campus,*

*Uttarakhand Ayurveda University, Haridwar, Uttarakhand* with complaints of pus discharge from a wound over an operated site along with pain and discomfort in March 2015. Patient was apparently alright 5 years back. Gradually developed swelling around natal cleft and after few days pain and pus discharge occurs through this region. Patient takes some allopathic medicine and it subsides in few days. After 6 months again swellings occur and these time patients go to allopathic surgeon. Surgeon performed *Z-Plasty procedure* for *Pilonidal sinus* in 2011. The disease reoccurred after 4 years in 2015.

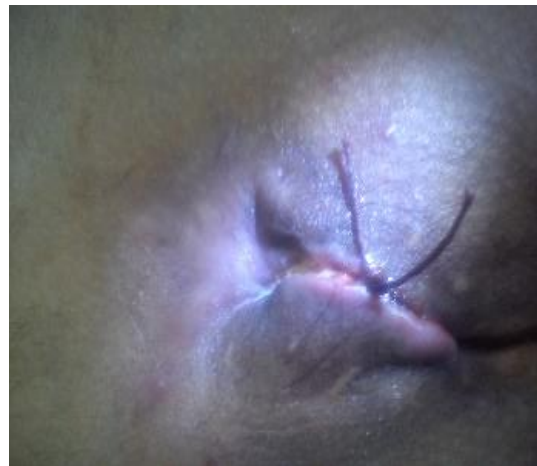
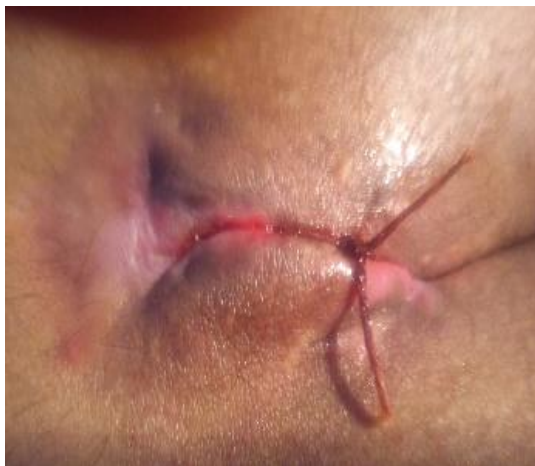

Figure A & B Image Showing the Pilonidal Sinus during the healing

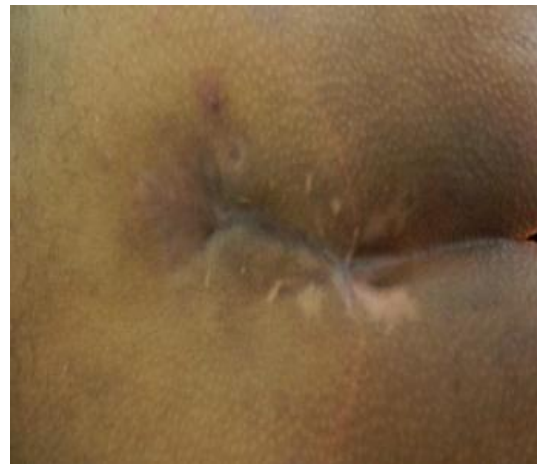
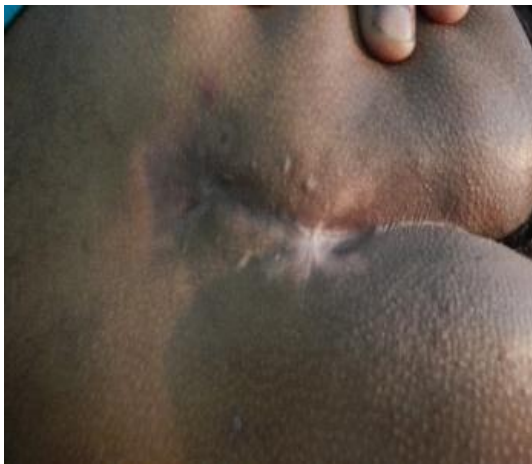
Figure C & D Image Showing the Pilonidal Sinus After the healing

Before planning treatment Patient was assessed for fitness for anaesthesia and surgery. After giving spinal anaesthesia debridement of the Pilonidal tract is done with scoop. Hairs and unhealthy granulation

tissue was removed through the opening on skin. The opening of the skin was incised as the scoop can go inside and tract was cleaned with normal saline. Probing done through opening and tract traced till its blind

end and another opening was made over the skin up to the tip of the probe. Probe removed through another opening after feeding of *kshar sutra* and *kshar sutra* ligated appropriately. Patient was discharged from hospital on next day after operation. *Kshar sutra* was changed on every week by Railroad technique [8] until “cut through” of the tract.

## DISCUSSION

According to *Ayurveda* the action of *kshar sutra* is thought to be due to its healing and cleansing effect in the area where it is applied. The *kshar sutra* acted as good drainage for the wound. *Kshar sutra* have alkaline pH so it posses desloughing property. Collectively *kshar sutra* acts as simultaneous cutting and healing procedure. So the healing was good because no collection remain in the wound site. The pain after ligation of *kshar sutra* was bearable as the patient, who is working had not taken a break for this reason. So this is ambulatory method and patient need not take a leave for long period. No side effects or complications were noted during the study. After cut through of the tract, healing of the wound site is done properly & recurrence is not noted.

## CONCLUSION

Minimum tissue loss is seen in comparison to the other surgery. Minimal bleeding occurs & there is no need to put huge dressings. In ancient time *Acharya*

*Sushruta* mention *Kshar sutra* therapy in *Nadivrana chikitsa*. In this case study we also seen *Kshar sutra* is very efficient method for recurrence of *Pilonidal sinus*.

## REFERENCES

1. Gray's Anatomy Williams P.L, 38<sup>th</sup> Ed. ELBS, 1995.
2. Maurice BA, Greenwood RK. A conservative treatment of Sacrococcygeal Pilonidal Sinus. Br Journal of Surgery 1964; 51 :510-12
3. Hodges R.M. Pilonidal sinus. Boston Med Surg j 1880; 103: 485-586.
4. Prince ML, Griffiths WAD. Normal body hair: a review. Clin Exp Dermatol 1985, 10: 87-97.
5. Pilonidal disease, Origin from follicles of hairs and results of follicle removal as treatment, John Bascon, 1975.
6. Acharya Sushruta, Sushruta Samhita; Ayurveda - Tattva - Sandipika Hindi commentary; Edited by Kaviraja Ambikadutta Shastri; Chaukhambha Sanskrit Sansthan, Varanasi, Edition; Reprint 2008; NidhanSthaana-10
7. Acharya Sushruta, Sushruta Samhita; Ayurveda - Tattva - Sandipika Hindi commentary; Edited by Kaviraja Ambikadutta Shastri; Chaukhambha Sanskrit Sansthan, Varanasi, Edition; Reprint 2008; ChikitsaSthaana-17.
8. Gupta Rajesh comparative study of the effect of modified kshar sutra with standard Ksharsutra in the treatment of fistula-in-ano. International Ayurvedic Medical Journal. Sept-Oct 2014; 2(5) 649-658. Available from : iamj.in

How to cite this article: Jaiswal AK, Gupta AK, Chaturvedi A et al. Minimal invasive parasurgical treatment in recurrent pilonidal sinus. Int J Health Sci Res. 2016; 6(11):327-329.

\*\*\*\*\*