

Original Research Article

A Clinico-Morphological Spectrum of Nephrectomy Specimens - An Experience from a Tertiary Care Hospital

Kotta Devender Reddy¹, Sri Lakshmi Gollapalli², Chougani Sujitha³, Shivalalitha Sidagam³, Amanulla Khan Mohammed³, Archana Bommana⁴

¹Associate Professor, ²Assistant Professor, ³Post Graduate, ⁴Senior Resident, Department of Pathology, Osmania Medical College, Hyderabad, Telangana State, India.

Corresponding Author: Kotta Devender Reddy

Received: 30/09/2016

Revised: 15/10/2016

Accepted: 01/11/2016

ABSTRACT

Background: In recent years, there is an increase in the number of nephrectomies done as there is an extensive use of imaging techniques. Nephrectomy is a standard therapeutic urological procedure for irreversibly damaged non functioning kidneys involved by different benign pathological conditions and renal malignancies.

Aim: This study analyzed various kidney diseases histopathologically from nephrectomy specimens received in the department of pathology in our institute.

Methodology: This is a retrospective study conducted in Osmania General Hospital for duration of two years from August 2014 to July 2016.

Results: Seventy seven cases of nephrectomy specimens were received in the department of histopathology. Out of 77 patients, 33 were females and 44 were males. Most common age group was in 4th decade. The final diagnosis was arrived at after correlating the clinical features, gross, microscopic findings, immunohistochemistry wherever required. The spectrum of pathological lesions included both non-neoplastic and neoplastic lesions.

Conclusion: Chronic pyelonephritis was the most common lesion of all nephrectomies studied. Renal cell carcinoma was the most common malignant lesion encountered in our study. Other rare malignant lesions like sarcomatoid renal cell carcinoma, squamous cell carcinoma, PNET were studied. Angiomyolipoma and oncocytoma are the benign neoplastic lesions seen in our study.

Keywords: Nephrectomy, Pyelonephritis, Renal cell carcinoma, Angiomyolipoma.

INTRODUCTION

Kidneys are one of the major organs of the human body that serve several essential functions. Their main function is to regulate the balance of electrolytes in the blood, along with maintaining pH homeostasis. They also remove waste products of metabolism from blood and produce erythropoietin to maintain hematopoiesis and an important enzyme, renin to maintain blood pressure.

Kidneys are affected by various non-neoplastic and neoplastic pathological processes. Common clinical conditions

involving the kidney include the nephritic and nephrotic syndromes, renal cysts, acute kidney injury, chronic kidney disease, urinary tract infection, nephrolithiasis, urinary tract obstruction and various cancers of the kidney. ⁽¹⁾ Because of widespread use of imaging, increased number of renal lesions is being discovered. These renal conditions can be managed medically or surgically. Surgical removal of the kidney is known as nephrectomy.

Nephrectomy is the standard surgical procedure performed in irreversible kidney damage and in the case of renal

malignancies. Simple nephrectomy is indicated in patients with symptomatic chronic infection, obstruction, calculus disease or severe traumatic injury that caused irreversible renal damage and also to treat renovascular hypertension. Radical nephrectomy is standard treatment with localized renal carcinoma with a normal contralateral kidney. (2)

Aim:

- To study histopathological spectrum of various lesions in nephrectomy specimens.
- To analyze the frequency of non-neoplastic and neoplastic renal lesions.
- To assess age and sex wise distribution of various renal lesions.

MATERIALS AND METHODS

This is a retrospective study carried out in the department of Pathology in collaboration with department of Urology in

our institute. Seventy seven consecutive nephrectomy specimens received during the period from August 2014 to July 2016 were included in the study. The indications for the nephrectomy and other available relevant clinical information were recorded. The weight, size, capsule and other changes recorded in the grossing sheet were analysed. All the specimens were fixed in 10% buffered formalin for 24-48 hours and processed. Besides the routine Hematoxylin and Eosin stain, special stains and IHC were done whenever necessary. The histopathological slides were reviewed and the microscopic findings were studied and correlated with the clinical data. The results were compiled and analysed.

RESULTS

In the present study 77 cases were included. Out of 77 cases, age of the patient ranged from 4 years to 63 years.

Table 1: Age and sex wise distribution of renal lesions

Age (yrs)	<10	11-20	21-30	31-40	41-50	51-60	>61	Total	%
Female	3	2	4	6	9	6	3	33	42.8%
Male	6	3	7	8	12	4	4	44	57.2%
Total	9	5	11	14	21	10	7	77	100%
%	11.6%	6.4%	14.2%	18.1%	27.2%	12.9%	11%	100%	

In this study, most common age group underwent nephrectomy were in 4th decade. Male to female ratio was 1.3.

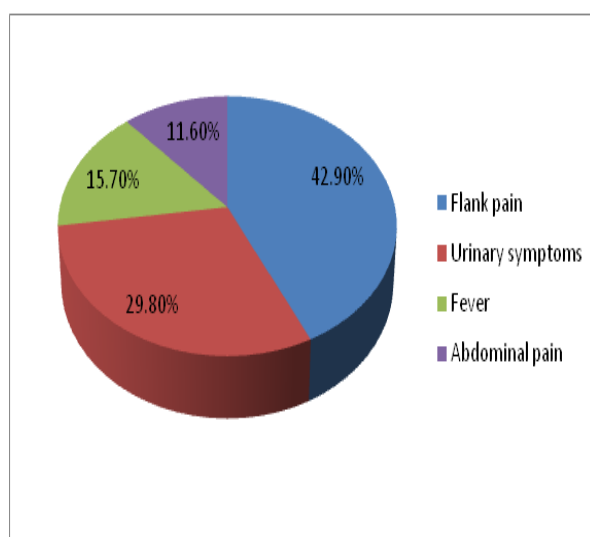


Fig: 1 Presenting complaints

Table 2: Histopathological diagnosis of various renal lesions

Histopathological diagnosis	No. of cases	Percentage
NON-NEOPLASTIC		
Chronic pyelonephritis	33	42.9%
Hydronephrosis with CPN	10	12.9%
Tuberculous pyelonephritis	06	7.8%
Xanthogranulomatous pyelonephritis	08	10.4%
Granulomatous interstitial nephritis	03	3.9%
Glomerulonephritis	02	2.6%
Total	62	80.5%
NEOPLASTIC		
Benign		
Angiomyolipoma	01	1.3%
Oncocytoma	01	1.3%
Malignant		
Renal cell carcinoma	08	10.4%
Squamous cell carcinoma	01	1.3%
Wilms tumor	03	3.9%
PNET	01	1.3%
Total	15	19.5%

In patients who underwent nephrectomy, most common clinical presentation was flank pain, followed by hematuria, burning micturition and

increased frequency of micturition, fever. In paediatric age group, abdominal mass is the most common complaint.

Table 3: Histological variants of renal cell carcinoma

Histopathological variant	No. of cases	Percentage
Clear cell	05	71.4%
Chromophobe	01	14.2%
Sarcomatoid	01	14.2%

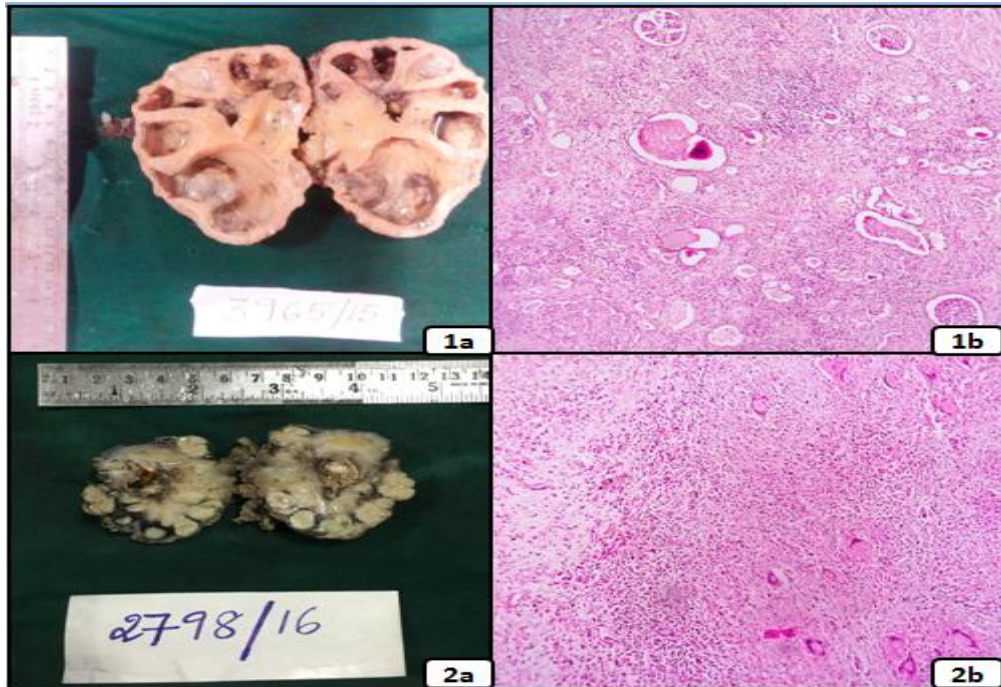


Fig 1a, 1b: Gross and photomicrograph (H&E, 10X) of Chronic pyelonephritis.
 Fig 2a, 2b: Gross and photomicrograph (H&E, 10X) of Tuberculous pyelonephritis.

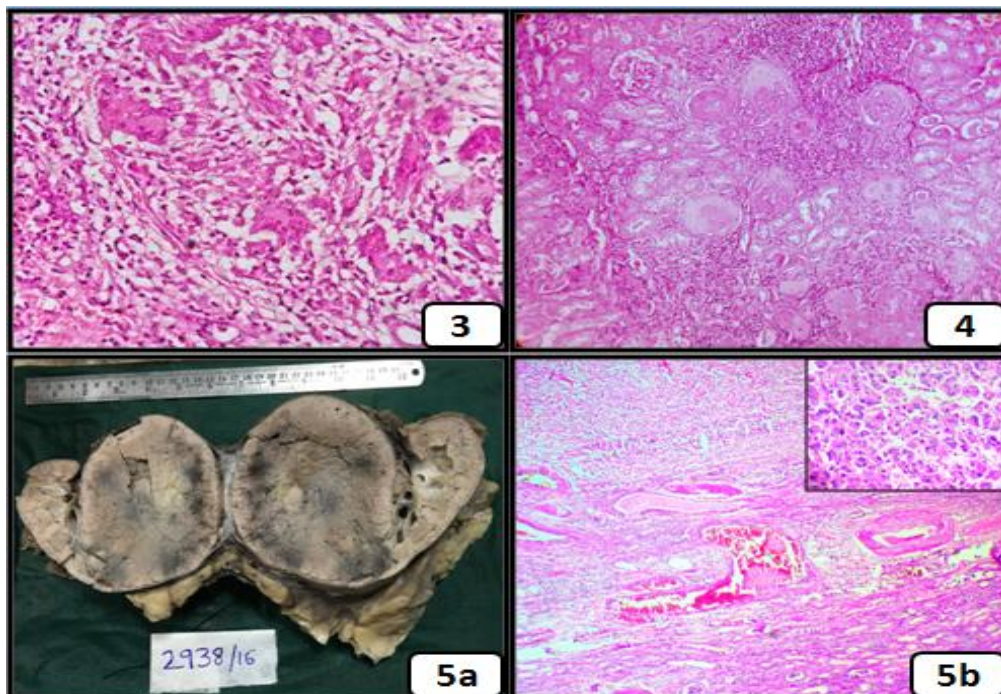


Fig 3: Photomicrograph (H&E, 10X) of Xanthogranulomatous pyelonephritis.
 Fig 4: Photomicrograph (H&E, 10X) of Chronic glomerulonephritis.
 Fig 5a, 5b : Gross and photomicrograph (H&E, 10X; Inset, 40X) of renal oncocytoma.

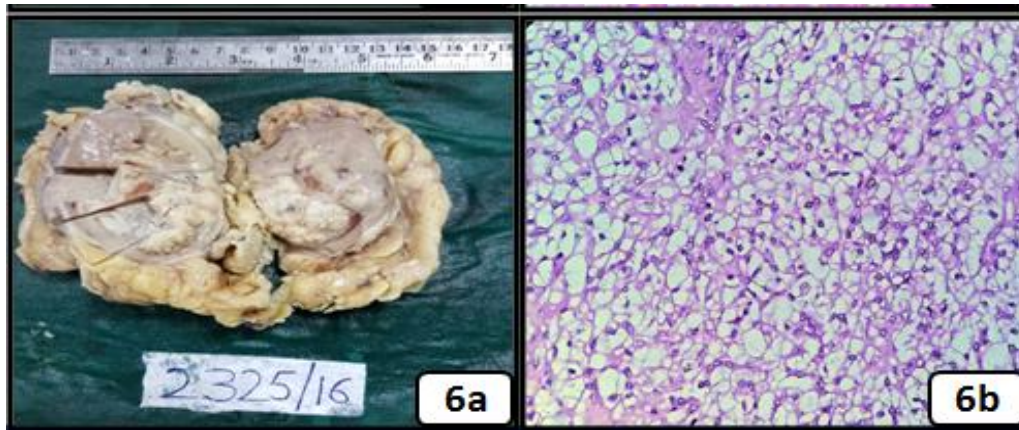


Fig. 6a, 6b: Gross and Photomicrograph (H&E, 10X) of renal clear cell carcinoma

Fig 7: Microphotograph(H&E, 10X) of angiomyolipoma cell

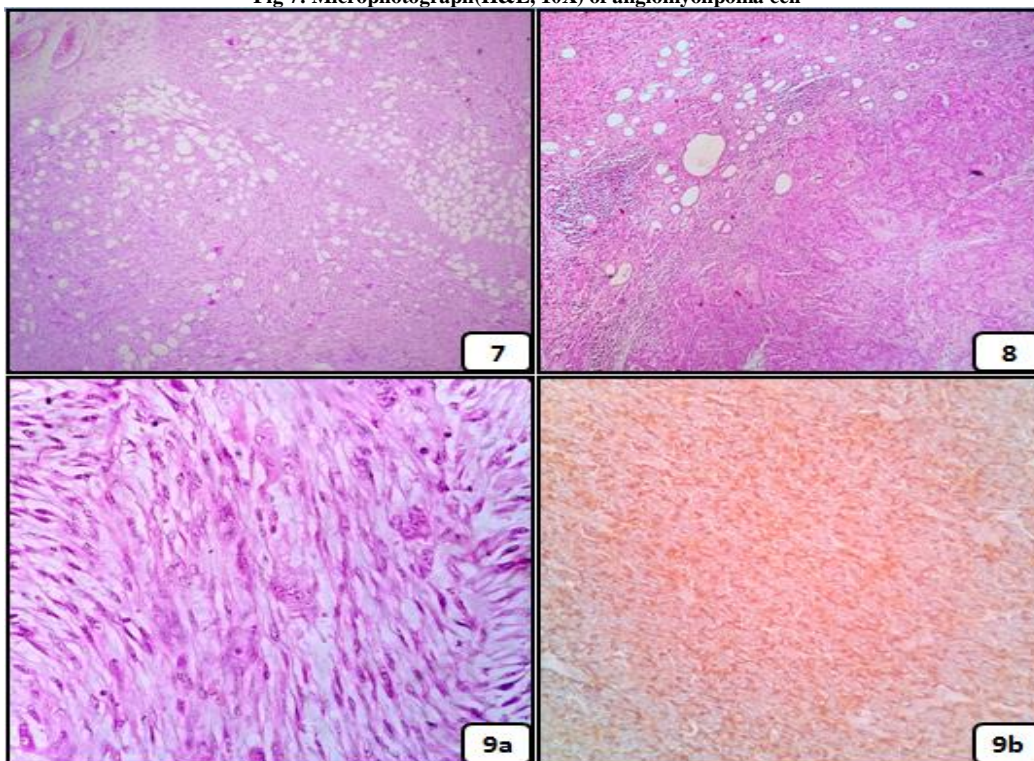


Fig 7: Photomicrograph (H&E,10X) of Angiomyolipoma.

Fig 8: Photomicrograph (H&E,10X) of Squamous cell carcinoma.

Fig 9a: Photomicrograph (H&E,10X) of Sarcomatoid renal cell carcinoma.

9b: Photomicrograph (IHC, 10X) of Sarcomatoid renal cell carcinoma. Tumor cells showing cytoplasmic and membranous immunoreactivity.

DISCUSSION

In the present study 77 nephrectomy specimens were analyzed. In this study highest number of cases included was in the age group of 4th decade followed by 3rd decade. Male to female ratio of all the nephrectomies was 1.3. Ashima N Amin et al (2015),⁽³⁾ Lathif et al (2011),⁽⁴⁾ Badmus

T et al (2008)⁽⁵⁾ in their respective studies concluded that the male to female ratio was 1.3:1, 9:1, 2:1. In Rafiq et al study, there was a slight female predominance with a M: F ratio 2.3:11.⁽⁶⁾

In our study, most common clinical presentation was flank pain followed by urinary symptoms. This finding is similar to

study by Aiffa Aiman.et.al, Divyashree B.N.et al and Mohammad Rafique Zaki.et.al. (7,8,9)

In our study, non-neoplastic conditions forms majority of the case load. Chronic Pyelonephritis (CPN) is the most common non-neoplastic lesion found in all age groups accounting for about 42.9% of all nephrectomies. This finding is similar to Ashima N Amin et al (2015), Divyashree et al (2014). (3,8)

Table 4: Comparison of our study with other studies

Studies	Non-neoplastic	Neoplastic
Shaila et al (2015) (10)	77.6%	22.64%
Ashima N Amin et al (2015) (3)	54.2%	45.7%
Divyashree B.N et al (2015) (8)	72.41%	27.59%
Mahesh Kumar U et al (2012) (11)	45.4%	54.6%

In the present study, non obstructive pyelonephritis was found to be more common as compared to obstructive chronic pyelonephritis. There were 10 cases of Hydronephrosis with Chronic pyelonephritis in this study. Most of these cases were due to vesicoureteric reflux followed by ureteric stricture. Prasanna. L. C. studied 30 cases of hydronephrosis in which ureteric calculus was the common cause. (12)

Out of 77 cases, 6 (7.7%) cases were diagnosed as tuberculous pyelonephritis in our study. Ibrahim Fathi Ghalayini.et.al reported 9 (2.1%) out of 423 cases and 5 (0.8%) cases out of 646 nephrectomies found in a Beisland et al study were tuberculous pyelonephritis cases. (13,14) We found 8 (10.3%) cases out of 77 nephrectomy specimens were having xanthogranulomatous pyelonephritis as underlying pathology. Our findings are comparable with Ibrahim Fathi Ghalayini et al study. (13) Glomerulonephritis accounts for 3.8% of total cases.

Neoplastic lesions constituted 19.5% of all renal lesions with a male to female ratio of 1.8:1. Among the neoplastic lesions, 86.4% were malignant and 13.3% were benign. Under neoplastic conditions we encountered, renal cell carcinoma was the most common, comprising of 10.4% (8 cases) of all nephrectomies followed by 3 cases (3.9%) of wilm's tumor. This was

similar to findings of Aiffa Aiman et al, Mohammed Rafique et al and Shaila et al studies. (7,9,10) Histological types of renal cell carcinoma in our study were 5 cases of clear cell type, chromophobe and sarcomatoid types 1 case each. This finding is similar to Mahesh kumar et al observation. (11) In our study, out of 3 cases of Wilm's tumor, histologically 2 cases had triphasic lineage composed of blastemal, epithelial, mesenchymal components and 1 case had biphasic lineage with mesenchymal and blastemal elements.

Other rare neoplastic lesions were squamous cell carcinoma and PNET accounting for 1.3% each. Squamous cell carcinoma originated from the urothelial lining of the renal pelvis and involved the renal parenchyma at the time of detection. Ureters and bladder cuff were negative for tumor involvement or dysplasia, thus confirming their localization to the kidney. Peripheral primitive neuroectodermal tumor (PNET) is primarily a tumor of soft tissue, occasionally localized in the kidney. (15) PNET case showed morphology of small round blue cell tumor and the diagnosis was confirmed by IHC for CD99.

Angiomyolipoma and oncocytoma are the benign neoplastic lesions encountered in our study and the incidence of angiomyolipoma is 1.3% and it is comparable with that of Ashima N Amin et al and Nusrat Bashir et al studies. (3,16) Oncocytoma incidence is 1.3% and it is similar to shaila et al and Nusrat Bashir et al studies. (10,16)

CONCLUSION

Nephrectomy is the standard surgical procedure for many neoplastic lesions of the kidney and in case of non-functioning kidney. In our setup, majority of lesions are non-neoplastic. Chronic pyelonephritis is the most common non-neoplastic lesion and among neoplastic lesions, renal cell carcinoma is most common. Other benign and malignant neoplastic lesions are comparatively rare.

REFERENCES

1. Cotran, RS S.; Kumar, Vinay; Fausto, Nelson; Robbins, Stanley L.; Abbas, Abul K. (2005). *Robbins and Cotran pathologic basis of disease. St. Louis, MO: Elsevier Saunders*. ISBN 0-7216-0187-1.
2. Truong LD, Shen SS, Park MH, Krishnan B. diagnosing nonneoplastic lesions in nephrectomy specimens. *Arch Pathol Lab Med* 2009; 133: 189-200.
3. Ashima N Amin, Pushpalatha Pai, Krishnaraj Upadhyaya. A Histopathological spectrum of nephrectomy specimens in a tertiary hospital in southern India. *Int J Biol Med Res.*2015; 6(3):5173-5178.
4. Latif F, Mubarak M, Kazi JI. Histopathological characteristics of adult renal tumors: a preliminary report. *J Pak Med Assoc* 2011; 61:224-8.
5. Badmus TA, Salako AA, Sanusi AA, Arogunta A, Oseni GO, Yusuf BM. Adult nephrectomy: Our experience at Ile-Ife. *Niger J Clin Pract* 2008; 11(2):121-6.
6. Rafique M. Nephrectomy: Indications, complications and mortality in 154 consecutive patients *Journ of Pak Med Assoc* 2007; 5:35-8.
7. Aiman A, Singh K, Yasir M. Histopathological spectrum of lesions in nephrectomy specimens: A five year experience in a tertiary care hospital. *J Sci Soc.* 2013; 40(3): 148-154.
8. Divyashree B.N, Kusuma venkatesh, Madhusudhan H.R, Hanumantha Raju B.K. Pathological spectrum of non-neoplastic diseases in the nephrectomy specimens. *J of Evidence Based Med and Healthcare* 2014; 1(15):1909-1920.
9. Zaki M R, Ghazanfar A, Asif K. Nephrectomy for non-traumatic benign renal diseases: Its indications and outcomes in a developing country. *Pak J Med Health Sci.* 2012; 6(1):216-9.
10. Shaila, Nityananda B.S, Tamil Arasi. Spectrum of lesions in nephrectomy specimens in tertiary care hospital. *Journal of Evolution of Medical and Dental sciences* 2015; 4(73):12714 - 12726.
11. Mahesh Kumar U., Yelikar BR, Girija Patil, Mahesh H Karigoudar, Pankaj Pande and Patil SB. Spectrum of Histopathological lesions in Nephrectomy specimens - A two year study in a tertiary care hospital; *International Journal of Research in Pharmaceutical and Biomedical Sciences*; Vol. 3 (4) Oct - Dec 2012;1787-90
12. Prasanna L. C, Nataraj K.M. Unilateral hydronephrosis- A clinical study. *Int J Cur Res Rev.* 2013; 5(9):51-55.
13. Ghalayini I F. Pathological spectrum of nephrectomies in a general Hospital. *Asian J Surg.* 2002; 25(2): 163-9.
14. Beisland C, Medby PC, Sander S, Beisland HO. Nephrectomy indications, complications and post-operative mortality in 646 consecutive patients. *Eur Urol* 2000; 37:58-64.
15. Gudbjartsson T, Hardarson S, Petursdottir V, Thoroddsen A, Magnusson J, Einarsson GV. Histological subtyping and nuclear grading of renal cell carcinoma and their implications for survival: a retrospective nation-wide study of 629 patients. *Eur Urol* 2005; 48: 593-600.
16. Nusrat Bashir, Yasir Bashir, Parveen Shah, Nazia Bhat, Othman Salim, Nuzhat Samoon. Histopathological study of renal tumors in resected nephrectomy specimens - An experience from tertiary care centre. *National Journal of Medical Research* 2015; 5(1):25-29.

How to cite this article: Reddy KD, Gollapalli SL, Chougani S et al. A clinico-morphological spectrum of nephrectomy specimens - an experience from a tertiary care hospital. *Int J Health Sci Res.* 2016; 6(11):67-72.
