

*Case Report***Tonsillar Actinomycosis - A Case Report**Wasim M Khatib¹, Sunil V. Jagtap², Pankti M Patel³, Tasneem V. Bisht³, Dhirajkumar B. Shukla¹¹Assistant Professor, ²Professor, ³Assistant Lecturer,
Department of Pathology, KIMS, Karad, India.

Corresponding Author: Wasim M Khatib

*Received: 26/07/2015**Revised: 20/08/2015**Accepted: 24/08/2015***ABSTRACT**

Actinomycetes are filamentous branched bacteria and live as commensal organisms within the oral cavity. When present in tonsillar tissue, they may present with recurrent tonsillitis along with complaints of sore throat, fever. We present a case of a 42 year old male who presented to ENT OPD with complaints of sore throat, fever, painful deglutition and bilateral tonsillar enlargement since 2 months. Histopathology revealed actinomycosis within tonsillar tissue. This case emphasizes the accurate diagnosis as treatment protocols are different for individual lesions.

Key word: Actinomycosis, tonsil, tonsillitis.

INTRODUCTION

Actinomycosis is a chronic suppurative inflammation of the organs caused by anaerobic, gram positive, branching, filamentous bacteria which are commensal in the oral cavity. [1] Till date six actinomyces species are known to be pathogenic to humans namely *A.israelii*, *A.naeslundii*, *A.odontolyticus*, *A.viscosus*, *A.meyeri* and *A.gerecseriae*. [2] It may become invasive and gain access subcutaneous tissue and lead to discharging lesions. [3]

Within oral cavity actinomycetes species exist in plaque deposits over the teeth, gingival crevices and tonsillar crypts. [4]

According to few studies, actinomycetes have a role in recurrent tonsillitis and tonsillar hypertrophy. [5-8] This

case highlights the clinical importance of recognizing the organism and accurate diagnosis as treatment differs.

CASE REPORT

A 42 year old male presented to the ENT OPD with complaints of sore throat, fever, pain during deglutition, for the past 2 months. He was a chronic tobacco chewer and occasional drinker. On examination he was pale and had low grade fever. Rests of the vitals were within normal limits. On local examination he had bilateral enlargement of the palatine tonsils.

Locally, both the tonsils were inflamed and showed surface exudate. He gave a history of similar complaints on three different occasions within the past one and half years. He also gave history of dental caries. Bilateral tonsillectomy was

performed and the specimen was sent for histopathological examination. Grossly, tonsils were enlarged and thick copious exudate within the crypts was noted. Microscopy revealed features of chronic tonsillitis showing stratified squamous epithelium and exaggerated lymphoid hyperplasia. Also noted were actinomyces colonies (Figure 1, Figure 2). Periodic Acid Schiff staining confirmed presence of actinomyces.

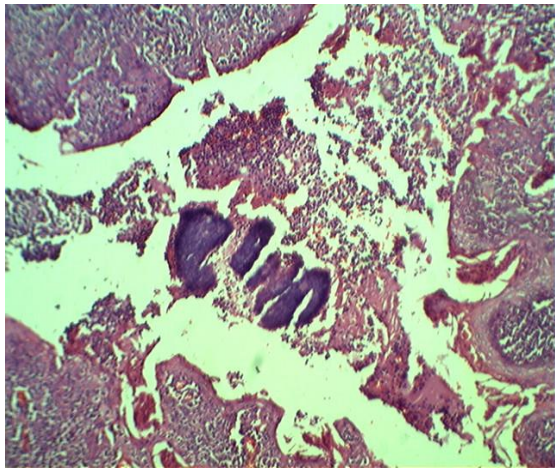


Figure 1: Photomicrograph showing Actinomycetes in a tonsillar crypt along with inflammatory infiltrate. (H&E, 100x)

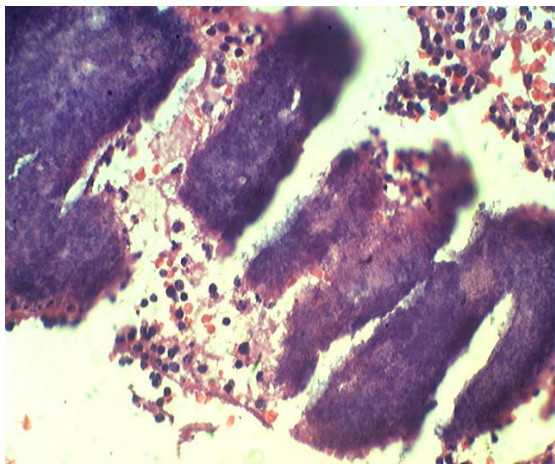


Figure 2: Photomicrograph showing high power image of Actinomycetes with inflammatory infiltrate. (H&E, 400x)

DISCUSSION

Human actinomycosis is mainly caused by *A. israelii*. Actinomycoses are common bacteria found in oral cavity and

palatine tonsils and are found in 2-3% of subjects. [3,8,9] Actinomycosis commonly occurs in the 4th to 6th decades and commonly involves cervicofacial, thoracic, abdominopelvic region and central nervous system. [3] Within the cervicofacial region invasion of actinomyces is precipitated by factors such as dental caries, trauma and periodontitis.

Actinomycosis has been reported in oral cavity, mandible, maxilla, paranasal sinuses, salivary glands, and eye, ear and neck areas. [10] Generally with long standing effects actinomycosis is characterized by paramandibular draining sinus tract, trismus and woody fibrosis.

Actinomyces are anaerobic filamentous, branched bacteria which are also commensal organisms in the oral cavity. Diagnosis of actinomycosis can be done by positive cultures, presence of sulphur granules in the discharge or on light microscopy. [11] However cultures are difficult to obtain and histopathological identification is the gold standard. Clinically, the patients present with varied symptoms ranging from sore throat, fever, discharging sinuses and hypertrophied inflamed tonsils, etc. Such patients generally give history of recurrent tonsillitis. According to studies, actinomycosis leading to massive tonsillar enlargement can mimic a neoplasm. [11]

In our case, patient presented with sore throat, fever and bilateral enlargement of tonsils with inflammation. Microscopy revealed actinomyces. The patient was maintained on long course of intravenous and oral antibiotics and was responding on follow up.

Actinomycosis can mimic other oropharyngeal malignancies and hence if diagnosis is missed, appropriate treatment is not instituted and patient care is hampered.

Hence, accurate diagnosis is imperative so that proper treatment

protocols are followed for eradication of the disease.

CONCLUSION

Actinomycosis is an infection which can affect the tonsillar region. Appropriate treatment is necessary for eradication and hence, proper microscopic examination and diagnosis is of prime importance.

REFERENCES

1. Schwartz HC, Wilson MC, Cervicofacial actinomycosis following orthognathic surgery: report of 2 cases. *J Oral Maxillofac Surg* 2001;59:447-9.
2. Smego RA Jr, Foglia G. Actinomycosis. *Clin Infect Dis* 1998;26:1255-61.
3. Bhargava D, Bhusnurmath B, Sundaram KR, Raman R, Al Okbi HM, Al Abri R, et al. Tonsillar actinomycosis: a clinicopathological study. *Acta Trop* 2001;80:163-8.
4. Aydin A, Erkilic S, Bayazit YA, Kocer NE, Ozer E, Kanlikama M: Relation actinomycosis and histopathological and clinical features of the palatine tonsils; a comparative study between adult and pediatric patients. *Rev Laryngol OtolRhinol* 126:95-98, 2005.
5. Ozgursoy OB, K emal O, Saatci MR, *et al.* Actinomycosis in the etiology of recurrent tonsillitis and obstructive tonsillar hypertrophy: answer from a histopathologic point of view. *J Otolaryngol Head Neck Surg* 2008; 37:865–9.
6. Pransky SM, Feldman JI, Kearns DB, *et al.* Actinomycosis in obstructive tonsillar hypertrophy and recurrent tonsillitis. *Arch Otolaryngol Head Neck Surg* 1991;117: 883–5.
7. Van Lierop AC, Prescott CA, Sinclair-Smith CC . An investigation of the significance of Actinomycosis in tonsil disease. *Int J Pediatr Otorhinolaryngol* 2007;71:1883–8.
8. Gaffney R, Harrison M, Walsh M, et al. The incidence and role of actinomyces in recurrent acute tonsillitis. *Clin Otolaryngol Allied Sci* 1993;18:268–71.
9. Assimakopoulos D, Vafiadis M, Askitis P, et al. The incidence of Actinomyces Israeli colonization in tonsillar tissue. A histopathological study. *Rev Stomatol Chir Maxillofac* 1992;93:122-6.
10. Hata T, Fukuda M, Hosoda M: Actinomycosis of submandibular gland region with salivary stone in center of gruse; report of a case. *J Jpn Stomatol Soc* 46:76-79,1997.
11. Mohanty S. Actinomycosis of faucial tonsil masquerading as oropharyngeal malignancy. *Indian J Otolaryngol Head Neck Surg* 2006;58:82–4.

How to cite this article: Khatib WM, Jagtap SV, Patel PM et al. Tonsillar actinomycosis – A case report. *Int J Health Sci Res.* 2015; 5(9):607-609.
