

Case Report

Osteosarcoma of Jaw: A Rare Case Report

Kuldeep Singh¹, Rita Kumara², Priya Gupta²¹Professor, ²Senior Resident,
Department of Pathology, Government Medical College, Jammu.

Corresponding Author: Priya Gupta

*Received: 08/07/2015**Revised: 22/08/2015**Accepted: 27/08/2015*

ABSTRACT

Osteosarcoma of the jaw is a relatively rare tumour comprising of about 8% of all cases. We report a case of osteosarcoma of the maxilla in a 13 year old girl diagnosed on fine needle aspiration cytology and discuss in detail the cytological and histological features of this tumour.

Keywords: osteosarcoma, Fine needle aspiration, maxilla.

INTRODUCTION

Osteosarcoma refers to a group of malignant neoplasms of mesenchymal tissue in which there is histopathological evidence of osteogenic differentiation. [1] Evidence of direct osteoid formation by neoplastic cells is considered to be essential criterion for its diagnosis. [2] It is usually found in long bones followed by craniofacial region and pelvis. About 8% of all cases occur in the craniofacial region. [3]

The tumor shows a discrete predominance in men and affects all ages from children to elderly. The highest prevalence is observed during second decade of life which coincides with the period of maximal growth and the tumor most commonly occurs in long bones. A second peak is observed in adults above the age of fifty with the tumor involving mostly the axial skeleton and flat bones. [4]

Osteosarcoma of the jaw occurs in third and fourth decades of life. Males

slightly outnumber females. Mandibular lesions are located in the body, symphysis, angle or ramus while maxillary lesions most often involve alveolar ridge, antrum, sinus floor and palate. [5]

The main clinical features of osteosarcoma of jaw are pain, swelling of bone and soft tissue, tooth bulging and dislocation, lack of healing and swelling at the site of tooth extraction, trismus, hypoesthesia or paresthesia in case of mandibular tumors and nasal obstruction in maxillary tumors. [4]

Radiological features may be mixed radiolucent and radio opaque lesion, periodontal ligament widening, radio opaque mass with moth eaten appearance, codman triangle and sunburst appearance. [6] Treatment of osteosarcoma of jaw is radical or conservative surgery followed by radio or chemotherapy. Early detection of the tumor and early resection are keys to higher survival. Due to non specific features the

diagnosis of osteosarcoma of jaw can be delayed or even misdiagnosed specially for inflammatory pathology. [2, 7]

Fine needle aspiration cytology is becoming popular in diagnosis of bone tumors as it is rapid, easy and fairly accurate. We report a rare case of osteosarcoma of maxilla in a young female which was suspected on fine needle aspiration cytology and discuss in detail the cytological and histological aspects of this tumor.

CASE REPORT

A thirteen year old female reported to the department of pathology for fine needle aspiration cytology of swelling over right side of face. She had a history of tooth extraction twenty days back which was followed by gradually increasing swelling which was evident extraorally from one week. It was associated with pain continuous in nature.

General physical and systemic examination of the patient was normal. On extraoral examination, there was facial asymmetry caused by swelling in the right maxillary region. Swelling measured 3X2 cm in size, was fixed, hard in consistency and tender. Intraoral examination showed maxillary swelling involving the vestibular and palatine region on the right side extending from 1st molar to ramus. Overlying mucosa was normal. CT scan showed a right sided expansile maxillary tumor with calcification causing destruction of the cortex and local invasion into the adjacent spaces and above. FNAC of the swelling was done with a 24 guage fine needle. Multiple passes were given in different directions. Smears were air dried for May grunwald giemsa staining and papanicolau staining was done on smears wet fixed in 95% alcohol. Cytomorphology showed cellular smears comprising of pleomorphic round to polygonal to spindle

shaped cells with greyish vacuolated cytoplasm, coarse chromatin and prominent nucleoli. Many bizarre cells along with interspersed amorphous pinkish stromal substance were seen in a haemorrhagic background [Figure 1]. Diagnosis of a malignant tumor with a possibility of osteosarcoma was extended. The patient underwent incisional biopsy of the swelling. The sections stained with hematoxylin and eosin showed a mesenchymal tumour mainly composed of round to oval to spindle shaped highly pleomorphic cells having hyperchromatic irregular shaped nuclei. The osteoid was laid down by the tumour cells in the form of thin trabeculae to irregular large sheets of dense eosinophilic matrix. Tumour giant cells and mitotic figures were also seen in the stroma. A histopathological diagnosis of osteogenic osteosarcoma was made [Figure2].

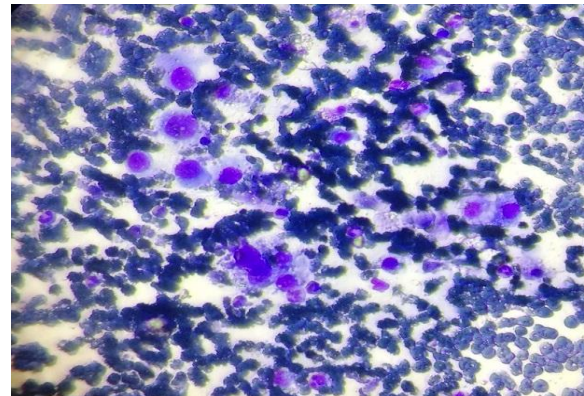


Figure 1: Smear showing malignant round to polygonal cell having pleomorphic hyperchromatic nuclei, prominent nucleoli and greyish blue vacuolated cytoplasm (MGG X40).

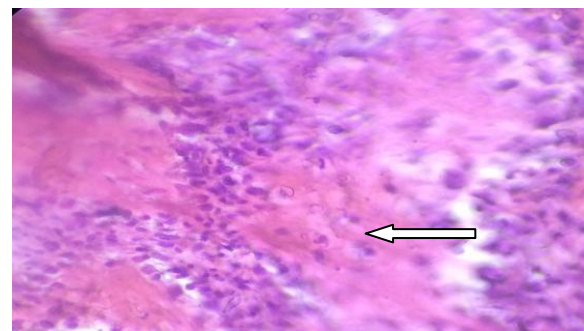


Figure 2: Section showing sheets of oval to spindle shaped tumor cells. Arrow shows osteoid being laid down by the tumor cells.

DISCUSSION

Osteosarcoma is the most common primary malignancy of bone. Osteosarcoma of craniofacial region is relatively rare with nearly equal frequency in maxilla and mandible.^[8]

The exact etiopathogenesis of osteosarcoma is unknown. However, factors predisposing to osteosarcoma are rapid bone growth during adolescence, environmental factors such as radiation and bony abnormalities as in Paget's disease, fibrous dysplasia, multiple osteochondromatosis, chronic osteomyelitis.^[9, 10] There were no such predisposing factors in our case.

Histologically diagnosis of osteosarcoma is based on demonstration of osteoid being directly laid down by tumor cells. Osteoid is seen as dense pink, curvilinear amorphous material often arranged in a lace like pattern.^[5,10] The tumor cells can be spindle, clear, epithelioid, plasmacytoid or anaplastic giant cells or a mixture of these.^[5,11] Osteosarcomas are classified histologically according to the predominant extracellular matrix produced by the tumor cells as osteoblastic osteosarcoma in which osteoid matrix or bone predominates; chondroblastic osteosarcoma which is characterised by predominant presence of chondroid matrix; fibroblastic osteosarcoma which is characterised by high degree of fusiform neoplastic cells with minimal quantities of bone matrix with or without presence of cartilage¹. Other histological types include telangiectatic type osteosarcoma, malignant fibrous histiocytoma like osteosarcoma, large cell predominant osteosarcoma, and small cell or round cell predominant osteosarcoma.^[1,11] In craniofacial bones, chondroblastic osteosarcoma is the most common type followed by osteoblastic. Although histopathological subtypes have not been shown to have prognostic significance,

degree of cellular anaplasia is prognostically significant as high grade osteosarcomas have been associated with poor prognosis.^[5]

Though osteosarcoma of jaw bones and long bones show common histological features, they are distinct biological entities.^[12] Osteosarcomas of jaw bones are less aggressive, occur in more elderly population and prefer local invasion rather than metastasis. The age of the patient in this case was lower than this age group though some series also report occurrence in younger age groups.

The technique of needle aspiration was first applied to bone tumors in 1931.^[13] Later Martin and Ellis studied the technique exhaustively including its application in bone tumors.^[14] Since then it has gained popularity in diagnosing bone tumors. Fine needle aspiration smears in osteosarcoma show markedly anaplastic discohesive round to spindle shaped cells with moderate to abundant cytoplasm, large pleomorphic and hyperchromatic nuclei with coarse chromatin with or without macronucleoli. Mitosis can be frequent. Mononucleate or multinucleate tumor giant cells may be seen.^[15-17] Osteoid appears as faintly eosinophilic material in H&E and bright red or pink in MGG with an amorphous fibrillary character.^[15,16] Chondroblastic variant of osteosarcoma shows an abundant chondromyxoid material in background which is seen as a granular film with scattered clear bubbles with cell clusters, aggregates and dissociated cells embedded in it. Cells are round to polygonal with significant pleomorphism, abundant vacuolated cytoplasm, hyperchromatic and pleomorphic nuclei with prominent nucleoli.^[15,18,19] Differential diagnosis of chondroblastic osteosarcoma and chondrosarcoma can be difficult on cytology.

The treatment of osteosarcoma of jaw is radical or conservative surgery

followed by radio or chemotherapy. Surgical margin appears important in terms of prognosis. Obtaining sufficiently safe surgical margins is difficult in maxillary tumors and this is responsible for high recurrence rate for these tumors. [8]

CONCLUSION

Osteosarcoma of the maxilla is a relatively rare tumor. Due to non specific clinical and conventional radiographic features, the diagnosis of osteosarcoma of jaw can be delayed or even misdiagnosed especially for inflammatory pathology and this may badly affect the prognosis. Knowledge of this tumor is essential for its early detection and treatment. Fine needle aspiration cytology is a simple, rapid and fairly accurate method in diagnosis of osteosarcomas of the jaw. It may provide definitive diagnosis in many cases or at least may suggest a malignant neoplasm which can be very helpful in early detection and prompt management of this aggressive tumor.

REFERENCES

1. Almeida E, Mascarenhas BA, Cerqueira A, Medrado AR. Chondroblastic osteosarcoma. *J Oral Maxillofac Pathol* 2014 ;18(3):464-8
2. Khorate MM, Goll S, Singh MP, Ahmed J. Osteosarcoma of Mandible: A Case Report and Review of Literature. *J Cancer Sci Ther* 2010; 2: 122-25.
3. Ottaviani G, Jaffe N. The epidemiology of osteosarcoma. *Cancer Treat Res* 2009; 152:3-13.
4. Cabral LA, Werkman C, Brandão AA, Almeida JD. Imprint cytology of osteosarcoma of the jaw: a case report. *J Med Case Rep* 2009 ;3:9327
5. Anil S, Krishnan AP, Rajendran R. Osteosarcoma of the mandible masquerading as a dental abscess: report of a case. *Case Rep Dent* 2012;2012: 635062

6. Kedar S, Nagle S, Agarwal S, Bage S, Kothekar A, Kashide R, Ahire D. Giant chondroblastic osteosarcoma mandible- a rare case report. *Otolaryngology* 2013; 3: 146
7. Praveena NM, Maragathavalli G. Osteosarcoma of maxilla. *J Indian Aca Oral Med Radiol* 2012;24(3): 236-238
8. Sayin B, Yildirim N, Vural M, Dede D. Osteosarcoma of the maxilla. *Radiol Oncol* 2005; 39(2): 95-9.
9. Hudson M, Jaffe MR, Jaffe N, Ayala A, Raymond AK, Carrasco H, Wallace S, Murray J, Robertson R. Pediatric osteosarcoma: therapeutic strategies, results, and prognostic factors derived from a 10-year experience. *J Clin Oncol* 1990; 8(12): 1988-1997
10. Khandekar S, Dive A, Munde P, Fande PZ. Chondroblastic osteosarcoma of the left zygomatic bone: Rare case report and review of the literature. *J Oral Maxillofac Pathol* 2014;18:281-5
11. Kaur H, Singh A. Osteosarcoma of jaw - Case report and review of literature. *Int J Med and Dent Sci* 2015; 4(1):653-657.
12. Kumaravelu C, Sathya Kumar D, Chakravarthy C, Kishore Kumar RV, Rajasekhar G, Gokul Chandra Reddy M, Sridhar Reddy K. Chondroblastic osteosarcoma of maxilla: a case report and review of literature. *J Maxillofac Oral Surg* 2009; 8(3):290-3.
13. Coley BL, Sharp GS, Ellis KB: Diagnosis of bone tumours by aspiration. *Am J Surg* 1931; 13: 214-224.
14. Martin HE, Ellis EB: Aspiration biopsy. *Surg Gynecol Obstet* 1934; 59: 578-589.
15. Wahane RN, Lele VR, Bobhate SK. Fine needle aspiration cytology of bone tumors. *Acta Cytol* 2007; 51(5):711-20.
16. Sathiyamoorthy S, Ali SZ. Osteoblastic osteosarcoma: cytomorphologic characteristics and differential diagnosis on fine-needle aspiration. *Acta Cytol* 2012; 56(5):481-6.
17. White VA, Fanning CV, Ayala AG, Raymond AK, Carrasco CH, Murray JA. Osteosarcoma and the role of fine-

- needle aspiration. A study of 51 cases. Cancer 1988; 62(6):1238-46.
18. Ellison DA, Silverman JF, Strausbach PS, Joshi VV. Fine-needle aspiration of chondroblastic osteosarcoma of the skull: report of a case in an 11-year-old girl. Diagn Cytopathol 1996 ; 14(1):51-5.
19. Gupta N, Rajwanshi A, Gupta P, Vaiphei K, Gupta AK. Chondroblastic osteosarcoma of the temporal region: a diagnostic dilemma. Diagn Cytopathol 2011; 39(5):377-9.

How to cite this article: Singh K, Kumara R, Gupta P. Osteosarcoma of jaw: a rare case report. Int J Health Sci Res. 2015; 5(9):598-602.

International Journal of Health Sciences & Research (IJHSR)

Publish your work in this journal

The International Journal of Health Sciences & Research is a multidisciplinary indexed open access double-blind peer-reviewed international journal that publishes original research articles from all areas of health sciences and allied branches. This monthly journal is characterised by rapid publication of reviews, original research and case reports across all the fields of health sciences. The details of journal are available on its official website (www.ijhsr.org).

Submit your manuscript by email: editor.ijhsr@gmail.com OR editor.ijhsr@yahoo.com