



Original Research Article

## Morphometry of Bony Orbit Related to Gender in Dry Adult Skulls of South Indian Population

S. Senthil Kumar<sup>1</sup>, E. Gnanagurudasan<sup>2</sup>

<sup>1</sup>Professor, <sup>2</sup>Ph.D Scholar,

Department of Anatomy, Sri Ramachandra Medical College and Research Institute, Sri Ramachandra University, Porur, Chennai, Tamil Nadu.

Corresponding Author: E. Gnanagurudasan

Received: 16/07/2015

Revised: 11/08/2015

Accepted: 12/08/2015

### ABSTRACT

**Introduction:** Orbit lodges important structures for vision and allows passage of fine neurovascular structures in it. The knowledge of orbital morphometry helps to protect those structures during various surgical procedures.

**Aim:** To determine the morphometry of bony orbit in dry South Indian skulls related to gender and to compare the results with previous authors.

**Material and Methods:** The material of the present study consists of 100 orbits from 50 skulls (right & left) which are identifiable of their sex. Foetal skulls and skulls with damages in the area of measurement were excluded. All the parameters were examined by a single observer using a vernier calliper, divider and millimetre scale. In each wall of the orbit, a bony landmark is chosen from where the distance of other bony structures is measured.

**Result:** The result of the present study showed significance with respect to gender and side.

**Conclusion:** The data of the present study will be helpful for various surgical approaches around the orbit.

**Keywords:** orbit, South Indian skulls, morphometry.

### INTRODUCTION

The bony orbits are skeletal cavities located on either side of the root of the nose. They house the eyes, the paired peripheral organs of vision. The walls of each orbit protect the eye from injury, provide points of attachment for six extra ocular muscles which allow the accurate positioning of the visual axis, and determine the spatial relationship between the two eyes, which is essential for both binocular vision and conjugate eye movements. [1] Whitnall described the orbit as a quadrilateral

pyramidal cavity formed by seven bones namely maxilla, palatine, frontal, zygomatic, sphenoid, ethmoid & lacrimal bone with base directed forwards, lateral and slightly downwards corresponding to orbital margin and apex directed posteromedially. [2]

Seven bones form each orbit, and they are arranged to form a four-sided pyramid with a posterior apex and anterior base. This pyramid is not straight but in a medially tilted axis. This fact constitutes the basis of the human stereoscopic vision and allows for understanding the location of

orbital foramina. In the orbit, all openings are arranged around the base, apex or between the orbital walls.

Patnaik V.V.G et al [3] in their study examined the bony boundaries, walls & various openings of the orbit. Various weak areas in different walls were discussed which guide the fracture lines. A mention has been made of distances of the orbit from important bony landmarks which are to be borne in mind during surgery in the region. The author also discussed the various age changes & sex differences to help Forensic Experts. Thanasil Huanmanop et al [4] conducted a study to provide the morphometric data of the orbital foramina related to side and gender in Thai subjects. One hundred orbits from 50 adult dried skulls were used. Gender of each skull was identified and the distances from the constant landmarks to the foramina in the medial, superior, inferior, and lateral walls were measured. Their results suggest that race, side, and gender should be concerned during the orbital surgery.

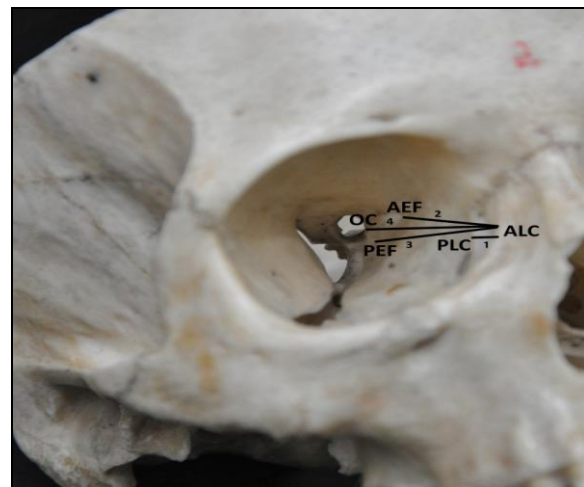
Several diseases including trauma, inflammation, infection and tumor can involve the orbital cavity. In particular situation, surgeries in the orbit, for example, orbital decompression, enucleation, exenteration, optic nerve decompression and vascular ligation have an essential role. However to avoid injuries to the important structures in the orbit mainly neurovascular bundle passing through various foramina and fissures, precise knowledge about the morphometry of orbit is indispensable. [5] This study is aimed at evaluating the morphometry of orbit related to gender in south Indian population and to get baseline data regarding orbit.

## MATERIALS AND METHODS

The material of the present study consists of 100 orbits from 50 skulls (right & left) identifiable of their sex. Foetal skulls

and skulls with damages in the area of measurement were excluded. All the parameters were examined by a single observer using a vernier calliper, divider and millimeter scale. Two measurements were made for each parameter to get an average value. In each wall of the orbit, a bony landmark is chosen from where the distance of other structures is measured.

**Medial wall:** In the medial wall anterior lacrimal crest (ALC) is chosen as the bony landmark. The distances from the anterior lacrimal crest (ALC) to the posterior lacrimal crest (PLC), the anterior & posterior ethmoidal foramina (AEF, PEF) and to the medial border of the optic canal (OC) were measured (fig.1). In case of multiple PEF, the most posterior foramen was used for the measurements. This was to provide the longest distance that this foramen could still be present posterior to other foramina or the landmark.

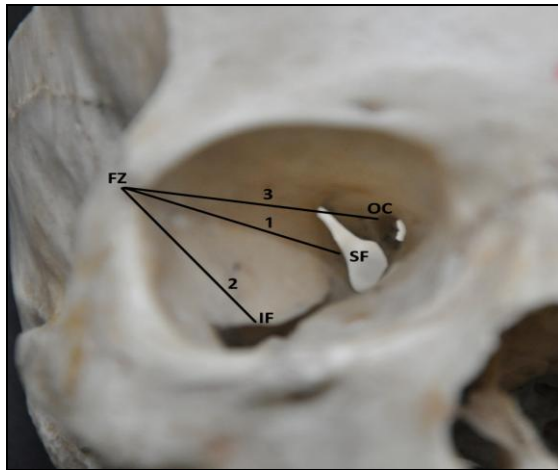


**Fig 1: Measurements in the medial wall of orbit**

1. Distance between anterior lacrimal crest to posterior lacrimal crest
2. Distance between anterior lacrimal crest to anterior ethmoidal foramen
3. Distance between anterior lacrimal crest to posterior ethmoidal foramen
4. Distance between anterior lacrimal crest to optic canal

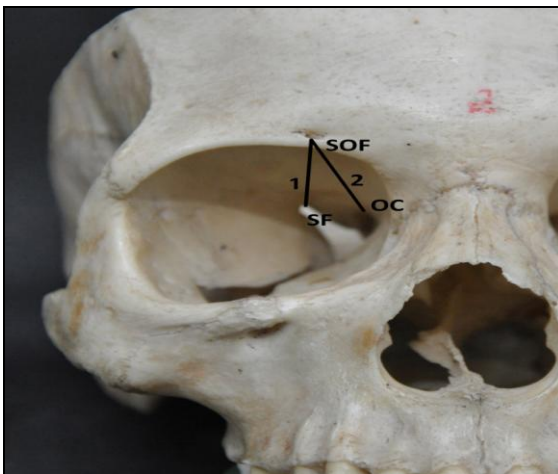**Lateral wall:** In the lateral wall the distances from the fronto-zygomatic suture (FZ) to the closest margin of the superior orbital fissure (SOF), the inferior orbital

fissure (IF), the medial border of optic canal (OC) were measured (fig.2).



**Fig.2 Measurements in the lateral wall of orbit**  
 1. Distance between Fronto-zygomatic suture to superior orbital fissure  
 2. Distance between Fronto-zygomatic suture to inferior orbital fissure  
 3. Distance between Fronto-zygomatic suture to optic canal

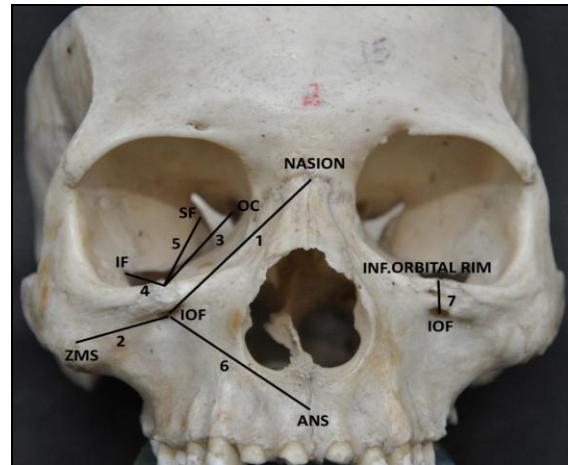
**Superior wall or roof:** The distances from the Supraorbital notch or foramen (SN/F) to the closest margin of the superior orbital fissure (SOF), the superior border of the OC were determined (fig.3).



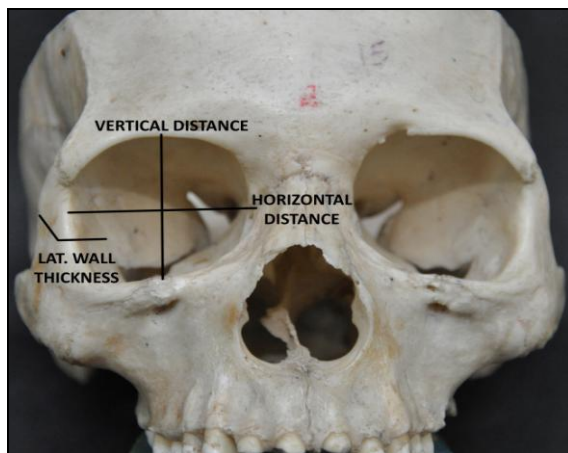
**Fig.3 Measurements in the superior wall of orbit**  
 1. Distance between supraorbital foramen to superior orbital fissure  
 2. Distance between supraorbital foramen to optic canal

**Inferior wall or floor:** The infraorbital foramen was the landmark to which the following bony structures were determined; Nasion (NAS), Zygomatico-maxillary suture (ZMS), optic canal (OC), inferior and superior orbital fissure (IF & SOF) (fig.4).

In addition to the above mentioned analysis of the distances of bony landmarks, Vertical distance is measured by taking the midpoint of the supra and infraorbital notches, Horizontal distance is measured by taking the midpoint of the medial and lateral walls, lateral wall thickness is ascertained by taking the midpoint of the lateral wall close to the fronto-zygomatic suture(fig.5).



**Fig.4 Measurements in the inferior wall of orbit**  
 1. Distance between infraorbital foramen to nasion  
 2. Distance between infraorbital foramen to zygomatico-maxillary suture  
 3. Distance between inferior orbital rim to optic canal  
 4. Distance between inferior orbital rim to inferior orbital fissure  
 5. Distance between inferior orbital rim to superior orbital fissure  
 6. Distance between infraorbital foramen to anterior nasal spine  
 7. Distance between inferior orbital rim to infraorbital foramen



**Fig.5 other parameters in the orbit**

**Statistical analysis:** Paired t-test was used to compare the parameters between side and gender for each measurement. Statistically

significant differences were reported when p-values were less than 0.05.

## RESULTS

In the medial wall the mean distance from ALC to PLC in males is  $7.40 \pm 1.00$  mm on the right side and  $7.60 \pm 1.32$  mm on the left side, in females it is  $7.72 \pm 1.06$  mm on the right side and  $7.84 \pm 1.07$  mm on the left side. This is the only parameter in the medial wall where the measurement is more in females than males, but it is statistically insignificant. The mean distance between the anterior lacrimal crest (ALC) to the anterior ethmoidal foramen (AEF) is  $24.52 \pm 2.69$  mm on the right side and  $23.88 \pm 2.76$  mm on the left side in males and  $23.84 \pm 3.02$  mm on the right side  $23.00 \pm 3.01$  mm on the left side in females. The mean distance between ALC to PEF in males is  $36.84 \pm 1.97$  mm on the right side and  $36.48 \pm 2.10$  mm on the left side. In females it is  $36.80 \pm 2.08$  mm on the right side and  $35.88 \pm 2.03$  mm on the left side. These parameters are statistically significant in both sides (Table-1). The mean distance between the anterior lacrimal crest to the optic canal is  $42.40 \pm 2.60$  mm on the right side and  $41.84 \pm 2.10$  mm on the left side in males, for females it is  $42.08 \pm 2.33$  mm on the right side and  $41.64 \pm 2.18$  mm on the left side in females, thus signifies an increase in the distance in males than

females and also between sides i.e on the right side the distance is more than the left side.

In the lateral wall the mean distance from the fronto-zygomatic suture to the superior orbital fissure is  $36.60 \pm 2.42$  mm on the right side and  $35.44 \pm 2.79$  mm on the left side in males and  $37.00 \pm 2.22$  mm on the right side and  $35.72 \pm 1.97$  mm on the left side in females. (Table-2). The mean distance from the fronto-zygomatic suture to the optic canal is  $45.36 \pm 2.40$  mm on the right side and  $44.80 \pm 2.16$  mm on the left side in males and  $45.12 \pm 1.56$  mm on the right side and  $45.12 \pm 2.27$  mm on the left side in females. In the roof of the orbit the distance between supraorbital notch or foramen (SF) to superior orbital fissure (SOF) in males is  $40.88 \pm 3.69$  mm on the right side and  $40.24 \pm 4.55$  mm on the left side. In females it is  $42.28 \pm 3.81$  mm on the right side and  $41.96 \pm 4.55$  mm on the left side (Table-3). The distance between the infraorbital foramen to the optic canal is  $47.60 \pm 1.17$  mm on the right side and  $46.60 \pm 1.84$  mm on the left side in males and in females it is  $44.52 \pm 1.12$  mm on the right side and  $44.61 \pm 1.14$  mm on the left side (Table -4). The horizontal distance and lateral wall thickness of the orbit vary considerably between side and the measurements in female orbits are lesser than males which are listed in (Table-5).

**Table -1: Measurements in the median wall of orbit:**

Measurement	Male (n=50)		Female (n=50)	
	Right (n=25)	Left (n=25)	Right (n=25)	Left (n=25)
ALC – PLC	$7.40 \pm 1.00$ mm	$7.60 \pm 1.32$ mm	$7.72 \pm 1.06$ mm	$7.84 \pm 1.07$ mm
ALC – AEF	$24.52 \pm 2.69^*$ mm	$23.88 \pm 2.76^*$ mm	$23.84 \pm 3.02^*$ mm	$23.00 \pm 3.01^*$ mm
ALC – PEF	$36.84 \pm 1.97^*$ mm	$36.48 \pm 2.10^*$ mm	$36.80 \pm 2.08^*$ mm	$35.88 \pm 2.03^*$ mm
ALC – OC	$42.40 \pm 2.60$ mm	$41.84 \pm 2.10$ mm	$42.08 \pm 2.33$ mm	$41.64 \pm 2.18$ mm

Data are Mean $\pm$ SD ALC = Anterior lacrimal crest, PLC = Posterior lacrimal crest, AEF = Anterior ethmoidal foramen, PEF = Posterior ethmoidal foramen, OC = Optical canal (Medial border)

**Table – 2: Measurements in the lateral wall of orbit:**

Measurement	Male (n=50)		Female (n=50)	
	Right (n=25)	Left (n=25)	Right (n=25)	Left (n=25)
FZ - SOF	$36.60 \pm 2.42^*$ mm	$35.44 \pm 2.79^*$ mm	$37.00 \pm 2.22^*$ mm	$35.72 \pm 1.97^*$ mm
FZ – IF	$26.20 \pm 4.32$ mm	$26.16 \pm 4.15$ mm	$26.76 \pm 4.40^*$ mm	$26.24 \pm 4.93^*$ mm
FZ – OC	$45.36 \pm 2.40$ mm	$44.80 \pm 2.16$ mm	$45.12 \pm 1.56$ mm	$45.16 \pm 2.27$ mm

Data are Mean $\pm$ SD FZ = Fronto zygomatic suture, SOF = Superior orbital fissure, IF = Inferior orbital fissure, OC = Optic canal.

**Table – 3: Measurements in the superior wall of orbit:**

Measurement	Male (n=50)		Female (n=50)	
	Right (n=25)	Left (n=25)	Right (n=25)	Left (n=25)
SF – SOF	40.88±3.69* mm	40.24±4.55* mm	42.28±3.81* mm	41.96±4.55* mm
SF – OC	42.68±2.72 mm	42.76±2.40 mm	42.12±2.98 mm	41.80±2.18 mm

Data are Mean±SD SF = Supra orbital foramen, SOF = Superior orbital fissure, OC = Optic canal

**Table – 4: Measurements in the inferior wall of orbit:**

Measurement	Male (n=50)		Female (n=50)	
	Right (n=25)	Left (n=25)	Right (n=25)	Left (n=25)
IOF – NASION	38.45±3.28 mm	37.95±3.33 mm	32.86±2.66 mm	30.16±2.06 mm
IOF – ZMS	28.35±8.57* mm	27.40±9.33* mm	27.32±7.50* mm	27.31±6.31* mm
IOF – OC	47.60±1.17* mm	46.60±1.84* mm	44.52±1.12* mm	44.61±1.14* mm
IOF – IF	20.20±2.39 mm	19.50±2.50 mm	20.22±2.31 mm	19.12±2.20 mm
IOF – SOF	43.30±2.41 mm	43.70±2.67 mm	41.32±2.38 mm	41.70±2.61 mm
IOF – ANS	36.30±2.26 mm	36.00±2.36 mm	34.31±2.20 mm	33.01±2.31 mm
IOF -ORBITAL RIM	7.60±1.07 mm	6.80±0.42 mm	7.11±1.02 mm	6.02±0.41 mm

Data are Mean ± SD IOF = Infraorbital foramen, ZMS = Zygomatico maxillary suture, OC = Optic canal, IF = Inferior orbital fissure, SOF = Superior orbital fissure, ANS = Anterior nasal septum.

**Table – 5: Other parameters of the orbit:**

Measurement	Male (n=50)		Female (n=50)	
	Right (n=25)	Left (n=25)	Right (n=25)	Left (n=25)
VERTICAL DISTANCE	31.56±2.36 mm	31.28±2.34 mm	32.86±2.66 mm	30.16±2.06 mm
HORIZONTAL DISTANCE	41.44±2.08* mm	40.56±2.24* mm	41.23±2.04* mm	40.04±2.10* mm
LATERAL WALL THICKNESS	14.20±3.44* mm	14.80±3.91* mm	13.21±2.40* mm	14.02±2.91* mm

Data are Mean ± SD

## DISCUSSION

Since the anatomy of the orbit and its foramina seems to be dependent on the population as suggested by the previous authors, [3,6-9] the present study attempts to provide a pertinent morphometric data of orbit in the dry skulls of south Indian population. Carolina Martins et al [16] enunciated that the orbits are paired structures, located on the anterior part of the face. They described the anatomical characteristic of the orbit and revealed the structures are arranged in groups of seven: there are seven bones, seven intraorbital muscles and seven nerves in the orbit. Tumors confined within the periorbita in the anterior two thirds of the orbit can often be approached extracranially, but those located in the apical area, and especially those on the medial side of the optic nerve, often require a transcranial approach.

**Medial wall:** The anterior ethmoidal foramen (AEF) and the posterior ethmoidal foramen (PEF) through which the anterior and posterior ethmoidal vessels pass are present in the medial wall of the orbit. The

anatomy of these foramina is important when performing several procedures eg. ethmoidal vessel ligation for epistaxis, exploration of medial wall fractures, orbital decompression. Like previous authors [10, 11] in the present study also the anterior lacrimal crest was taken as a constant landmark, since it is easily located by palpation.

Thanasil Huanmanop [4] observed the mean distance between the anterior lacrimal crest to the optic canal to be  $42.2 \pm 2.3$  mm in the 100 bony orbits of Thai population which is very similar to the present study. But his study failed to differentiate between gender and side.

Mcqueen et al [12] concluded the mean distance between the anterior lacrimal crest to the optic canal of the United States population as  $43.29 \pm 4.19$  mm which infers increase in the distance in the United States population and she described significant difference between gender and side. This study was conducted in 54 cadaveric specimens in United States population whereas the present study confined only to

the bony orbit. This explains firmly that discrepancy is seen in the mean distances in the population and between genders.

In the distance between anterior lacrimal crest to anterior ethmoidal foramen Thanasil Huanmanop<sup>[4]</sup> observed  $23.5 \pm 2.6$  mm as the mean in Thai population. Whereas the value observed by Mcqueen et al<sup>[12]</sup> in United States population was  $21.96 \pm 3.13$  mm which is lesser than the present study.

The higher incidence of the multiple posterior ethmoidal foramina is clinically important, as all ethmoidal vessels have to be identified to control bleeding during surgery or trauma. In the present study if more than one posterior ethmoidal foramina were present, the most posterior and the prominent one was taken for the study and 64% of multiple foramina were identified which is very close to the Thanasil Huanmanop et al<sup>[4]</sup> on Thai population who observed 62% multiple foramina. Whereas other authors like Mcqueen et al,<sup>[12]</sup> Hwang et al,<sup>[5]</sup> Karaskas et al<sup>[13]</sup> found only 25%, 40% and 28% respectively; this signifies lesser incidence in the European and United States population.

**Lateral wall:** The present study is close to Mcqueen et al,<sup>[12]</sup> who found  $36.59 \pm 4.30$  mm as the mean value in United States population. The parameter is lesser for Thai population as reported by Thanasil Huanmanop et al<sup>[4]</sup> as  $34.5 \pm 2.6$  mm.

The mean distance from the frontozygomatic suture to the optic canal shows decrease in the distance in south Indian population than those reported by other authors. Mcqueen et al<sup>[12]</sup>  $47.10 \pm 2.88$  mm, Hwang et al<sup>[5]</sup>  $47.4 \pm 3.0$  mm, Karaskas et al<sup>[13]</sup>  $46.9 \pm 2.5$  mm, Thanasil Huanmanop et al<sup>[4]</sup>  $46.7 \pm 2.9$  mm.

**Superior wall:** The superior wall of the orbit is involved in several procedures, such as frontal sinus obliteration, orbital decompression, exploration for fractures and

orbital exenteration. The supraorbital foramen (SOF) is found close to the superior orbital rim and therefore was used as the reference point for the measurements in the superior wall.

The mean distance from the supraorbital foramen to the optic canal (OC) observed in the present study is comparatively lesser than the other studies. The distances between supraorbital foramen to optic canal in the present study is significantly shorter in females than males as reported previously by Thanasil Huanmanop<sup>[4]</sup> in Thai population and Hwang et al<sup>[5]</sup> in Korean population.

These findings may indicate that the location of important structures in the orbital roof can be slightly closer to the supraorbital foramen in females than in males and should be kept in mind aware.

**Inferior wall:** In the inferior wall, orbital floor exploration and maxillectomy are important related procedures. The infraorbital foramen was used as the landmark for measurement. In the present study the distance between the infraorbital foramen to the optic canal is similar to the observations of Mcqueen et al and Thanasil Huanmanop who reported  $47.10 \pm 2.88$  mm and  $46.9 \pm 2.4$  mm respectively. These findings suggest that the probable shorter distances to the neurovascular bundle during surgical approach in the inferior orbital wall in the Asian population to be kept in mind. Same was initially observed by Thanasil Huanmanop in Thai population and the present study reaffirms it in the South Indian population.

The location of infraorbital foramen has become mandatory for different procedures to reduce the risk in orbital surgeries and Macedo et al<sup>[14]</sup> observed the infraorbital rim to be the easier way to locate the foramen. He found the mean distance between the infraorbital foramen to the inferior orbital rim as  $6.28 \pm 1.79$  mm on the

right side and  $6.45 \pm 1.76$  mm on the left side in a sample of 295 adult Brazilian skulls. Whereas in the present study the distance between the infraorbital foramen to the inferior orbital rim is found to be  $7.60 \pm 1.07$  mm on the right side and  $6.80 \pm 0.42$  mm on the left side in males and for females it is found to be  $7.11 \pm 1.02$  mm on the right side and  $6.02 \pm 0.41$  mm on the left side. The observation in the present study signifies an increase of the distance in the south Indian population.

The laterality of the infraorbital foramen can be ascertained by measuring the distances from the Nasion to the Infraorbital foramen and found to be  $38.45 \pm 3.28$  mm on the right side and  $37.95 \pm 3.33$  mm on the left side in males and in females the distance found was  $32.86 \pm 2.66$  mm on the right side and  $30.16 \pm 2.06$  mm on the left side, from which we can infer the laterality is more on the right side than the left. There is no other relevant study available to compare the mean distance from the Nasion to Infraorbital foramen and the present study will be more reliable as it is the first study which included many parameters.

Another parameter also proves to be of help in order to locate the infraorbital foramen, is the distance from Zygomatico-maxillary suture to the infraorbital foramen, it was the present study and it is  $28.35 \pm 8.57$  mm on the right side and  $27.40 \pm 9.33$  mm on the left side in males and  $27.32 \pm 7.50$  mm on the right side and  $27.81 \pm 6.51$  mm on the left side in females. The values are similar to the observations by Isurani Ilayaperuma <sup>[15]</sup> in Sri Lankan Tamil Population.

The mean horizontal distance in the present study shows significant increase in the distance in males than females that proves to be valuable in the orbital approaches.

Similarly the vertical distance and the lateral wall thickness also found to be more in males than females. Thus gender plays a vital role in the surgical approach of the orbital region. No similar studies were done with the above parameters and so comparison could not be made among ethnic groups.

## CONCLUSION

The morphometry of orbit in the present study is found to vary between side and gender which makes it significant during surgical approaches to preserve the most vital structures passing through the orbit. The differences with other population groups suggest that this aspect of learning the morphometry could further enhance the present knowledge of the anthropometry. However more parameters are required in other population groups to make comparative analysis.

## ACKNOWLEDGEMENT

The Authors would like to gratefully acknowledge the assistance provided by Sri Ramachandra University in the form of Founder-Chancellor Shri N.P.V Ramasamy Udayar Research Fellowship grant for Ph.D 2014.

The Authors would like to thank Prof. Dr. Usha Kothandaraman, ESI Medical College, Chennai and Dr. Chandrika Teli, ESI Medical College, Gulbarga for their support and guidance.

## REFERENCES

1. Standring S, Ellis H, Healy JC, Johnson D, Williams A, Collins P, et al, eds. Gray's Anatomy: The Anatomical Basis of Clinical Practice. 39th Edition, Elsevier, Churchill Livingstone, London. 2005: 511-513.
2. Whitnall S.E. The Anatomy of the human orbit: Oxford university press. 2<sup>nd</sup> Ed. London; 1921:1-52.
3. Patnaik Vvg, Bala Sanju, Singla Rajan K, Anatomy of the bony orbit - some

- applied aspects. Journal of the anatomical society of India, 2001, 50(1):59-67.
4. Huanmanop, Chentanez, Anatomic characteristic of the infraorbital nerve: A cadaver study. J Oral Maxillofac surg 2000; 58; 992-996.
  5. Hwang, Han, Baik, Communication of the infraorbital nerve and facial nerve; an anatomic and histologic study. The journal of craniofacial surgery 2004, 15:88-91.
  6. Willa Rachel Trusk, Transethmoidal approach to the optic canal: Surgical and radiological microanatomy. Surg Neurol 2004;62:268-74.
  7. Wandee Apinhasmit, Suprorbital notch/foramen, Infraorbital foramen and mental foramen in Thais: Anthropometric measurements and surgical relevance. J Med assoc Thai 2006;89(5):675-682.
  8. Bakholdina Vlu, Morphometric characteristics and typology of the human orbit, Morphologia, 2008; 133(4): 37-40.
  9. Brunos Ramos Chrcanovic, Morphometric analysis of the supraorbital and infraorbital foramina relative to surgical landmarks. Surg.Radio. Anat 2011, May 33(4); 329-335.
  10. Gozdziwski S, Die morphologische analyse des canalis infraorbitalis und des foramen ifraorbitale beim menschen. Anat. Anz 1979:145:517-527.
  11. Hindy And Abel Rouf, A study of infraorbital foramen, canal and nerve in adult Egyptians. Egyptian Dental Journal 1993:39:573-80.
  12. Mcqueen CT, Orbital osteology: A study of the surgical landmarks, laryngoscope 1995;105:783-788.
  13. Mg Bozkir, P Karakas and O Oguz, Measurement of the soft tissues in Turkish young adults, Surg. Radiol. Anat. 2003, Apr; 25(1): 54-57.
  14. Macedo VC, Cabrini RR, Infraorbital foramen location in dry human skulls. Braz. J.Morphol sci, 2009, vol, 26, no.1, p.35-38.
  15. Isurani Ilayaperuma, Ganananda Nanayakara, Morphometric analysis of the infraorbital foramen in adult Sri Lankan population, Int. J. Morphol 2010: 28(3):777-782.
  16. Carolina Martins, Isabel Eugenia. Microsurgical anatomy of the orbit: Rule of seven. Anatomy research international 2011; vol. 3:1-14.

How to cite this article: Kumar SS, Gnanagurudasan E. Morphometry of bony orbit related to gender in dry adult skulls of south Indian population. Int J Health Sci Res. 2015; 5(9):207-214.

\*\*\*\*\*