



Short Communication

A Study of Precondylar Tubercles on the Basiocciput in South Indian Adult Human Skulls

Neelima P¹, B. N. Rao²

¹Associate Professor, ²Professor & HOD,
Department of Anatomy, GIMSR, GITAM University, Rushikonda, Visakhapatnam, Andhra Pradesh, India.

Corresponding Author: Neelima P

Received: 22/04/2015

Revised: 22/05/2015

Accepted: 16/07/2015

ABSTRACT

The knowledge of the occasional occurrence of tubercles in front of the occipital condyles in norma basalis is very much essential for the neurosurgeons, radiologists, anthropologists and anatomists in their regular practice and teaching curriculum. The present study is based on the occurrence of these precondylar tubercles in various forms like single, paired, ridges, spines and depressions in front of the occipital condyles on the basiocciput. Of the 160 skulls studied, 28 skulls were found to have projections on the basiocciput in various forms. 3 skulls revealed bilateral depressions instead of projections. 9 skulls showed bilateral prominent tubercles, 6 unilateral tubercles, 5 exhibited spines and ridges on both sides were present for another 5 skulls. There is a considerable increase in the incidence of occurrence of precondylar tubercles in the present study when compared to the previous studies which mark its significance clinically.

Key words: Precondylar tubercles, occipital condyles, ridges, spines, basiocciput

INTRODUCTION

The occipital bone of the human skull seen in the posterior part of the vault and the base of the cranial cavity is divided into 4 parts by virtue of the foramen magnum occupying the median plane. These are squamous, basilar and a pair of condylar parts. ^[1] The basilar part extends anterosuperiorly from the foramen magnum. A small depression immediately anterior to the occipital condyle may occasionally be replaced by a small precondylar tubercle. ^[2] Pharyngeal tubercle is the only projection seen on the inferior surface of the basiocciput 1cm in front of the foramen

magnum to which fibrous raphe of the pharynx is attached. ^[2] The occasional presence of the precondylar tubercles on the inferior surface of the basiocciput marks its etiology as a developmental malformation associated with the cranio-vertebral anomalies. Lang demonstrated the presence of transverse occipital ligament in 40% of dissected cadavers. ^[3] 14% of the skulls displayed these tubercles unilaterally or bilaterally. ^[4] Another study depicted the occurrence as 10%. ^[5] The precondylar tubercles may also exhibit a partial influence on the shape of the occipital condyles though the most common shape of the

occipital condyles is oval according to Naderi et al. [6] There may be other manifestations like paracondylar process, epitransverse process, hypocondylar arch or a third occipital condyle representing an occipital vertebra. [7] As the embryological aspect is concerned, and the base of the occipital bone is developed from the cartilaginous neurocranium under the influence of TGF- β . [8] The presence of these tubercles might not hinder with the physiological aspects of the structures present around it but their presence play a major role in the radiological studies as they may be misinterpreted for a lesion or a localized calcification. The knowledge of these tubercles is also essential for the Anthropologists, Forensic experts, Neurosurgeons and also Anatomists in their regular curriculum of teaching practice. Hence the study was made to detect the percentage of the prevalence of precondylar tubercles in south Indian adult human skulls.

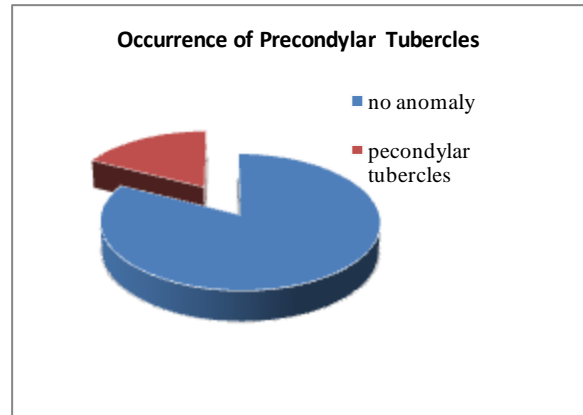
MATERIALS AND METHODS

160 adult human skulls were acquired from the department of Anatomy in various medical colleges in and around Visakhapatnam. The bases of all the skulls were examined for the occurrence of precondylar tubercles in front of the foramen magnum. The results were tabulated and were represented graphically. The same were compared with those of other authors.

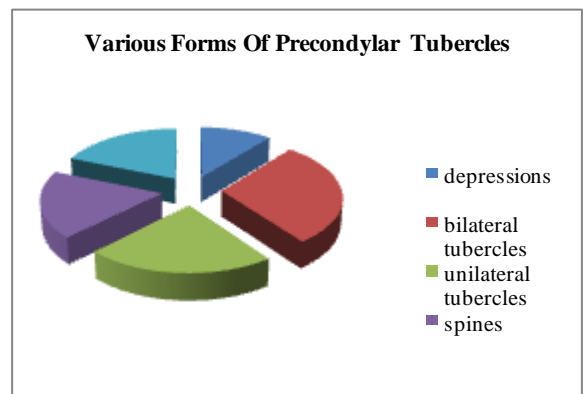
RESULTS

Table 1: Types of Precondylar Tubercles & Their Prevalence

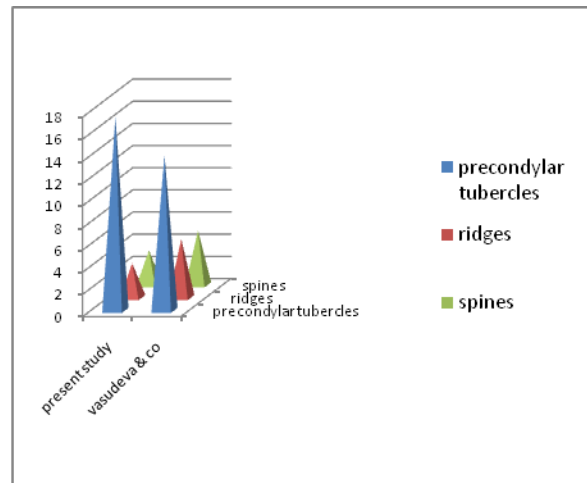
No. of skulls	Anomaly	Percentage
6	Unilateral tubercles	3.75
9	Bilateral tubercles	4.8
5	Spines	3.1
3	Depressions	1.8
5	Ridges	3.1
28	All types	17.5
132	No tubercles	82.5



Graph 1: Occurrence of Precondylar Tubercles among Normal Skulls



Graph 2: Distribution of Various Forms of Precondylar Tubercles



Graph 3: Comparison of Values of Present Study with Other Authors

p value- 0.2939 which is statistically not significant
 p value is calculated from chi square and degree of freedom

$$x^2 - 2.449 ; n=3-1=2$$

$$x^2 = \sum \frac{(o-e)^2}{e}$$

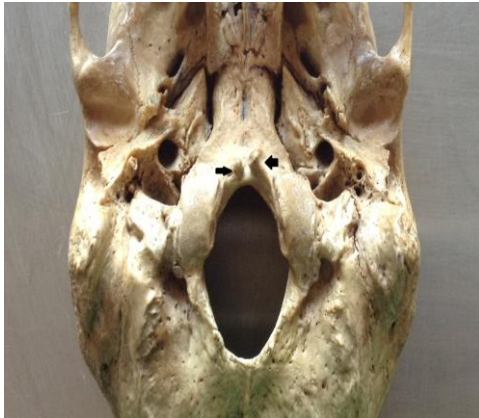

Fig 1: Bilateral Precondylar Tubercles

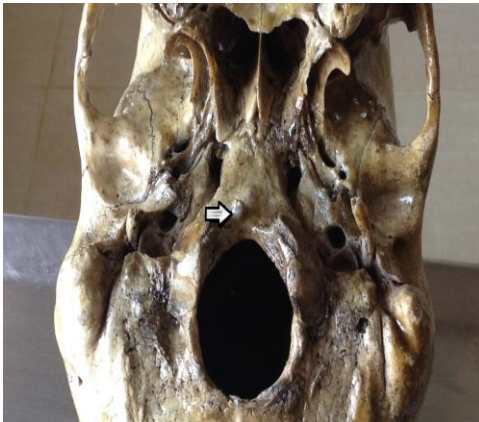

Fig 2: Unilateral Precondylar Tubercle

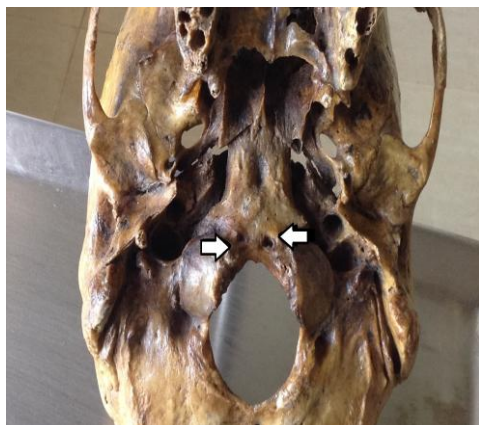

Fig 3: Depressions In Front Of the Foramen Magnum

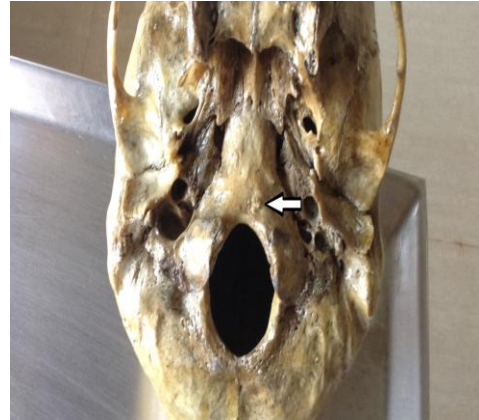

Fig 4: Spinous Projection In Front Of Foramen Magnum

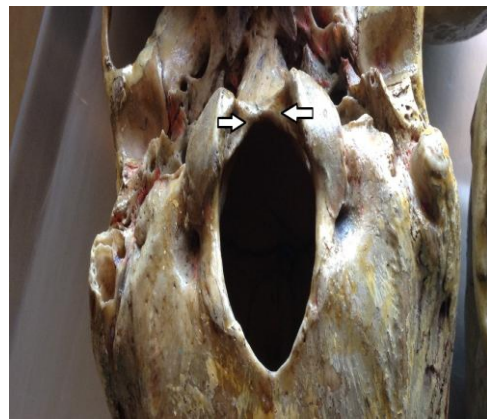

Fig 5: Ridges In Front Of Foramen Magnum

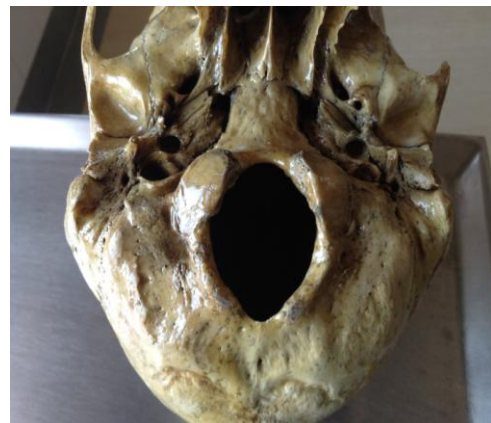

Fig 6: Normal Basiocciput

DISCUSSION

The overall occurrence of preoccipital tubercles turned out to be 17.5% among the human adult skulls which is a quiet considerable number. Various forms of precondylar tubercles were observed in the present study. Of the 160 skulls studied, 28

skulls showed the occurrence of preoccipital tubercles in various forms which clinch its clinical significance besides the anatomical importance. There were 9 skulls showing bilateral tubercles, 6 skulls revealed unilateral tubercles, 3 skulls exhibited depressions instead of elevations, 5 skulls depicted spines and another 5, ridges in front of the foramen magnum on the basiocciput. The numbers were quiet variable when compared to the previous study of other authors. A recent study by Vasudeva & co., gave the result of 14% skulls showing the precondylar tubercles. [4] Another study by Akram revealed 10% skulls for the precondylar tubercles. [5] There is a marked increase in the occurrence of the precondylar tubercles in the present study .The occurrence of precondylar tubercles in various forms also showed a varied difference from the previous studies. The etiology for the occurrence of precondylar tubercles could be due to the variations during the development of basiocciput from the precervical vertebrae as a part of craniovertebral anomalies. The reason for the increase in the incidence of these tubercles might be multifactorial (environmental, genetical, racial, molecular growth factors) which should be stressed upon in future studies.

CONCLUSION

There is increased incidence of occurrence of precondylar tubercles (17.5%) in front of the foramen magnum on the basiocciput when compared to the previous studies (14%). Various forms of the precondylar tubercles have been identified like unilateral tubercles (3.75%), bilateral

tubercles (4.8%), ridges (3.1%), spines (3.1%) and depressions (1.8%). Hence it is concluded from the present study that the occurrence of the preoccipital tubercles in front of the foramen magnum in the basiocciput shows a marked clinical significance.

ACKNOWLEDGEMENTS

I thank the HODs of Anatomy of various medical colleges for permitting to do the present study.

REFERENCES

1. A.K.Datta, Essentials of Human Anatomy part-2, 4th edition pg-4, 5
2. Gray's Anatomy 40th edition, pg 711
3. Lang J 1986 craniocervical region, osteology & articulations. Neuro orthop 1:67-92
4. Vasudeva N, Choudhry R. Precondylar tubercles on the basiocciput of adult human skulls. J Anat. 1996; 188: 207-210
5. Akram Abood jaffar Anatomical and clinical correlates of the intercondylar tubercle e ISSN 1308-4038 International Journal of Anatomical Variations (2014) 7: 68-70
6. Naderi S, Korman E, Citak G, Guvencer M, Arman C, Senoglu M, Tetik S, Arda MN. Morphometric analysis of human occipital condyle. Clin Neurol Neurosurg. 2005; 107: 191-199
7. Taitz C. Bony observations of some morphological variations and anomalies of the craniovertebral region. Clin Anat. 2000;13(5):354-360. doi: 10.1002/1098-2353(2000)13:5<354::AID-CA5>3.0.CO; 2-6.
8. Moore Persaud The Developing Human 9th Ed, pg- 351

How to cite this article: Neelima P, Rao BN. A study of precondylar tubercles on the basiocciput in south Indian adult human skulls. Int J Health Sci Res. 2015; 5(8):514-517.
