



Original Research Article

Vermian Fossa: An Anatomical Study of Indian Human Dry Skull

Rakesh Kumar Ranjan¹, Deepu Singh Kataria², Upendra Yadav³

¹Demonstrator, Department of Anatomy, Muzaffarnagar Medical College, Muzaffarnagar, U.P., India

²Demonstrator, Department of Anatomy, All India Institute of Medical Sciences, Jodhpur, India

³Associate Professor, College of Nursing, B.P. Koirala Institute of Health Science, Dharan, Nepal

Corresponding Author: Rakesh Kumar Ranjan

Received: 25/06/2015

Revised: 13/07/2015

Accepted: 21/07/2015

ABSTRACT

Background: Vermian fossa is a shallow depression of varying shape and size, which may be found occasionally on the dorsal aspect of foramen magnum. There is paucity of detailed study in the available literature; hence the present study was aimed to determine the incidence, morphology and morphometry of the vermian fossa in adult human dry skull.

Material and Methods: The present study was carried out in 110 dry bones, among them 65 were separate occipital bone and 45 were cranial base. All the bones were examined for the existence of a fossa on the inner surface of squamous part of occipital bone, just posterior to the foramen magnum. Height and width of each fossa were measured by a digital vernier caliper. The fossa were macroscopically examined and classified as triangular (type 1), quadrangular (type 2) and atypical (type 3).

Result: The fossa was observed in 88 (80%) bones and its shape was triangular in 62 (70.45%) specimens, quadrangular in 7 (7.95%) specimens and atypical in 19 (21.59%).

Conclusion: The incidence of vermian fossa was higher in our study as compared to previous study and majority of them were of triangular in shape. Detailed and accurate knowledge of the variability of the human morphology and morphometry improves the diagnosis and therapeutic performance. We believe that this study can also provide clue about the shape of the inferior cerebellar vermis.

Key words: Vermian fossa, Foramen magnum, Internal occipital crest, Morphometry, Vermis, Occipital bone, Indian population

INTRODUCTION

The Vermian fossa (VF) or the middle cerebellar fossa of Verga is a small depression, located at the lower part of internal occipital crest on the dorsal aspect of foramen magnum. [1] On the inner surface of squamous part of occipital bone, there is a median elevation (internal occipital protuberance) from which a prominent median crest, the internal occipital crest

descends towards the foramen magnum which provides attachment for the falx cerebelli. [2] Occasionally just above the foramen magnum, the internal occipital crest splits into two lips to enclose a shallow triangular depression of variable size, the vermian fossa in which part of the inferior vermis of cerebellum lodges. [3] It is reported that the vermian fossa is of varying size and found occasionally on the dorsal aspect of

foramen magnum. The fossa might be partitioned in to an upper and lower part by a bone ridge. There is a paucity of the detailed morphological and morphometric study of vermian fossa in the available literature. Hence the present study was aimed to determine the incidence, morphology and morphometry of the vermian fossa in the Indian adult human dry skull.

MATERIALS AND METHODS

The study was carried out in the Anatomy Department of Muzaffarnagar Medical College, Muzaffarnagar and Teerthanker Mahaveer Medical College and research center, Moradabad U.P., India. Totally 110 bones were examined for the study, among them 65 were separate occipital bone and 45 were cranial base (vault removed). The skulls and occipital bone which were damaged or having any pathological changes were excluded from the study.

The inner surface of squamous part of occipital bone was examined for the

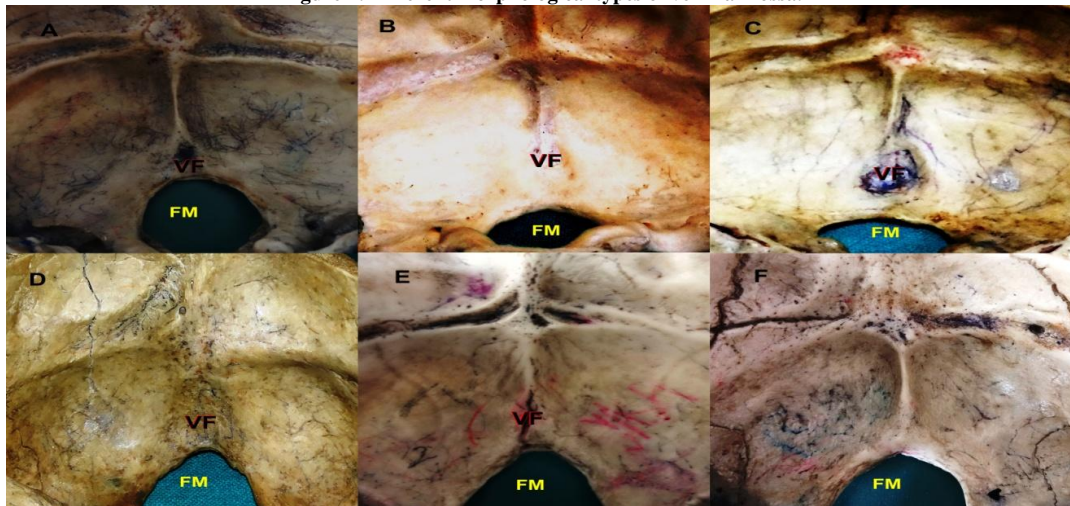
existence of the fossa just posterior to the foramen magnum. The fossa were macroscopically examined and classified as Triangular (Type 1), Quadrangular (Type 2) and Atypical (Type 3). The atypical type comprised the fossa which was other than triangular or quadrangular in shape.

The length and width of each vermian fossa were determined by a digital vernier caliper. The length was measured from the most superior to the most inferior part of the fossa where as the width was measured at its maximum. The data were recorded, tabulated and statistically analyzed using Microsoft Office Excel 2007.

RESULT

A total 110 bones were examined in the present study and among them we identified total 88 vermian fossa, 52 out of 65 separate occipital bone and 35 out of 45 cranial base. In the remaining 22 bones, no such fossa was found (Figure 1F). So the incidence of VF in Indian skulls was therefore estimated as 80%.

Figure 1: Different morphological types of vermian fossa.



A: triangular shape (type 1); B: quadrangular shape (type 2); C: atypical, deep (type 3); D: atypical, widened (type 3); E: atypical, partitioned (type 3); F: absent vermian fossa. (VF= vermian fossa; FM= foramen magnum).

Further the found vermian fossa were triangular shaped (Type 1, Figure 1A)

in 62 specimens (70.45%) and quadrangular (Type 2, Figure 1B) in 7 specimens (7.95%).

Rest 19 specimens (21.59%) were not accepted as type 1 or type 2 due to its unusual morphology and was considered as atypical (Type 3)

Among the atypical type, 6 vermian fossa were looked like triangular in shape but is was deepened on its lower part (figure 1C) whereas in other 10 specimens, the fossa were widened as the lateral borders are getting far away from each other (Figure 1D). Rest 3 atypical vermian fossa were partitioned (Figure 1E).

The mean height and width of the vermian fossa was found 13.4 mm and 12.1mm respectively

DISCUSSION

The inner surface of the squamous part of occipital bone is divided into 4 deep compartments by an irregular, median, internal occipital protuberance and ridged horizontal and sagittal extensions form that protuberance. The two superior fossa are shaped to accommodate the occipital pole of cerebral hemisphere, and the inferior fossa to accommodate cerebellar hemisphere. [4]

A shallow V-shaped fossa of varying size may be found on the dorsal aspect of Foramen magnum, formed by the bifurcation of internal occipital crest and attached falx cerebelli at its inferior end. [5] The fossa lodge the inferior part of cerebellar vermis, which is divided into Tuber, Pyramid, Uvula and Nodule. [6] A well marked vermin fossa was reported in animal like Lemur and Marmoset while it

was found absent in Macacus monkey and Cercopithcus. [7]

Berge and Bergman in 2001 has reported the frequency of VF as 4% in their study, performed on 100 skulls. [8] Kale, Ozturk, Aksu et al in 2008 reported 8.2% incidence of VF in Turkish skull. For the first time in the literature they made the morphological classification of the fossa into type 1 (triangular). Type 2 (quadrangular) and the shape other than these as type 3 (atypical). They observed 53.84% type 1, 30.76% type 2 and remaining 15.38% as type 3 vermian fossa. [9]

In 2013 Murlimanju et al found 71.42% incidence of VF in Indian human skull among them 76% was triangular and 8% was quadrangular. Rest 16% was considered as atypical. [4]

Arvind Yadav et al in 2014 carried the similar research and found the VF in 72.7% specimen. They observed 72.5% triangular and 10% quadrangular and 17.5% atypical vermian fossa. [10]

In the present study the incidence of VF was 80% which is higher than the previous study. The shape of the VF was found triangular in 70.45% bones and quadrangular in 7.95% whereas in 21.59% bones it was atypical type. These findings are lower than finding of Murlimanju et al. and Arvind Yadav et al. The mean height and width of the VF were 13.4 mm and 12.1 mm respectively in our study. A comparative finding of VF between previous and present study is well shown in table 1.

Table 1: A comparative morphological and morphometric findings of vermian fossa.

SN	Author	Incidence	Type 1	Type 2	Type 3	Height (mm)	Width (mm)
1	Berge and Bergman	4 %	-	-	-	-	-
2	Kale et al.	8.2 %	53.84 %	30.76 %	15.38 %	27.8	18.4
3	Murlimanju et al.	71.42 %	76 %	8 %	16 %	13.6	13.9
4	Arbind Yadav et al.	72.7 %	72.5 %	10 %	17.5 %	14.2	12.1
5	Present	80 %	70.45%	7.95%	21.59 %	13.4	12.1

We cannot exclude that this type of morphological and morphometric

differences may be influenced by the small sample size of the present study.

Nonetheless, we believe that data like these ones may be of value in studies or diseases that cause the alteration in shape and size of the vermian fossa. The anatomy of cerebellum, especially the vermis is of interest to many clinicians. It has been reported that some cases of cerebellar cortical dysplasia are associated with vermian malformations. ^[11]

In 2007 Robinson described few criteria to elevate the vermian growth, including vermian biometry and relationship in between superior and inferior lobes of the vermis in fetuses. ^[12] Siebert in 2006 proposed basic morphological definitions of the posterior fossa anomalies, so that better arrangement can be reached between clinical and pathological diagnoses. ^[13]

In neurosurgery, the combined transventricular and supracerebellar infratentorial approach are practiced to remove the midline tumor of posterior fossa. This approach avoids unnecessary splitting of the vermis. ^[14] Due to these reasons of the clinical interest, we believe that the vermian fossa needs to be studied anatomically.

CONCLUSION

Medical progress needs a more accurate knowledge of the variability of human morphology to improve the diagnosis and therapeutic performance. The clinician who operates intracranial or interprets radiological imaging should be aware of the anatomical variations. The incidence of vermian fossa is higher in our study as compared to previous study and it might be because of racial variations. We believe that this study can also provide clue about the shape of the inferior cerebellar vermis. The present study might also help those who are involved with pathologies around foremen magnum, like Arnold chiari malformation. The futures implication of this study includes correlation of the data with surgically relevant considerations.

REFERENCES

1. Bergman R.A, Thompson S.A, Afifi A.K, Saadeh F.A. Compendium of human anatomic variation. Urban & Schwarzenberg; 1988. p:200.
2. Grant JCB and Basmajian JV. Grant's Method of Anatomy. Seventh edition. Baltimore: The Williams & Wilkins Co; 1965. p:720-721.
3. Berge JK, Bergman RA. Variations in size and symmetry of the foramina of the human skull. *Clinical Anatomy* 2001; 14(6):406-413.
4. Murlimanju, BV, Prabhu LV, Sharmada KL, et al. Morphological and morphometric study of the vermian fossa in Indian human adult skulls. *J. Morphological Sci.* 2010; 130(3):148-151.
5. Lang, J. *Clinical anatomy of the posterior cranial fossa and its foramina.* Thieme: New York. 1991; p.6.
6. Standring S. *Gray's Anatomy.* Thirty-ninth edition. Spain: Churchill Livingstone; 2005. p:353-464.
7. East, Cft. A rare abnormality of the occipital bone. *Journal of Anatomy.* 1926; 60(4): 416-417.
8. Berge JK, Bergman RA. Variations in size and symmetry of the foramina of the human skull. *Clinical Anatomy.* 2001; 14:406-413.
9. Kale, A., Oztürk, A., Aksu, F., et.al. Vermian fossa - anatomical study. *Journal of Istanbul Faculty of Medicine.* 2008; 71:106-108.
10. Arvind Yadav, Ketu Chauhan, GL Nigam et al. Morphological And Morphometrical Analysis Of The Vermian Fossa In Dry Adult Skulls Of Western Uttar Pradesh Population: An Osteological Study. *International Journal of Anatomy and Research.* 2014; 2(3):478-80.
11. Soto-Ares, G., Delmaire, C., Deries, B., et al. Cerebellar cortical dysplasia: MR findings in a complex entity. *American Journal of Neuroradiology.* 2000; 21(8):1511-1519.

12. Robinson, AJ. Blaser, S., Toi, A., et al. The fetal cerebellar vermis: assessment for abnormal development by ultrasonography and magnetic resonance imaging. *Ultrasound Quarterly*. 2007; 23(3):211-223.
13. Siebert, JR. A pathological approach to anomalies of the posterior fossa. *Birth Defects Research: A Clinical and Molecular Teratology*. 2006; 76(9):674-684.
14. Hermann, EJ., Rittierodt, M. and Krauss, JK. Combined transventricular and supracerebellar infratentorial approach preserving the vermis in giant pediatric posterior fossa midline tumours. *Neurosurgery*. 2008; 63(1):30-37.

How to cite this article: Ranjan RK, Kataria DS, Yadav U. Vermian Fossa: An Anatomical study of Indian human dry skull. *Int J Health Sci Res*. 2015; 5(8):238-242.

International Journal of Health Sciences & Research (IJHSR)

Publish your work in this journal

The International Journal of Health Sciences & Research is a multidisciplinary indexed open access double-blind peer-reviewed international journal that publishes original research articles from all areas of health sciences and allied branches. This monthly journal is characterised by rapid publication of reviews, original research and case reports across all the fields of health sciences. The details of journal are available on its official website (www.ijhsr.org).

Submit your manuscript by email: editor.ijhsr@gmail.com OR editor.ijhsr@yahoo.com