

*Case Report***Live Healthy Fetus with Coexisting Molar Pregnancy - A Surprise**C. N. Sai Shalini^{1*}, S.Rajendiran^{2*}, M. G. Dhanalakshmi^{3**}, N.Sanjeev Reddy^{2**}, J.Thanka^{2*}

¹Assistant Professor, ²Professor, ³Associate Professor,
*Department of Pathology, **Department of Obstetrics & Gynaecology,
Sri Ramachandra University, Chennai.

Corresponding Author: C.N.Sai Shalini

*Received: 19/06/2015**Revised: 10/07/2015**Accepted: 17/07/2015***ABSTRACT**

A twin gestation comprising of a complete hydatidiform mole and a surviving, healthy coexistent twin is rare. We describe a case of woman who delivered a healthy male infant along with a normal placenta with cord and adjacent molar tissue. Prenatal ultrasound showed a normal fetus with enlarged placenta showing cystic changes. The sonographic differential diagnosis includes placental mesenchymal dysplasia, partial mole and a twin gestation with molar changes. A live male baby was delivered by emergency caesarian section at 29 weeks of gestation. The gross appearance of the placenta showed a normal placenta and adjacent multiple clusters of grape like vesicles. Microscopy of the placenta showed features of a complete mole with adjacent normal third trimester placenta. This favored the diagnosis of twin gestation with a normal male fetus and a molar pregnancy. The pathology, clinical and radiological findings of this rare entity is discussed.

Keywords: complete mole, healthy twin, placental mesenchymal dysplasia, partial mole.

INTRODUCTION

The incidence of twin pregnancy consisting of complete hydatidiform mole and a coexisting fetus ranges from 1 in 22,000 to 1, 00,000 pregnancies. ⁽¹⁾ In this condition, the twin gestation consists of one twin which is a normal fetus with normal placenta and the other twin a complete hydatidiform mole. ⁽²⁾ Radiologically the molar tissue appears as a large cystic mass with multiple hypoechoic spaces. This sonographic appearance is similar to that seen in placental mesenchymal dysplasia and partial mole. The ultrasonographic finding of a large cystic placenta along with a phenotypically well formed fetus is highly

unlikely in molar pregnancy and favours placental mesenchymal dysplasia or a partial mole. ⁽³⁾ We present a case of a large cystic placenta diagnosed radiologically as placental mesenchymal dysplasia which turned out to be a complete mole with a surviving healthy cotwin.

Gross and histopathological examination of placenta is very essential for a definitive diagnosis in cases of placental mesenchymal dysplasia, partial mole and complete mole.

CASE HISTORY

34yr woman G2A1 was admitted to our center at 29 weeks gestation with

elevated blood pressure (180/90mmHg), threatened preterm labour and fetal distress. Her obstetric history included a non consanguineous marriage, infertility for 8yrs, one previous abortion and unsuccessful in-vitro fertilization. On examination the uterine size was equivalent to 32weeks of gestational age. Ultrasound examination revealed an intrauterine gestation with a live active fetus (fetal size corresponds to gestational age). The placenta was visualized as a large cystic mass with multiple cystic spaces. The differential diagnosis was placental mesenchymal dysplasia, partial mole and twin gestation with complete mole. The presence of normal fetus with cystic placenta favored a diagnosis of placental mesenchymal dysplasia. The 2nd trimester anomaly scan was normal and karyotyping of amniocentesis showed a normal 46XY karyotype. In view of the fetal distress and threatened preterm labour an emergency caesarean section was performed. A healthy live male infant weighing 1.6kg was delivered along with the large placental mass. Post partum beta HCG levels showed abnormal increase of above 2, 00,000 IU/L. Serum level of beta HCG decreased remarkably 3 weeks after delivery.

PATHOLOGY:

Gross Examination: We received a large placenta with a cord along with the irregular areas showing grape like clusters, totally weighing 1150gms all together measuring 24X18X11cm. Three vessel umbilical cord measured 22cm. The maternal surface was made up of normal appearing placenta with adjacent multiple glistening grape like clusters typical of a complete mole, comprising 25% of the whole placental volume (Figure 1). The junction between normal appearing placenta and molar vesicles was very distinct. The molar change was not seen involving the normal placental parenchyma. The fetal surface showed

translucent membranes with fetal blood vessels without any prominent dilatation, thrombosis or subamniotic hemorrhage (Figure 2). Serial sectioning of the placental parenchyma showed no evidence of ischemia, infarction, thrombosis or hemorrhage.

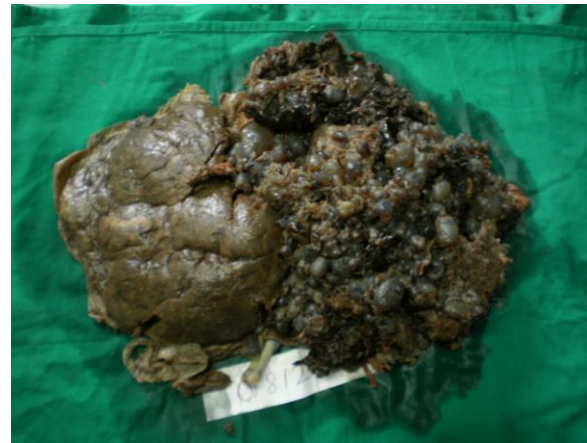

Fig.1 Normal placenta with adjacent multiple glistening grape like clusters

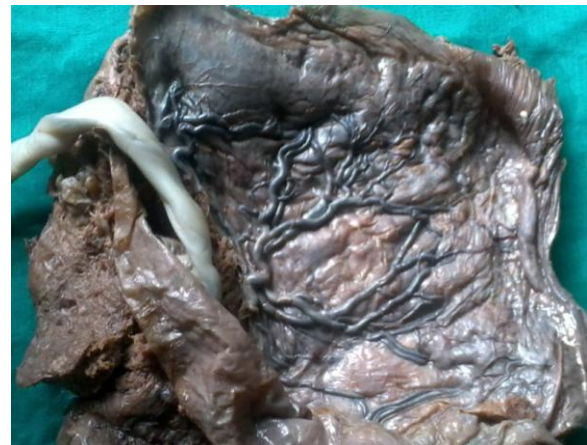

Fig.2 Fetal surface of placenta with thickened vessels

Microscopic Examination: Microscopy of the grossly normal appearing placenta showed mature third trimester villi with normal histology. Sections taken at the junction showed normal and vesicular villi adjacent to each (Figure 3). The grape like clusters demonstrated markedly edematous vesicular villi with circumferential trophoblastic proliferation (Figure 4). Trophoblastic cytological atypia was also

noted No thickened blood vessels were noted within the edematous villi. One umbilical cord identified showed three blood vessels. Membranes were free of inflammation. Gross absence of prominent dilated and thrombosed fetal blood vessels, microscopic presence of edematous villi without thickened fibrotic vessels and presence of circumferential trophoblastic proliferation in the presence of normally developed fetus favored a diagnosis of twin gestation with molar changes.

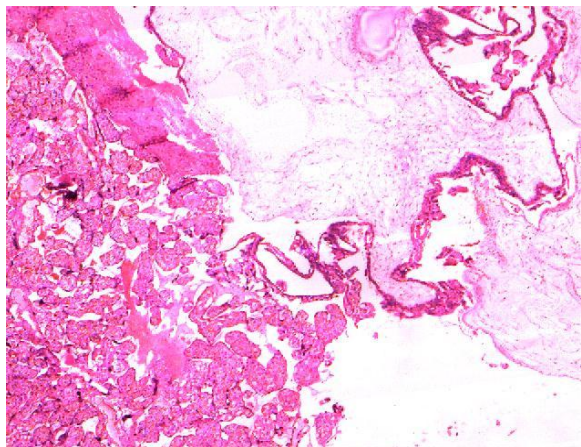


Fig.3 Junction of normal and vesicular villi adjacent to each other

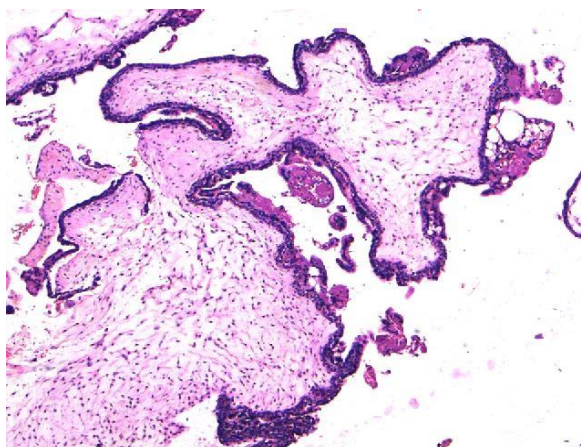


Fig.4 Oedematous vesicular villi with circumferential trophoblastic proliferation

DISCUSSION

The presence of an abnormal placenta with a well developed fetus in an antepartum sonography raises the

differential diagnosis of partial mole and placental mesenchymal dysplasia. The presence of fetus usually rules out the possibility of complete mole but the rare occurrence of twin gestation with a normal fetus and a molar pregnancy always should be included in the differential diagnosis. Pathologic examination of the placenta is a must to come to a definitive diagnosis in this scenario.

Placental mesenchymal dysplasia (PMD) is a relatively recently recognized entity by Moscoso ⁽⁴⁾ et al in 1991. It is a placental vascular anomaly sonographically showing features of partial mole. PMD is associated with Beckwith-Wiedemann syndrome (BWS) and most of the time shows growth restriction of the fetus but can be associated with normal fetus also. The reported incidence of PMD with BWS is 23%. ⁽⁵⁾ As PMD is unfamiliar, underdiagnosed and called by variety of names, the exact incidence is unknown. The reported incidence is 0.02% ⁽⁶⁾ with a female fetus preponderance of 3.6:1. ⁽⁵⁾ There is no specific clinical presentation and most of the PMD are diagnosed incidentally because of the abnormal placenta during the prenatal sonography checkup. In most cases, the diagnosis is made postpartum because of the large abnormal placenta. Sometimes it may present with polyhydramnios, especially if associated with fetal swallowing difficulty as part of BWS. Biochemical abnormality includes raise in maternal alpha feto protein (AFP) with normal or mildly elevated beta HCG that returns to normal soon after the delivery. The raised AFP is of fetal origin. This is predicted due to increased transfer from the fetus to maternal circulation through enlarged placenta and increase blood vessels in the fetal stem villi. A thickened and enlarged placenta with hypoechoic spaces are noted by ultrasound and the differential diagnosis includes both partial and complete mole and others like

chorangiomas and subchorionic hematoma. (7) One can note the migration of cystic spaces towards chorionic plate with aneurysmally dilated chorionic vessels as the pregnancy advances in cases of PMD.

In PMD, at gross examination, the placenta is large with aneurysmally dilated, tortuous chorionic plate blood vessels with abnormal branching. (8) Luminal thrombosis or subamniotic hematoma due to rupture of the blood vessels can be present. Cut surface of the placental parenchyma will show pale and friable areas with streaks of prominent stem villi and multiple grape like vesicles oriented perpendicular to chorionic plate. Microscopic examination will be highlighted by dilated and thick walled chorionic plate vessels with fibromuscular hyperplasia with or without fresh or organizing thrombus. The stem villi will be enlarged with central gelatinous cisterns and fibromuscular vessels at the periphery. Terminal villi may also show mesenchymal hypercellularity and stromal fibrosis. Scattered normal appearing and hydropic secondary and tertiary villi will be noted. Most importantly, there will not be any trophoblastic proliferation or stromal trophoblastic inclusions.

The maternal complications of PMD include polyhydramnios, gestational diabetes, preeclampsia, and rarely microangiopathic hemolytic anemia due to abnormal shunting of blood. (9) The fetal complication can be divided in to those associated with BWS like hyperinsulinemic hypoglycemia and those occurring in phenotypically normal fetus like prematurity, growth retardation and in extreme case, fetal demise. (10,11) In a study, a five year follow up of mothers with PMD failed to show signs of trophoblastic disease or recurrence of PMD in subsequent pregnancies. (12) But rare recurrence is possible in cases associated with BWS as 15% of them are familial. The exact etiology of PMD is unknown and the proposed idea

is that of fibroblastic and vascular proliferation due to hypoxia and hypoperfusion.

Presence of fetus with abnormal placenta always should raise the suspicion of partial mole. The triploid fetus associated with a partial mole may show growth restriction with a variety of external and internal defects. The examination of placenta shows club shaped villi that are more elongated rather than round when compared to complete mole. Microscopic examination will be characterized by 2 populations of villi, normal admixed with hydropic villi showing stromal trophoblastic inclusions, scalloping and trophoblastic proliferation. No cytological atypia of the trophoblasts present. Triploid karyotype is necessary to confirm the diagnosis in difficult cases. Clinical follow up is warranted in partial moles as persistence, recurrence or metastatic gestational trophoblastic disease can occur even though the incidence is very rare (0.5 to 4%).

The traditional teaching of “presence of fetus.....rules out the diagnosis of complete mole” has to be interpreted cautiously. This can happen as in our case very rarely in cases of twin gestation. The incidence of twin pregnancy consisting of complete hydatidiform mole and a coexisting fetus ranges from 1 in 22,000 to 1, 00,000 pregnancies. The theoretical explanation is that of a dizygotic pregnancy with one twin has developed normally and the other has degenerated into a complete mole. The presence of normal placenta with sharply defined molar tissue in both gross and microscopic examination favors the diagnosis of twin pregnancy with a normal fetus and coexisting mole. Clinically in these, like in our case the beta HCG level will be high when compared to non molar twin pregnancy. Gross and microscopic diffuse involvement of the placenta with single population enlarged round hydropic

avascular villi showing trophoblastic proliferation with cytologic atypia favors a diagnosis of complete mole over partial mole. It is very important to differentiate a complete mole and a partial mole when a fetus coexist as complete mole has a 20% tendency to become an invasive mole or even a choriocarcinoma, while the risk is far less for partial mole.

Vijerslev in the review of 113 reports of twin pregnancies with fetus and molar changes documented, 87 had intended to continue the pregnancy with or without the knowledge of coexisting molar pregnancy. Of the pregnancies that continued beyond the 28th week, a surviving child was expected in 70%. Persistent trophoblastic disease was reported in 19.2% of pregnancies interrupted at diagnosis and 9.1% of those who continued. In addition there is no report in which increased incidence of invasive mole or choriocarcinoma development even when the pregnancy is kept to term.

CONCLUSION

Presence of normal fetus with placental abnormality showing cystic hypoechoic changes raises the differential diagnosis of PMD, partial mole and dizygotic twin pregnancy with a normal fetus and coexisting complete mole. Thorough sonographic, genetic and pathological examination of placenta is very essential for a definitive diagnosis as it has a pivotal role in close clinical follow up and evaluation of the patient in the prenatal and postnatal period.

REFERENCES

1. Malhotra N, Deka D, Takkar D, Kochar S, Goel S, Sharma MC. Hydatiform mole with coexisting live fetus in dichorionic twin gestation. *Eur J Obstet Gynecol Reprod Biol* 2001; 94: 301-3.

2. Berkowitz RS, Goldstein DP. Management of molar pregnancy and gestational trophoblastic tumors. In: Knapp RC, Berkowitz RS, eds. *Gynecologic Oncology*. 2nd Ed. New York: Mc Graw Hill. 1992:328-38.
3. Zahida Parveen, Jane Elaine Tongson-Ignacio, Cory R. Fraser, Jeffery L. Killeen and Karen S. Thompson. Placental Mesenchymal Dysplasia. *Arch Pathol Lab Med* 2007; 131:131-137.
4. Moscoso, G., E. Jauniaux, and J. Hustin. Placental vascular anomaly with diffuse mesenchymal stem villous hyperplasia: a new clinico-pathological entity? *Pathol Res Pract* 1991; 187:324-328.
5. Cohen, M. C., E. C. Roper, N. J. Sebire, J. Stanek, and D. O .C. Anumba. Placental mesenchymal dysplasia associated with fetal aneuploidy. *Prenat Diagn* 2005; 25:187-192.
6. Arizawa, M and M. Nakayama. Suspected involvement of the X Chromosome in placental mesenchymal dysplasia. *Cong Anomal* 2002; 42:309:317.
7. Reinhart, R. D., W. A. Wells, and R. D. Harris. Focal aneurysmal dilatation of subchorionic vessels simulating chorioangioma. *Ultrasound Obstet Gynecol* 1999; 13:147-149.
8. Paradinas, F. J, N. J. Sebire, and R. A. Fisher et al. Pseudo-partial moles: placental stem vessel hydrops and the association with Beckwith-Wiedemann syndrome and complete moles. *Histopathology* 2001. 39:447-454.
9. Benirschke, K and P. Kaufmann. *Pathology of the Human placenta*. 4th ed. New York, NY: Springer Verlag; 2000.
10. Kuwabara, Y, Y. Shima, T. Araki, and S. Shin. Mesenchymal stem villus hyperplasia of the placenta and fetal growth restriction. *Obstet Gynecol* 2001; 98: 940-943.
11. Ohyama, M, T. Kojyo, H. Gotoda, T. Sato, R. Ijiri and Y. Tanaka. Mesenchymal dysplasia of the placenta. *Pathol Int* 2000; 50:759-764.

12. Matsui, H, Y. Litsuka, and K. Yamazawa. et al. Placental mesenchymal dysplasia initially

diagnosed as partial mole. Pathol Int 2003; 53: 810-813.

How to cite this article: Shalini CNS, Rajendiran S, Dhanalakshmi MG et. al. Live healthy fetus with coexisting molar pregnancy - a surprise. Int J Health Sci Res. 2015; 5(8):693-698.

International Journal of Health Sciences & Research (IJHSR)

Publish your work in this journal

The International Journal of Health Sciences & Research is a multidisciplinary indexed open access double-blind peer-reviewed international journal that publishes original research articles from all areas of health sciences and allied branches. This monthly journal is characterised by rapid publication of reviews, original research and case reports across all the fields of health sciences. The details of journal are available on its official website (www.ijhsr.org).

Submit your manuscript by email: editor.ijhsr@gmail.com OR editor.ijhsr@yahoo.com