



Case Report

Primary Mucosal Malignant Melanoma of Middle Ear - A Case ReportHavle Abhay D^{1*}, Havle Padmaja A^{2**}, M D Fazal Ahmed^{3*}, Patil Nanda J^{4***}, Havle Pranav A⁵¹Professor, ²Assistant Professor, ³Resident, ⁴Associate Professor, ⁵UG Student,
*Department of ENT, **Department of Obstetrics & Gynecology, ***Department of Pathology,
KIMSU, Karad

Corresponding Author: Havle Abhay D

Received: 10/06/2015

Revised: 30/06/2015

Accepted: 01/07/2015

ABSTRACT

Malignant melanoma is neoplastic lesion of skin and mucus membrane originating from melanocyte. The mucosal variant of melanoma in head and neck is uncommon. The overall incidence of the malignant melanoma is < 0.002%, of which the mucosal type is less than 1%. The mucosal variant arising from the middle ear is extremely rare. We present a case of 56-year-old male having left sided ear discharge, LMN type of facial nerve palsy and mass in the EAC-mucosal malignant melanoma with no involvement elsewhere.

Keywords: Facial nerve palsy, Melanocytes, Middle ear melanoma, Mucosal malignant melanoma.

INTRODUCTION

Malignant melanoma of the temporal bone may emanate from the squamous epithelium of the auricle and the external auditory canal (EAC), or very rarely from the mucosa of the middle ear and the

mastoid cavity. ^[1-4] It can arise as a primary lesion or as a result of metastasis. Very few histopathologically diagnosed cases of malignant melanoma of the middle ear mucosa (ref. Table-1) are reported in the literature ^[2-9] and hence this presentation.

Table-1: The reported cases of primary malignant melanoma of the middle ear

Authors	Year	Number of Cases
Peters G, Arriaga MA	2012	1
Özmen ÖZTÜRK, Tekin BALAM et al.	2006	1
B.S. Mehata, et al	2006	1
Oueslati Z, et al. ^[5]	2001	1
Uchida M and Matsunami T ^[3]	2001	1
Urpegui Garcia A, et al. ^[6]	1999	1
Banerjee A, Meikle D. ^[7]	1992	1
Sherman IW, et al. ^[4]	1991	1
McKenna EL Jr, et al. ^[2]	1984	1
Kagan AR, et al. ^[8]	1982	1
Muir CS, Nectoux J. ^[9]	1980	1

CASE REPORT

A 56-year-old man presented with ear discharge, mass in left ear and left side

facial weakness since 15 days. The other associated symptoms were ear ache, aural fullness, hearing loss, and tinnitus in left ear.

There was history of pulmonary tuberculosis for which he was treated 2 years ago.

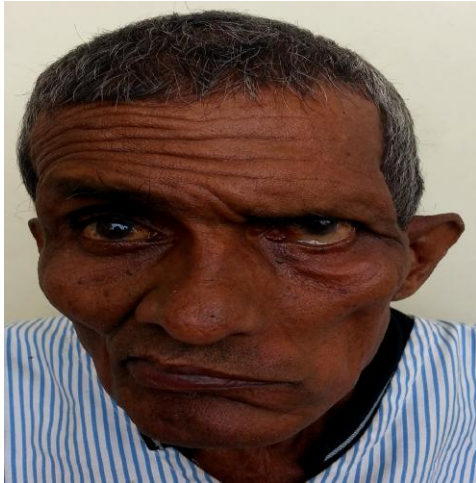

Fig.1: Clinical photo-Left LMN type Facial palsy

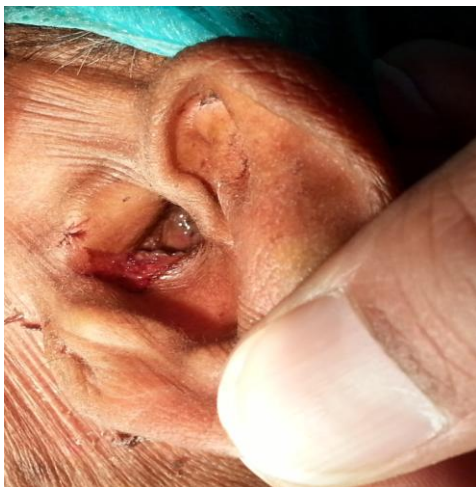

Fig.2: Clinical photo- mass in left ear

Clinical examination of left ear revealed anaemia, left LMN type of facial nerve palsy (Fig.1) and sero-purulent ear discharge and dark purple black coloured mass filling the left EAC (Fig. 2), with mixed type of hearing loss on tuning fork testing. The opposite ear was normal. The neck was free of any palpable cervical lymphadenopathy. Additionally, the clinical examination as well as abdominal ultrasonography for any pigmented skin lesions, suspicious nevi or any mass was negative. Systemic examination was within normal limits. The micro-otoscopy revealed

dark black mass arising from middle ear protruding into EAC with no involvement of the skin of the EAC. The mass was removed in piece meal (Fig.3) and sent for histopathological examination.

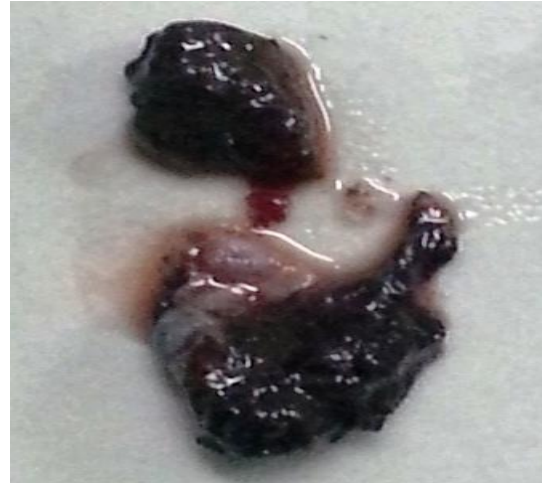

Fig. 3: Gross appearance of mass from left ear

Mixed type hearing loss with an air-bone gap of 60 dB in left ear was noted at PTA.

The high-resolution computed tomography (CT) of the temporal bone showed an irregular mass of soft tissue density, filling the tympanum and the EAC, the mass appeared confluent with the ossicles and tympanic membrane as they could not be made out separately.

Gross appearance of the tissue sent for HPE revealed multiple soft, friable blackish, bits of irregular mass of 3x4 cm in size all together (Fig.3). The microscopic examination with haematoxylin and eosin staining showed diffusely distributed sheets of spindle to polygonal shaped cells, pleomorphic hyperchromatic nuclei, prominent nucleoli with moderate amount of cytoplasm and brownish-black melanin pigment (Fig.4, 5). The tumour cells are arranged in fascicles and nests. The melanin pigment was confirmed after melanin bleach (Fig.6).

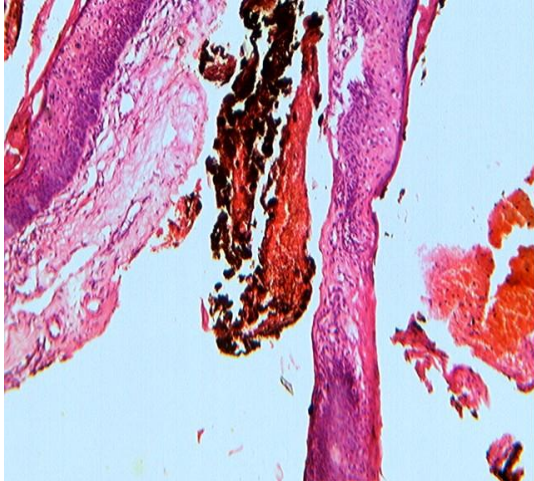


Fig.-4: haematoxylin and eosin Staining the appearance of diffusely distributed sheets of spindle to polygonal shaped cells seen.

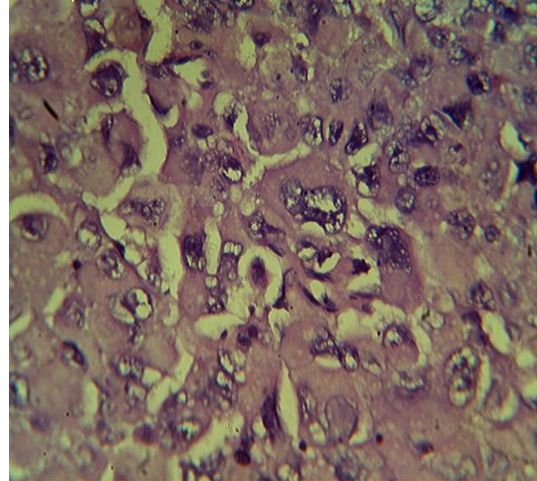


Fig.-6: HPE appearance after melanin

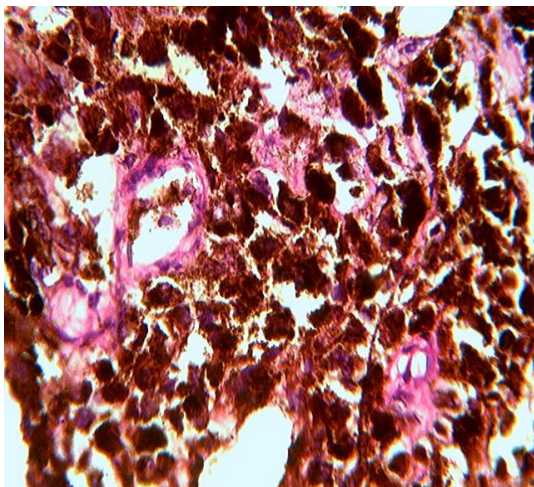


Fig.-5: HPE before melanin bleach Showing-Pleomorphic hyperchromatic nuclei, prominent nucleoli with moderate amount of cytoplasm and brownish black melanin pigment

Bone scintigraphy and computerized tomography of thorax and abdomen done and metastasis to other areas was ruled out. All blood, urine and liver function tests revealed no abnormality except anaemia. Finally, the diagnosis of primary mucosal malignant melanoma of the middle ear was established by positive histopathological findings and negative systemic as well as abdominal ultrasound examination findings.

TREATMENT

Extensive surgical wide excision is the treatment of choice for mucosal malignant melanoma combined with radiotherapy with high dose fractions. [10,11] However, in our case in view of poor prognosis of the disease as well as due to financial constrains and related family problems, the patient and his close relatives were not willing for any further workup and the treatment. Unfortunately the patient therefore was lost to follow up.

DISCUSSION

Malignant melanoma is malignancy primarily affecting the skin. It could be either cutaneous or mucosal type. Mucosal malignant melanoma of head and neck is uncommon as very few cases have been reported in the world literature till date. It can arise as a primary lesion or as a result of metastasis. Amongst the cases contributing to the mucosal malignant melanoma, the type thought to be arising from middle ear mucosa is extremely rare and rarely reported (ref. Table-1). [2-9]

In terms of proportion of all melanomas, primary mucosal melanomas of the head and neck represent < 1% of the total. [12] Cutaneous malignant melanoma of the auricle is thought to arise as a result of

intense sun exposure, but the specific similar pathophysiological factors underlying the development of the primary malignant melanoma of the middle ear mucosa and the deep EAC are not known, however the genetic predisposition and patient's phenotype are thought to be the parts of aetiology. [1,13] These patients often have presenting features such as long-standing otalgia, otorrhea, blood stained discharge and loss of hearing similar to chronic infections of the EAC and middle ear. [14] However, initially the lesion tends to remain asymptomatic due to the fact that it is deeply situated. [14] Therefore the diagnosis is often delayed. The diagnosis of malignant melanoma is established by histopathological examination of the suspicious lesion. [3] Pathologic diagnosis of melanoma hinges on the identification of intracellular melanin, [3] which was seen in our case too. Successful management of a melanoma depends on the early recognition. The CT temporal bone and neck helps in assessment of exact extension to neighbouring structures. Routine metastatic workup should include a thoraco-abdominal radiograph, radionuclide bone scan and liver function tests. [13]

Due to extremely low incidence of occurring the definite guidelines regarding management of mucosal melanoma of ear are lacking. Surgery currently is the best choice for cure of malignant melanoma of the head and neck. [13] The surgical management of the head and neck melanomas is often limited as the lesion is frequently inaccessible leading to delay in diagnosis, there is often anatomical difficulties in obtaining a wide surgical excision margin. [14] Extension of the tumour into the mastoid cavity and EAC may necessitate concomitant subtotal temporal bone resection, mastoidectomy, and parotidectomy. [14] Careful surgical planning minimizes the cosmetic and

functional consequences of extensive wide surgical excision and decrease the tumour burden. The nodal status is one of the most important predictors of survival. The removal of occult metastatic disease by various dissections of the neck reduces the incidence of recurrence. [15] The extension of neck dissection to include periparotid lymph nodes is essential. The technique of lymphoscintigraphy and sentinel lymph node biopsy to identify patients with non palpable lymph node metastases may greatly increase the yield of elective lymph node dissection. [15] Radiation therapy may play an increasing role in the treatment of patients with unresectable local disease or those who refuse surgery. Radiation therapy is not effective in completely eradicating the tumour and improving the overall survival, but improves regional disease control. [13] Chemotherapy has been generally reserved for patients with systemic disease. Dacarbazine (DTIC) and nitrosoureas have been the mainstays of chemotherapy. [13] Immunotherapeutic agents (interferon and interleukin-2).

The vaccines against melanoma associated antigens remain a promising hope.

CONCLUSION

Though the malignant melanoma of the middle ear and mastoid cavity is extremely rare which remains asymptomatic initially, it is required to be aware of it for early diagnosis and management. It is important to discuss the poor outcome of patient survival and high morbidity due to extensive resections as well as need for expensive chemotherapy and or adjunctive radiotherapy.

The high index of suspicion may be useful for early recognition, before actually making the decision on a treatment plan.

REFERENCES

1. Langman A, Yarrington T, Patterson SD. Malignant melanoma of the external auditory canal. *Otolaryngol Head Neck Surg* 1996; 114:645-8.
2. McKenna EL Jr, Holmes WF, Harwick R. Primary melanoma of the middle ear. *Laryngoscope* 1984; 94(11 Pt 1):1459-60.
3. Uchida M, Matsunami T. Malignant amelanotic melanoma of the middle ear. *Arch Otolaryngol Head Neck Surg* 2001; 127:1126-8.
4. Sherman IW, Swift AC, Haqqani MT. Primary mucosal malignant melanoma of the middle ear. *J Laryngol Otol* 1991; 105:1061-4.
5. Oueslati Z, Touati S, Gritli S, el-May A, Benna F, Boussen H, et al. Mucous malignant melanoma of the neck and face. Experience at the Salah Azaiz Institute (Tunis). *Rev Laryngol Otol Rhinol (Bord)* 2001; 122:237- 40. [Abstract]
6. Urpegui Garcia A, Lahoz Zamarro T, Muniesa Soriano JA, Valles Varela H, Martinez Subias J, Sancho Serrano E, et al. Malignant melanoma of the middle ear, a rare site. *Acta Otorrinolaringol Esp* 1999; 50:559-62. [Abstract]
7. Banerjee A, Meikle D. Malignant melanoma of the middle ear. *J Laryngol Otol* 1992; 106:581.
8. Kagan AR, Stechel RJ, Allan M. Diagnostic oncology case study. *AJR Am J Roentgenol* 1982; 138:943-4.
9. Muir CS, Nectoux J. Descriptive epidemiology of malignant neoplasms of nose, nasal cavities, middle ear and accessory sinuses. *Clin Otolaryngol* 1980; 5:195-211.
10. Habermalz et al (1976) Radiation therapy of malignant melanoma: Experience with high individual treatment doses. *Cancer*, 38 ; 2258-2262
11. Snow et al (1986) mucosal melanomas of the head and neck. *Otolaryngologic clinics of north America*, 19:3
12. Manolidis S, Donald PJ. Malignant mucosal melanoma of the head and neck: review of the literature and report of 14 patients. *Cancer* 1997; 80:1373-86.
13. Beaver ME, Chang CYJ. Melanoma. In: Jackler RK, Driscoll CLW, editors. *Tumors of the ear and the temporal bone*. Philadelphia: Lippincott Williams &Wilkins, 2000. p. 56-66.
14. Leonetti JP, Marzo SJ. Malignancy of the temporal bone. *Otolaryngol Clin North Am* 2002; 35:405-10.
15. Wagner JD, Park HM, Coleman JJ 3rd, Love C, Hayes JT. Cervical sentinel lymph node biopsy for melanomas of the head and neck and upper thorax. *Arch Otolaryngol Head Neck Surg*. 2000 Mar; 126(3): 313-21

How to cite this article: Abhay DH, Padmaja AH, Ahmed MDF et. al. Primary mucosal malignant melanoma of middle ear - a case report. *Int J Health Sci Res*. 2015; 5(8):648-652.
