

*Case Report*

Severe Osteomalacia and Malnutrition: Many a Slip between the Cup and the Lip - A Case Report Based Discussion

Mohammad Nasim Akhtar¹, Sharat Agarwal²¹Assistant Professor, Dept. of Orthopaedics & Trauma,
ESI PGIMSR, ESIC Medical College & ESIC Hospital, The West Bengal University of Health sciences, Kolkata.²Associate Professor, Department of Orthopedics & Trauma,
North Eastern Indira Gandhi Regional Institute of Health & Medical sciences (NEIGRIHMS),
Shillong (Meghalaya) India -793018

Corresponding Author: Sharat Agarwal

*Received: 07/05/2015**Revised: 07/06/2015**Accepted: 11/06/2015*

ABSTRACT

A female patient of 27 years of age presented with low backache, diffuse bone pains, muscle weakness of both hips with bilateral trochanteric tenderness. Radiograph of the pelvis revealed bilateral coxa vara and Looser's zones. Diagnosis of osteomalacia with secondary hyperparathyroidism was well-established with further support of blood biochemistry findings. The patient was subsequently treated with Cholecalciferol and calcium supplementation with clinical and biochemical resolution. Such a severe deficiency of vitamin D with clinico-radiological and biochemical features, without any contributory medical co-morbidity in otherwise healthy adult is, generally, not anticipated in this era of scientific awareness. We have discussed the socio-cultural evolution of vitamin D along with diagnostic and therapeutic aspects of hypovitaminosis D. The non-skeletal benefits of optimum vitamin D status have also been highlighted.

Keywords: Osteomalacia, Vitamin D deficiency, malnutrition, nutritional bone disease.

INTRODUCTION

Vitamin D is also known by the terms 'the sunshine vitamin' or 'the sunlight hormone' which is justifiable due to obvious reasons. Recent literature is witnessing renewed interest in Vitamin D because the emerging data is indicating its benefits beyond healthy bones and musculoskeletal system. Osteomalacia results from failure of mineralization of organic osteoid formed by osteoblasts and it is also referred as 'adult rickets'. The nutritional osteomalacia has many natural to manmade causes like, living

in specific geographic location, limited source of vitamin D containing natural foods, lack of vitamin D fortified foods etc., and ignorance and poverty further accentuate the problem. This case report and the accompanying discussion highlight the presence of severe deficiency of vitamin D due to malnutrition, which is still prevalent in Indian population, which would have been preventable by proper health education and austerity measures that include optimum fortification of foods.

CASE REPORT

A 27 year old housewife with no history of any previous illness, presented with one year history of diffuse bone pains, low back ache, generalised weakness and difficulty in walking. She was a non-vegetarian and was from poor socioeconomic status. There was no history of any trauma, significant fever, loss of appetite or weight, loose motion, swelling of face, limbs or joints and altered sensation in limbs. Family history was non-contributory.

Clinical examination revealed conjunctival pallor, height 158 cm and weight 48 kg. The blood pressure was 130/80 mmHg and the pulse rate was 76/min. she was walking with waddling gait. No spinal tenderness or deformity was noted. Examination of pelvis revealed bony tenderness over bilateral trochanters. Active straight leg raising was possible but painful. There was no Scarpa's triangle tenderness. Movements of bilateral hips were painfully restricted terminally, especially abduction. Neurological examination revealed grade 3 to 4 power in all muscle groups of both hips with no sensory or reflex deficit. Neurological examination of upper limbs and distal muscle groups of both lower limbs were normal.

Antero-posterior radiograph of pelvis revealed (Fig. 1) bilateral coxa vara (arrow) with evidence of Looser's zones (arrowheads) at both femoral neck and left proximal femur. Blood investigations revealed serum calcium of 1.1 mmol/L, serum phosphorus 1.2 mg/dl, serum alkaline phosphatase 1046 U/L with normal blood urea, serum creatinine and random blood sugar levels. Parathyroid hormone assay revealed 174.53 pg/ml and 25(OH) vitamin D 5 ng/ml. Serum proteins were normal. Haemoglobin was 10.0 g/dl and erythrocyte sedimentation rate was 22 mm in first hour with normal total and differential leucocyte counts. Diagnosis of nutritional

osteomalacia with secondary hyperparathyroidism was made and patient was subsequently treated with oral cholecalciferol 60,000 IU twice weekly with total doses of 6 lakh units spread over 5 weeks with daily 1 gm of elemental calcium. Patient was also provided with dietary consultation and proper health education along with rehabilitative physiotherapy. Decreasing trend in alkaline phosphatase (ALP) was noted within one month with resolution of bone pains and subsidence of generalised weakness, with complete normalization of ALP in 4 months. Serum phosphorus level was normalized by second month of starting treatment. At the end of 9 months patient had full functional recovery albeit with some difficulty in squatting. Physiotherapy and rehabilitation continued.

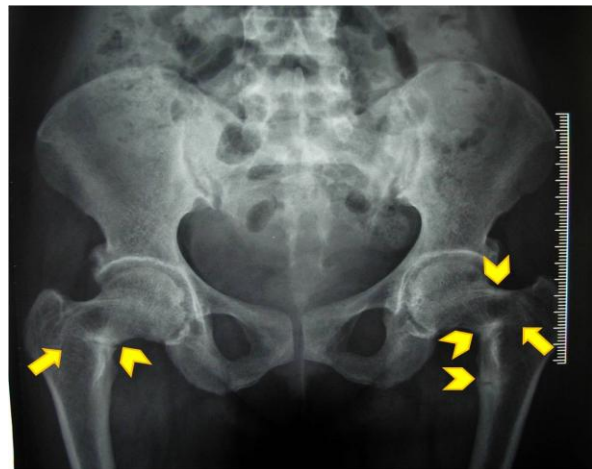


Figure 1, showing bilateral coxa vara (arrow) with pseudofractures called Looser's zone (arrowheads).

DISCUSSION

The road to the discovery of vitamin D began with recognition of the childhood metabolic bone disease of rickets. The first formal medical treatise on Vitamin D deficiency diseases was published by Francis Glisson, Professor of Physics at University of London in 1650, and this medical discourse is still unsurpassed in its clinical description of the disease. [1] During the industrial revolution of the 1800s, the

prevalence of rickets increased dramatically among children who lived in crowded, polluted and dimly-lit urban areas. Human inquisitiveness further lead to expansion of knowledge related to dietary and nutritional aspects of vitamin D. In 1917, Hess and Unger described the prevention of rickets in children in New York City by administration of cod liver oil or by ultraviolet irradiation of food. [2] Around 1922, McCollum and co-workers [3,4] and Shipley and associates isolated the first of the vitamin D's, and subsequently a number of investigators established the various members of the vitamin D family and the relationship of 7-dehydrocholesterol to calciferol, [5,6] By the end of the 1920's rickets and osteomalacia were considered to be deficiency diseases, and were potentially curable and preventable by the addition of vitamin D to the diet. [7,8] These discoveries finally led to the fortification of milk and other foods with vitamin D in the 1930s, and as a result of which rickets virtually disappeared in North America and Europe. But, unfortunately, India and other developing countries are still fighting the menace of these bone diseases emanating from nutritional deficiency of vitamin D, and nutritional osteomalacia is the commonest among them. As per the surveys conducted in India, 52 % of the population surveyed had the evidence of nutritional bone diseases. [9-11] This fact becomes more worrisome and questions our attitude towards health education when reports documenting vitamin D deficiency even in doctors and nurses from northern latitude of India are encountered. [12,13] These facts are also supported by authors from Southern part of the country. [14] The geographic prevalence of osteomalacia shows that the women residing in the northern parts of India were heavily affected then those living in southern parts of the country. This difference in the incidence of osteomalacia is due to North-South gradient

of the solar ultraviolet radiations (UVR-B, 219-315 nm) which are essential for the endogenous cutaneous synthesis of vitamin D3. [15] Synthesis of vitamin D3 in the skin is reduced by residence at northern latitudes distant from the equator and atmospheric pollution. [16,17] The clinical diagnosis of osteomalacia in an adult is often subtle and is considerably more difficult to establish than that of rickets in a child. [7,18,19] The classic symptoms of osteomalacia are low back pain, generalised bone pains and tenderness, muscle weakness especially of proximal limb girdle, difficulty in walking, rising without support and climbing stairs, and classic duck-like (waddling) gait due to proximal myopathy, and in severest form, tetany. These symptoms may mimic fibromyalgia, polymyalgia, early rheumatoid arthritis, or even psychosomatism. Because unmineralized osteoid tissue is soft, it is unable to resist weight bearing or mechanical loads, which leads to crippling deformities in patients with severe osteomalacia. Skeletal deformities such as kyphoscoliosis, protrusion acetabuli and limb bowing occur very late in the disease. [20] Patients with osteomalacia have clinical, biochemical and haematological markers of generalised malnutrition along with hypocalcaemia, hypophosphataemia, low serum 25(OH) D and secondary hyperparathyroidism with significantly raised serum parathyroid hormone (PTH) concentration, increased urinary cyclic AMP excretion, increased tubular calcium reabsorption and decreased tubular phosphate reabsorption. Serum 25(OH)D is usually low or unmeasurable, 1,25(OH)2D levels are usually reduced or undetectable and 24 h urinary calcium excretion is low. Raised serum alkaline phosphatase is the marker of metabolic bone disease. Serum concentration of 25(OH)D is the best indicator for judging the vitamin D status in patients with vitamin D-related disease

states. [21] The most diagnostic biochemical feature of osteomalacia is a decreased serum 25(OH)D in the presence of secondary hyperparathyroidism with unequivocally raised serum parathyroid hormone level.

Radiological changes in bone results from impaired mineralization and secondary hyperparathyroidism due to calcium deficiency. The unusual and pathognomonic features of the osteomalacic syndromes is the presence of Milkman's pseudofractures, also known as Looser's zones. The characteristic locations of these symmetrical, transverse, ribbon-like zones of decreased density are present at the concave side of the long bones, the medial side of the neck of the femur, the pubic rami, the ribs, clavicles, and axillary borders of the scapulae. They are usually associated with local tenderness and pain on activity. The triradiate pelvis with multiple, symmetrical Looser's zones in the ischio-pubic rami without the callus in the absence of treatment, is diagnostic of osteomalacia. [22-25]

Other features include symmetrical vertebral biconcavity and findings of high bone turnover as intracortical porosity, cortical striations in the metacarpals and phalanges. Reduction in bone density is the non specific observation. Vertebral compression fractures, femoral and true fractures do not occur in osteomalacia unless complicated by tertiary hyperparathyroidism with osteitis fibrosa. In the early stages of the disease the characteristic features of osteomalacia may not occur and the ultimate diagnosis in such cases is only possible on histomorphometric measurements of bone, which allow direct observation of the state of mineralization and dynamics of bone turnover. [26]

Objectives of treatment include subsidence of clinical symptoms and signs, radiological and histological healing of bone disease which has developed due to the deficiency of 25(OH)D, with normalization

of biochemical abnormalities, and achievement of adequate vitamin D nutrition status and suppression of secondary hyperparathyroidism.

For osteomalacia patients with deficient vitamin D intake, treatment involves 50,000 – 60,000 IU of vitamin D once or twice per week, plus 1 g of elemental calcium per day until blood parameters returned to normal. This usually occurs within 6 months. Patients with liver disease and impaired 1,25 dihydroxy-vitamin D synthesis can be treated with daily oral doses of 1,25 dihydroxy-vitamin D supplement (0.25-1 mg/day). The prognosis is good if treatment is appropriately directed at the underlying aetiology. [27]

Low serum calcium is the earliest abnormality to appear and to return to normal. Looser's zone is the first radiological finding and is the most rapid to heal (2-3 wk). Normalization of serum 25(OH)D and calcium and increase in urinary calcium excretion with disappearance of aminoaciduria are the important biochemical indices of healing osteomalacia. Raised serum parathyroid hormone, alkaline phosphatase and histological evidence of osteomalacia are the early abnormalities and resolve slowly. Hyperplastic parathyroid glands undergo very slow involution and may not involute completely in one's lifetime and remain a constant risk to evolve into an autonomous adenoma (tertiary hyperparathyroidism). Prevention of osteomalacia and rickets is only through ultraviolet (290 to 315nm) sunbath everyday for minimum 30 min of unprotected skin or 400 to 800IU of vitamin D3 orally per day. [28]

Unfortified foods naturally containing vitamin D are limited. The best sources are animal products and more particularly fatty fish and liver extracts, like salmon or sardines and cod liver oil. [29,30]

Vitamin D-fortified food sources in some developed countries include – milk and milk products, orange juice, breakfast cereals and bars, grain products, infant formulas and margarines. It is being done by some of the commercial establishments in India, though on unregulated scale. Country-wide preventive intervention, in the form of milk and edible oil fortification with vitamin D coupled with health education pertaining to proper nutrition would further enhance bone mineral metabolic health in India. Considering the magnitude and country-wide spread of such dysfunction and disorders, preventive measures of the type sighted are of urgent national need. ^[31]

The non-skeletal health benefits of optimum vitamin D status include cancer chemoprevention, ^[32] activation of the innate immune system, decrease in the risk of autoimmune diseases, ^[33] better metabolism with optimum cardiovascular health and prevention of diet-induced obesity, ^[34-40] improvement of muscle function of elderly and reduction in the risk of falls by about 20%, ^[41] and decreased mortality. ^[42-44]

CONCLUSION

Musculoskeletal and other health benefits of optimum vitamin D status is best served by proper health education combined with optimum daily intake of vitamin D. Fortification of foods which should be affordable to Indian population is the need of the hour.

REFERENCES

1. Glisson, f.: *de rachitide sive morbo puerili qui vulgo the rickets dicitur tractatus. Adscitis in operis societatem georgio bate et ahasuero regemortero.* London, G. Du-gardi, 1650.
2. Hess, A. F., unger, L. J.: *Prophylactic Therapy for Rickets in a Negro*

- Community. *J. Am. Med. Assn.*, 69: 1583-1586, 1917.
3. Mccollum, E. V. ; simmonds, N. ; shipley, P. G.; and park, E. A.: *Studies in Experimental Rickets. I. The Production of Rachitic and Similar Diseases in the Rat by Deficient Diets.* *J. Biol, Chem.*, 45: 333-342, 1921.
4. Mccollum, E. V. ; Simmonds, Nina; Becker, J. E. ; and Shipley, P. G.: *Studies in Experimental Rickets. XXI. An Experimental Demonstration of the Existence of a Vitamin Which Promotes Calcium Deposition.* *J. Biol. Chem.*, 53: 293-312. 1922.
5. Steenbock, H., and Black, Archie: *Fat Soluble Vitamins. XXIII. The Induction of Growth-Promoting and Calcifying Properties in Fats and Their Unsaponifiable Constituents by Exposure to Light.* *J. Biol. Chem.* , 64: 263-298, 1925.
6. Windaus, A.: *Chemistry of Irradiated Ergosterol.* *Proc. Roy. Soc. Med.*, 108: 568-570, 1931.
7. Hess, A. F.: *Rickets, Including Osteomalacia and Tetany.* Philadelphia, Lea and Febiger, 1929.
8. Park, E. A.: *The Etiology of Rickets.* *Physiol. Rev.* , 3: 106-163, 1923.
9. Teotia SPS, Teotia M. *Epidemiology of Disorders of Bone and Bone Mineral Metabolism (India).* In: Teotia SPS, Teotia M, editors. *Nutritional and metabolic bone and stone disease: Asian perspective*, First Edition, New Delhi: CBS Publishers, 2008. p. 214-20.
10. Teotia SPS, Teotia M. *Endemic bone disease and deformities consequent to disorders in nutrition, bone and mineral metabolism and related hormones.* Published report. New Delhi: Indian Council of Medical Research, 1996. p. 1-111.
11. Teotia SPS, Teotia M. *Nutritional bone disease.* In: Teotia SPS, Teotia M, editors. *Nutritional and metabolic bone and stone disease: Asian perspective*, First Edition, New Delhi: CBS Publishers, 2008. p. 221-321.

12. Harinarayan CV, Gupta N, Kochupillai N. Vitamin D status in primary hyperparathyroidism. *Clin Endocrinol (oxf)* 1995; 43 : 351-8.
13. Goswami R, Gupta N, Goswami D, Marwaha RK, Tandon N, Kochupillai N. Prevalence and significance of low 25-hydroxyvitamin D concentrations in healthy subjects in Delhi. *Am J Clin Nutr* 2000; 72 : 472-5.
14. Harinarayan CV, Ramalakshmi T, Prasad UV, Sudhakar D, Srinivasarao PVLN, Sarma KVS, et al. High prevalence of low dietary calcium, high phytate consumption and vitamin D deficiency in healthy south Indians. *Am J Clin Nutr* 2007; 85 : 1062-7.
15. Teotia SPS, Teotia M. Singh KP. Epidemiology of metabolic bone disease and clinically related disorders-India, 1963-2001. In: Thakur BB, Postgraduate medicine. Mumbai: The Association of Physicians of India; 2002. p. 501-14.
16. Teotia SPS, Teotia M, Jyoti Krishna. Vitamin D. In: Teotia SPS, Teotia M, editors. *Nutritional and Metabolic Bone and Stone Disease: Asian Perspective*, First Edition, New Delhi: CBS Publishers, 2008. p. 80-91.
17. Hollick MF, Garabedian M. Vitamin D. Photobiology, metabolic mechanism of action, and clinical applications. In: Favus MS ed. *Primer on the Metabolic bone diseases and disorders of mineral metabolism*, sixth ed., Washington, D.C, American Society for Bone and Mineral Research, 2006. p. 106-114
18. Chalmers, J.; Conacher, W. D. H. ; Gardner, D. L.; and SCorr, P. J.: Osteomalacia - A Common Disease in Elderly Women. *J. Bone and Joint Surg.* , 49-B: 403-423, Aug. 1967.
19. Hodkjonson, H. M. : Fracture of the Femur as a Presentation of Osteomalacia. *Geront. Clin*, 13: 189-191, 1971.
20. Reginato AJ, Coquia JA. Musculoskeletal manifestations of osteomalacia and rickets. *Best Pract Res Clin Rheumatol* 2003;17:1063-80.
21. Need AG. Bone resorption markers in vitamin D insufficiency. *Clin Chim Acta* 2006;368:48-52
22. Jaffe, H. L.: *Metabolic, Degenerative, and Inflammatory Diseases of Bones and Joints*, p. 381. Philadelphia, Lea and Febiger, 1972.
23. Reynolds, W. A., and Karo, J. J.: *Radiologic Diagnosis of Metabolic Bone Disease*, Orthop. Clin. North America, 3: 521-543, 1972.
24. Steinback, H. G. , and Noetzi, Max: Roentgen Appearance of the Skeleton in Osteomalacia and Rickets. *Am. J. Roentgenol.* . 91: 955-972, 1964.
25. Steinbach, H. L.; Kolb, F. O.; And Gilfillan, Rutherford: Mechanism of Production of Pseudofractures in Osteomalacia (Milkman's Syndrome). *Radiology*, 62: 388-394, 1954.
26. Faccini JM, Teotia SPS. Histopathological assessment of endemic skeletal fluorosis and osteomalacia. *Calcif Tissue Res* 1974; 16 : 45-57.
27. Reginato AJ, Falasca GF, Pappu R, McKnight B, Agha A. Musculoskeletal manifestations of osteomalacia: report of 26 cases and literature review. *Semin Arthritis Rheum* 1999;28:287-304.
28. S P S Teotia, M Teotia. Nutritional bone disease in Indian population. *Ind J of Med Res.* 2008; 127(3):219-229.
29. Rajakumar K. Vitamin D, cod-liver oil, sunlight, and rickets: a historical perspective. *Pediatrics* 2003;112:132-5
30. Norman AW, Henry HL. Vitamin D. In: Zempleni J, Rucker RB, McCormick DB, Suttie JW, eds. *Handbook of Vitamins*, Boca Raton, FL:CRC Press, 2007
31. N. Kochupillai. The physiology of vitamin D : Current concepts. *Indian J Med Res* 127, March 2008, 256-262.
32. Vitamin D and cancer. Proceedings of the vitamin D workshop meeting. November 17-19, 2004. National Institutes of Health, Bethesda, Maryland, USA. *J Steroid Biochem Mol Biol* 2005;97:1-218

33. Bouillon R, Carmeliet G, Verlinden L, van Etten E, Verstuyf A, Luderer HF, Lieben L, Mathieu C, Demay M. Vitamin D and human health: lessons from vitamin D receptor null mice. *Endocr Rev* 2008;29:726–76
34. Bouillon R. Vitamin D as potential baseline therapy for blood pressure control. *Am J Hypertens* 2009;22:867–70
35. Perez-Lopez FR. Sunlight, the vitamin D endocrine system, and their relationships with gynaecologic cancer. *Maturitas* 2008;59:101–13
36. Wang TJ, Pencina MJ, Booth SL, Jacques PF, Ingelsson E, Lanier K, Benjamin EJ, D'Agostino RB, Wolf M, Vasan RS. Vitamin D deficiency and risk of cardiovascular disease. *Circulation* 2008;117:503–11
37. Nemerovski CW, Dorsch MP, Simpson RU, Bone HG, Aaronson KD, Bleske BE. Vitamin D and cardiovascular disease. *Pharmacotherapy* 2009;29:691–708
38. Harris SS, Dawson-Hughes B. Reduced sun exposure does not explain the inverse association of 25-hydroxyvitamin D with percent body fat in older adults. *J Clin Endocrinol Metab* 2007;92:3155–7
39. Narvaez CJ, Matthews D, Broun E, Chan M, Welsh J. Lean phenotype and resistance to diet-induced obesity in vitamin D receptor knockout mice correlates with induction of uncoupling protein-1 in white adipose tissue. *Endocrinology* 2009;150:651–61
40. Pittas AG, Lau J, Hu FB, Dawson-Hughes B. The role of vitamin D and calcium in type 2 diabetes. A systematic review and meta-analysis. *J Clin Endocrinol Metab* 2007;92:2017–29
41. Bischoff-Ferrari HA, Willett WC, Wong JB, Stuck AE, Staehelin HB, Orav EJ, Thoma A, Kiel DP, Henschkowski J. Prevention of nonvertebral fractures with oral vitamin D and dose dependency: a meta-analysis of randomized controlled trials. *Arch Intern Med* 2009;169:551–61
42. Melamed ML, Michos ED, PostW, Astor B. 25-hydroxyvitamin D levels and the risk of mortality in the general population. *Arch Intern Med* 2008;168:1629–37
43. Kovesdy CP, Ahmadzadeh S, Anderson JE, Kalantar-Zadeh K. Association of activated vitamin D treatment and mortality in chronic kidney disease. *Arch Intern Med* 2008;168:397–403
44. Wolf M, Betancourt J, Chang Y, Shah A, Teng M, Tamez H, Gutierrez O, Camargo CA Jr, Melamed M, Norris K, Stampfer MJ, Powe NR, Thadhani R. Impact of activated vitamin D and race on survival among hemodialysis patients. *J Am Soc Nephrol* 2008;19:1379–88

How to cite this article: Akhtar MN, Agarwal S. Severe osteomalacia and malnutrition: many a slip between the cup and the lip - a case report based discussion. *Int J Health Sci Res.* 2015; 5(7):536-542.
