

*Case Report***Bilateral Choroidal Melanoma and Recurrence of the Choroidal Melanoma Following Internal Resection of the Left Eye**Arjeta Grezda<sup>1</sup>, Ermal Simaku<sup>1</sup>, Monika Fida<sup>2</sup>, Brikena Bezati<sup>3</sup>, Suela Kellici<sup>4</sup><sup>1</sup>Department of Ophthalmology, University of Medicine, Tirana, Albania<sup>2</sup>Department of Dermatology, University of Medicine, Tirana, Albania<sup>3</sup>Dermato- Venerology Private Practice, Tirana, Albania<sup>4</sup>University of Medicine, Tirana, Albania

Corresponding Author: Brikena Bezati

*Received: 22/04/2015**Revised: 22/05/2015**Accepted: 29/05/2015***ABSTRACT**

Our aim is to present the first diagnosed case of bilateral malignant melanoma of the choroid in Albania. A 49 year-old woman presented on April 2012 with blurred vision on the left eye, the same eye which about 9 months ago, underwent internal resection of an intraocular choroidal melanoma. She was diagnosed with recurrent malignant melanoma. Left eye was enucleated and biopsy confirmed the diagnosis. On September 2012 she complained of blurred vision in the other eye. It was diagnosed of choroidal melanoma of the right eye.

**Key words:** choroidal melanoma; bilateral; enucleation.

**INTRODUCTION**

Choroidal melanoma is the most frequent primary malignant tumor of the eye. It arises from melanocytes of the choroid. It can be diagnosed incidentally during routine eye check-up, or at the time when the symptoms start to appear. Therefore, it may remain asymptomatic for a long time. It has been observed that the symptoms appear later in tumors with more anterior origin. Liver is the most common site for choroidal melanoma to metastasize. Rare cases of bilateral choroidal melanoma have been reported in the literature. Treatment modalities of choroidal melanoma vary according to many factors as size of the tumor, age of the patient, condition of the other eye and etc.

Ophthalmic plaque radiation therapy and enucleation are the most commonly used therapies. Globe sparing treatment modalities have become more popular these days, so enucleation is usually recommended to be applied for large sized choroidal melanomas. Internal resection has been described as one of the treatment modalities for choroidal melanoma.

**CASE REPORT**

A 49 years old woman was referred for ophthalmologist opinion on June 2011. She had blurred vision in the left eye from 2 months. Examination showed Best Corrected Visual Acuity (BCVA) of 1.0 in the RE and 0.6 in the LE (Snellen Visual Acuity). Anterior segment was

unremarkable in both eyes. Dilated fundus examination showed normal features in the right eye, and a solid choroidal pigmented mass in the left eye, located supero-nasally to the optic disc, measuring 10 x 5 x 10 mm in size. The disc appeared normal with a C/D ratio 0.2. Fundus photo of the left eye was taken for documentation (Figure 1). Retinal angiography findings were consistent with choroidal melanoma. Ultrasound examination of the eye (Figure 2) supported this diagnosis. Head CT and MRI, and ultrasound examination (Fig. 3) confirmed the diagnosis.

All the other systemic examination appeared normal, including CT and MRI of abdomen and head, abdominal ultrasound, liver function and chest x-ray.

The only treatment option in Albania would be enucleation of the eye, so the patient was referred to as specialized clinic outside of Albania. Internal resection of the choroidal melanoma was performed there. We are not aware of the rationale behind this decision and of the specific steps of surgery in this case. Patient returned to our clinic in October 2011. Examination showed BCVA of 1.0 in the right eye and 0.05 in the left eye.

Right eye slit lamp examination didn't reveal any abnormality. Dilated fundus examination was unremarkable in this eye. Figure 4 shows the fundus appearance of the left eye at this time. We advised the patient to come for her check up every 3 months or earlier if she would notice any problem. On December 2011, BCVA of the left eye had improved to 0.1. Stability of other features was observed. On December the patient came for the routine check up and it was noted a slight improvement of the BCVA of the left eye by 10%. (Fig. 5)

Patient came back on April 2012 complaining of worsening of vision of her left eye. BCVA was 1.0 in the right eye and

light perception in the left eye. Left eye dilated fundus examination suggested recurrence of choroidal melanoma, while the right eye didn't show any abnormality on slit lamp examination. Periphery, macular and perimacular zone of the right fundus were unremarkable. General check-up showed no signs of involvement of extraocular tissues. Left eye enucleation was performed. Biopsy confirmed the presence of a spindle-B cell choroidal melanoma.

The patient came back after 5 months complaining of blurred vision in the right eye. The examination showed BCVA of 0.7, presence of a solid orange pigmented choroidal mass close to the macula (Figure 6 and Figure 7), approximately 7.0 x 5.0 x 8.0 mm in size.

MRI of the head confirmed the diagnosis too. Systemic examination showed presence of multiple liver metastases. No evidence of primary skin melanoma was found. The patient's family refused treatment of the right eye, so histologic examination was not performed for this eye. Patient was followed up at the oncology clinic, undergoing palliative treatment. She passed away 20 months after the time of diagnosis.

Figures

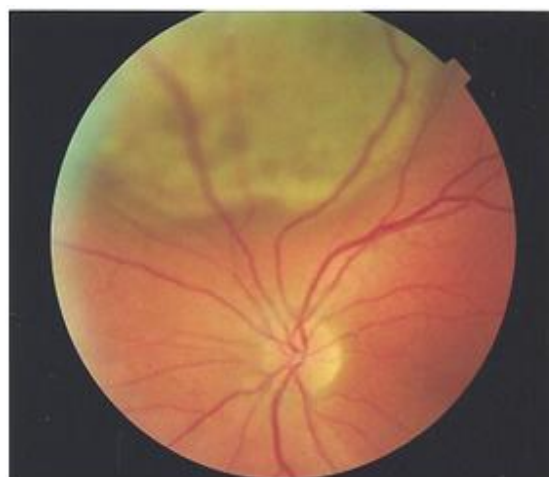

Figure 1. Photography of the left eye

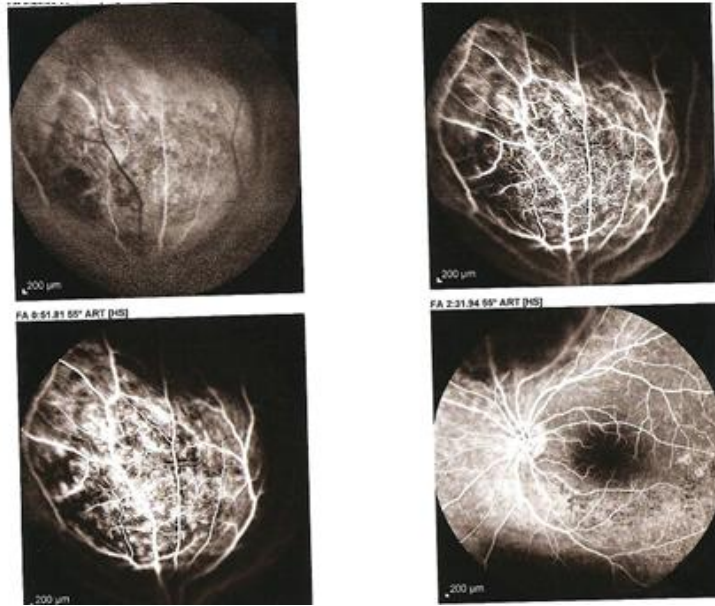


Figure 2. Floresce in angiography of the left eye.

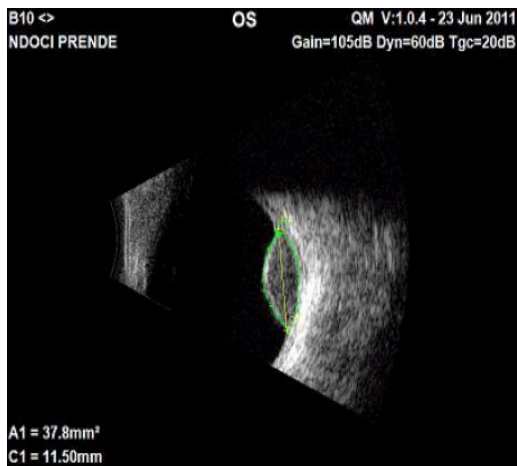


Figure 3. Ultrasound of the left eye

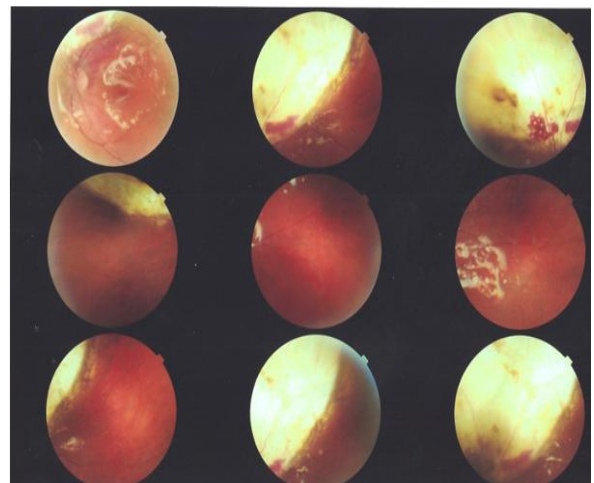


Figure 4. Left fundus on October 2011.

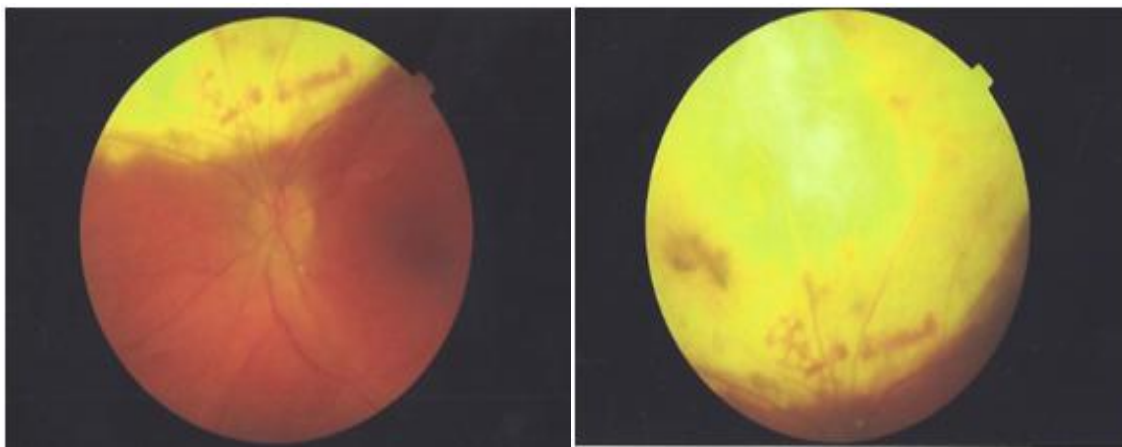


Figure 5. Left Fundus on December 2011

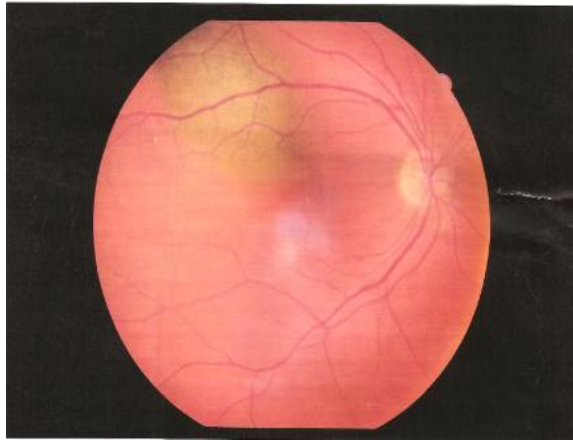


Fig 6. Choroidal melanoma on the right fundus.

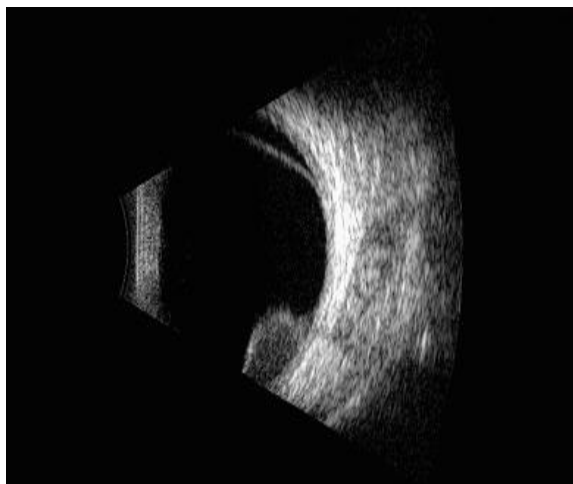


Figure 7. B-scan of the right eye

## DISCUSSION

The fellow eye apparently has a metastatic lesion rather than a second primary tumor. Metastasis from one eye to the other has also been reported. [1] However, we can't exclude the possibility of bilateral choroidal melanoma as represents an alternative for the diagnosis in this patient. Bilateral cases are reported to be very rare. A bilateral case is expected to occur once every 18 years in the United States. Metastasis from one eye to the other has also been reported. [2] Singh AD et al estimated that the probability of any one individual developing uveal melanoma during his lifetime is  $7.36 \times 10^{-5}$ . [3] Based on this figure, Hadden PW et al.

calculated the lifetime probability of bilateral uveal melanoma to be  $1.3510^{-9}$ . [4] Exact histologic diagnosis was not possible for our patient because her family members did not agree to perform the autopsy. Therefore, we could not define if the patient suffered from left eye choroidal melanoma with metastatic lesions in the right eye and liver, or bilateral choroidal melanoma with metastasis in the liver. Enucleation has been the preferred treatment for choroidal melanoma in the past and it is still the preferred treatment for large tumors (basal diameter  $>15$  mm and height  $>10$  mm). [5] The pivotal Collaborative Ocular Melanoma Study (COMS), found that at 12 years, there was no significant difference in survival rate between enucleation and plaque brachytherapy. [6] This is the preferred treatment method for medium sized tumors ( $< 10$  mm in height and  $< 15$  mm in diameter) as in our case. However, plaque brachytherapy bears the risk of radiation-related complications, such as radiation retinopathy and optic neuropathy.

Other studies have investigated the use of endoresection as an alternative treatment method to plaque brachytherapy. In a nested case-control study, endoresection for posterior choroidal melanomas provided outcomes similar to or better than those obtained with iodine-125 plaque brachytherapy. [7] The main risk of this procedure is the potential for liberating active tumor into the globe during the surgical procedure. Metastatic spread was observed in 11 patients in the iodine-125 brachytherapy group vs only 1 patient in the endoresection group (20.4% and 3.7%, respectively,  $P = .053$ ).

## CONCLUSIONS

We think that plaque brachytherapy or enucleation at the time of first diagnosis could have been a lifesaving method in our case. This case report highlights the need for

further studies, in larger group of patients, to confirm the results of endoresection for treatment of choroidal melanoma. It highlights the risk behind choosing a less aggressive technique for the treatment of such an aggressive disease and also the importance of thorough examination of both eyes, in every case presenting with unilateral choroidal melanoma. Close follow-up and monitoring of these cases is crucial for early detection of recurrences and metastasis of this tumor.

#### REFERENCES

1. Singh AD, Shields JA, Shields CL, Sato T. Choroidal melanoma metastatic to the contralateral choroid. *Am J Ophthalmol* 2001;132: 941–943
2. Shamma HF, Watzke RC. Bilateral choroidal melanomas. Case report and incidence. *Arch Ophthalmol*. 1977 Apr;95(4):617-23.
3. Singh AD, Shields JA, Shields CL, Sato T. Choroidal melanoma metastatic to the contralateral choroid. *Am J Ophthalmol* 2001;132: 941–943
4. Singh AD, Wang MX, Donoso LA, Shields CL, De Potter P, Shields JA et al. Familial uveal melanoma—III: is the occurrence of familial uveal melanoma coincidental? *Arch Ophthalmol* 1996; 114: 1101–1104.
5. Hadden PW, Damato BE, McKay IC. Bilateral uveal melanoma (a series of four cases). *Eye*. 2003;17:613–616
6. Enrique Garcia-Valenzuela, Mauricio E Pons, James E Puklin, Cathleen A Davidson Choroidal Melanoma. [internet] 2014 [updated march 31, 2014, cited april 22, 2015]. Available from [www.medscape.com](http://www.medscape.com)
7. The COMS randomized trial of iodine 125 brachytherapy for choroidal melanoma: V. Twelve-year mortality rates and prognostic factors: COMS report No. 28. *Arch Ophthalmol*. 2006; 124:1684-1693.
8. Caminal JM, Mejia K, Masuet-Aumadell C, Arias L, Piulats JM, Gutierrez C, et al. Endoresection Versus Iodine-125 Plaque Brachytherapy for the Treatment of Choroidal Melanoma. *Am J Ophthalmol*. 2013 Aug; 156(2): 334-342

How to cite this article: Grezda A, Simaku E, Fida M et. al. Thyrotoxicosis during infection: etiologies and outcome. *Int J Health Sci Res*. 2015; 5(7):465-469.

\*\*\*\*\*