

*Case Report*

## Step Wise Management of Severe Refractory Asthma: A Case Report

Manisha Bhardwaj<sup>1</sup>, Deepak Aggarwal<sup>2</sup>, A.K Janmeja<sup>3</sup>, Varinder Saini<sup>4</sup><sup>1</sup>Junior Resident Final Year, <sup>2</sup>Assistant Professor, <sup>3</sup>Professor and Head, <sup>4</sup>Professor,  
Department of Pulmonary Medicine, Government Medical College and Hospital, Chandigarh, India.

Corresponding Author: Varinder Saini

*Received: 29/05/2015**Revised: 21/06/2015**Accepted: 24/06/2015*

### ABSTRACT

Asthma is not a single disease but a conglomerate of different phenotypes, based on severity. Severe refractory asthma constitutes the most difficult phenotype to manage. Protocol based step-wise management ensures comprehensive and best possible management of this near fatal disease. This case highlights the importance of schematic approach in the management of severe refractory asthma.

**Keywords:** refractory asthma, phenotype, comorbidities.

### INTRODUCTION

Refractory asthma affects approximately 15 to 20% of asthmatic patients. However, the costs related to their disease represent approximately half of the total asthma-related costs. It encompasses asthma subgroups previously described as “severe asthma”, “steroid dependent and/or resistant asthma”, “difficult to control asthma”, “poorly controlled asthma”, “brittle asthma” or “irreversible asthma”.<sup>[1,2]</sup> Step wise approach is the cornerstone for successful treatment. We present a case of refractory asthma highlighting the complexities in its management.

### CASE REPORT

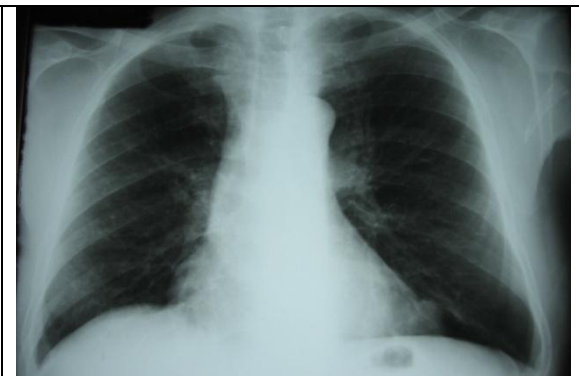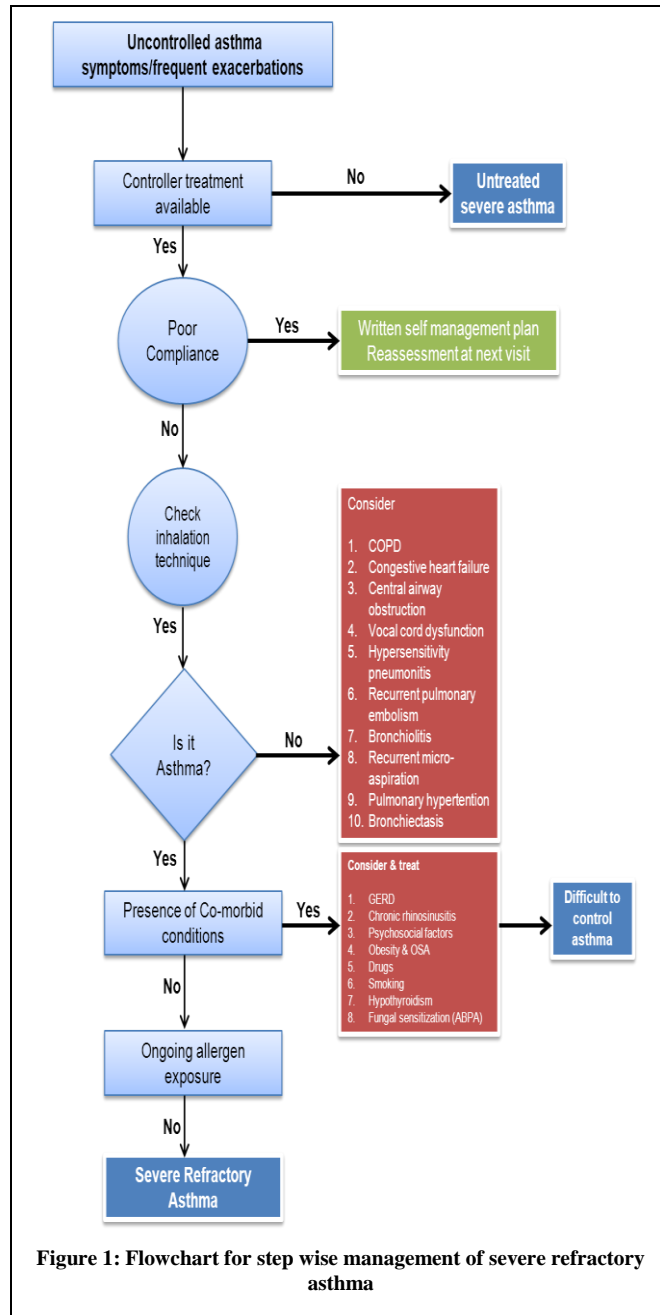
A 61 year old non smoker male, shopkeeper by occupation, presented to our clinic with increased shortness of breath and fever since 5 days. Patient had asthma for 5 years and diabetes for 3 years. He had no

pets and no significant family history of atopy. He was started on combination of inhaled bronchodilators and corticosteroids, leukotriene modifier agents, theophylline and insulin by private practitioner. Patient had been suffering recurrent exacerbations for last 5 years. Initially he used to get relieved with short course of parenteral steroids. But with time his hospitalizations and duration of parenteral steroids increased.

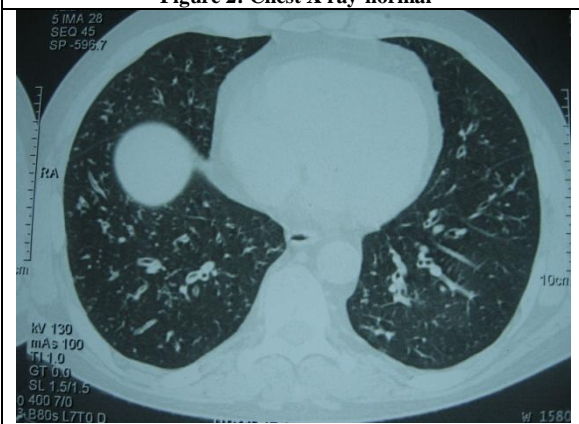
On admission, he was tachypneic with bilateral polyphonic biphasic wheeze. Routine blood investigations were normal except for Urea/creatinine-85/1.9. ABG showed type I respiratory failure. The diagnosis of asthma was re-evaluated and reconfirmed, compliance ensured and inhaler technique checked. To exclude other etiologies that mimic asthma, serology for auto-immune diseases (rheumatoid arthritis factor, C-reactive protein, antinuclear antibody), vasculitis (anti nuclear

cytoplasmic antibody profile) and serum thyroid stimulating hormone levels were

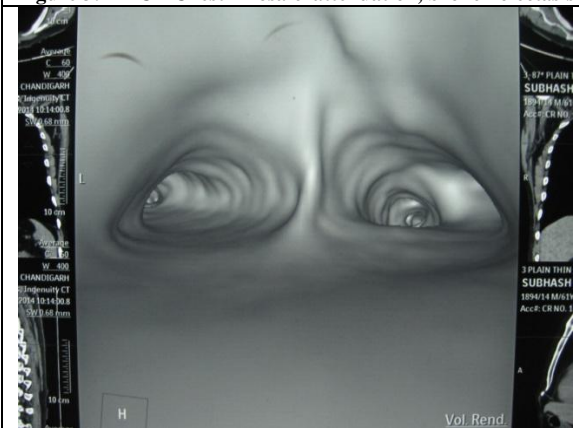
tested but they were normal.



**Figure 2: Chest X ray-normal**



**Figure 3: HRCT Chest- Mosaic attenuation, bronchiolectasis**



**Figure 4: VIRTUAL ENDOSCOPY- normal**

D-dimer levels were within normal limits and two dimensional echocardiography (2D-ECHO) revealed no cardiac abnormality/dysfunction. Sputum for acid fast bacilli and fungal cultures were sterile and malignant cytology was negative.

Ear, nose and throat screening ruled out nasal polyps, vocal cord dysfunction and sinusitis. Gastroesophageal reflux disease prophylaxis was given. High resolution computed tomography (HRCT) of chest showed mosaic attenuation pattern along

with mild bilateral bronchiectasis. To rule out allergic bronchopulmonary aspergillosis (ABPA), total serum IgE and Aspergillus specific IgE were sent. Total serum IgE was raised (>1000 IU/L). However, specific IgE was within normal limits. So patient was thought to have Aspergillus hypersensitivity. Considering the results being affected by oral steroids, treatment was planned on the lines of ABPA. Tab Itraconazole 400 mg/day were started along with oral steroids (0.5mg/kg/day of prednisolone). However, symptomatic improvement was short lasting. Patient was planned to be started on Omalizumab but he refused. Repeat 2-D ECHO showed global hypokinesia but coronaries were normal on angiography. As he refused Fibre-optic bronchoscopy, Virtual endoscopy was done which ruled out endobronchial obstruction or pathology. He was managed with intravenous methylprednisolone (1mg/kg/day), MgSO<sub>4</sub>, antibiotics and bronchodilators and non invasive positive pressure ventilation. He recovered and was discharged in hemodynamically stable condition. Patient was diagnosed as a case of late onset severe refractory asthma.

## DISCUSSION

Severe asthma has been known by different terminologies with no clear definition. As per recent WHO publication, severe asthma has been defined by the level of current clinical control and risks as: Uncontrolled asthma which can result in risk of frequent severe exacerbations (or death) and /or adverse reactions to medications and/or chronic morbidity (including impaired lung function or reduced lung growth in children). It includes three different sub groups of severe asthma each carrying different public health messages and challenges- untreated severe asthma, difficult-to-treat severe asthma and treatment-resistant severe asthma<sup>[3]</sup>

These definitions have important implication in public health planning, increased morbidity and financial costs, and facilitate comparisons. After step wise management excluding all diagnostic mimics of asthma and managing all co-morbidities, our patient was labelled as severe refractory asthma. Last, not the least, new evidence is being generated regarding categorization of asthma into different phenotypes based on their clinical characteristics. Our patient fits into ‘adult onset, male predominant’ phenotype. New experimental phenotype-targeted molecular based therapies aim at improved outcomes and fewer side-effects.<sup>[4]</sup>

## REFERENCES

1. Rabe KF, Adachi M, Lai CK, Soriano JB, Vermeire PA, Weiss KB, et al. Worldwide severity and control of asthma in children and adults: the global asthma insights and reality surveys. *J Allergy Clin Immunol.* 2004;114 (1):40–7.
2. Proceedings of the ATS workshop on refractory asthma: current understanding, recommendations, and unanswered questions. American Thoracic Society. *Am J Respir Crit Care Med.* 2000;162(6):2341-51.
3. Bousquet J, Mantzouranis E, Cruz AA, Ait-Khaled N, Baena-Cagnani CE, Bleecker ER, et al. Uniform definition of asthma severity, control, and exacerbations: document presented for the World Health Organization Consultation on Severe Asthma. *J Allergy Clin Immunol.* 2010;126(5):926-38.
4. Chung KF, Wenzel SE, Brozek JL, Brozek JL, Bush A, Castro M, Sterk PJ, et al. International ERS/ATS guidelines on

definition, evaluation and treatment  
of severe asthma. Eur Respir J.

2014;43(2):343-73.

How to cite this article: Bhardwaj M, Aggarwal D, Janmeja AK et. al. Step wise management of severe refractory asthma: a case report. Int J Health Sci Res. 2015; 5(7):461-464.

\*\*\*\*\*

**International Journal of Health Sciences & Research (IJHSR)**

**Publish your work in this journal**

The International Journal of Health Sciences & Research is a multidisciplinary indexed open access double-blind peer-reviewed international journal that publishes original research articles from all areas of health sciences and allied branches. This monthly journal is characterised by rapid publication of reviews, original research and case reports across all the fields of health sciences. The details of journal are available on its official website ([www.ijhsr.org](http://www.ijhsr.org)).

Submit your manuscript by email: [editor.ijhsr@gmail.com](mailto:editor.ijhsr@gmail.com) OR [editor.ijhsr@yahoo.com](mailto:editor.ijhsr@yahoo.com)