

*Short Communication*

Median Nerve F Wave Study in Traumatic Brachial Plexus Injury

Ashish Arvind^{1*}, Sushma Sood^{2*}, Roop Singh^{3**}¹Post Graduate Student (Final Year), ²Senior Professor & Head of the Department, ³Senior Professor,

*Department of Physiology, **Department of Orthopedics,

Pt. B D Sharma PGIMS, Rohtak-124001, Haryana, India.

Corresponding Author: Ashish Arvind

Received: 08/06/2015

Revised: 24/06/2015

Accepted: 25/06/2015

ABSTRACT

Adult traumatic brachial plexus injuries are not uncommon and affect the quality of life severely. This study included 30 patients with traumatic brachial plexus injury of more than 3 months duration of either sex. F wave was recorded for median nerve in Abductor pollicis brevis muscle and evaluated on both the affected and unaffected limbs. The test was done in a single sitting. M latency, minimum (F_{\min}), maximum (F_{\max}), mean (F_{mean}) and F- M latencies were examined. The latency was significantly increased in all patients with brachial plexus injury. All the patients were having complaint of inability to lift the affected limb.

Key words: Brachial plexus, F wave, median nerve.

INTRODUCTION

Injuries to the brachial plexus are common and are the most severe of all lesions of peripheral nerves. Adult traumatic brachial plexus injury is a potentially severe debilitating injury, commonly affecting individuals in the prime of their life. ^[1] Complete loss of the use of one's limb or partial loss (e.g. the limb is not capable in positioning of a working hand in space) results in significant impairment with devastating consequences. ^[2] Motorcycle misadventures, warfare injuries, contact sports and birth trauma are some of the leading causes of traumatic brachial plexus injury. Viral infections, tumours, surgical misadventures, radiation fibrosis are some of

the non traumatic factors associated with brachial plexopathy.

The F wave is a response of motor neurons activated by stimulation of a peripheral nerve. It is a late response resulting from antidromic activation of motor neurons involving conduction to and from the spinal cord and occurs at the interface between peripheral and central nervous systems. The name F wave is attributed to their recognition for the first time in the small muscles of foot. F waves are most prominent and easily elicited at supramaximal stimulation. ^[3]

MATERIALS AND METHODS

We selected 30 patients with history of trauma with clinical and radiological

diagnosis of brachial plexus injury for at least 3 months of either sex irrespective of age. The procedure was explained in detail in their own language and informed consent was taken in a fixed performa. They were encouraged to ask questions regarding procedure. subjects were screened out for the presence of any other metabolic or endocrine factors causing plexopathy. The ethical clearance was taken from the institute ethical committee. The affected side was taken as Group I and the healthy side was taken as Group II.

The detailed history was taken from each for the pattern of injuries, the mode of injury, associated lesions and the course of treatment. F wave study was conducted on RMS EMG EP Mark II machine manufactured by Recorders and Medicare Systems, Chandigarh, India in an air conditioned room with the temperature 23 °C to 34 °C inside the Faraday's cage.

Patients were asked to lie down comfortably and his arm supported at an arm rest in supine position at an angle of 45° relative to the trunk. Patients were instructed to close eyes and keep the arm in fully relaxed position. The electrode application site was cleaned with spirit swab and allowed to dry. The surface recording electrodes were placed over muscle belly and reference electrode was placed over the tendon of the muscle i.e. in a belly tendon montage similar to motor nerve conduction study. Ground electrode was placed over the dorsum of the hand.

F wave was recorded for median nerve in Abductor pollicis brevis muscle. Conventional supramaximal stimulation (25% above maximal) at a rate of not more than 0.5 Hz was used. Cathode was proximal to anode to avoid anodal block. Stimulation was done at the wrist between

the Palmaris longus and Flexor carpi radialis tendon i.e. 1 cm proximal to distal crease.

For analysis 10 F waves were recorded. The same procedure was done on the non affected limb as control. The parameters studied were latency of M and F wave. Ten consecutive F waves were recorded. For each extremity, we calculated M latency, minimum (F_{min}), maximum (F_{max}), and mean (F_{mean}) and F-wave latencies. The data so gathered was entered in the proforma.

Statistical analysis: Unpaired t- test was applied to the test result data.

RESULTS

The F wave was obtained on both the normal and affected side and their latencies were observed. In all the parameters, latency was increased on affected side.

The M latency was increased on affected side but it was statistically not significant. F_{max} latency also showed non-significant increase on affected side. The F_{min} latency, F_{mean} latency and F-M latency all showed significant increase on the affected side. This study included 27 males and 3 females. The F wave parameters were affected irrespective of sex.

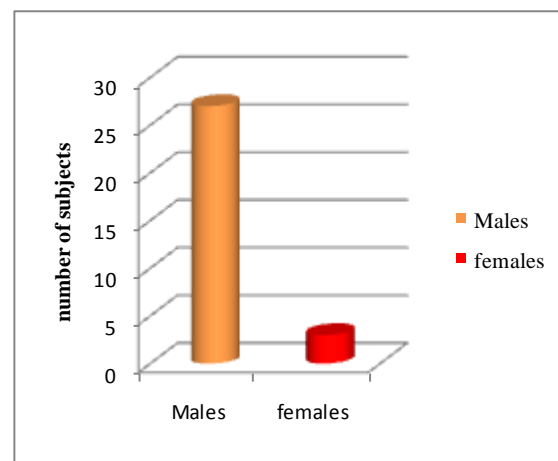


Figure 1 Gender distribution of lesion

Table 1 Different latency parameters of F wave for median nerve in Group I and Group II

Parameters	M latency		F-M latency		F _{min} latency		F _{max} latency		F _{mean} latency	
Nerve	Median									
N	30									
Group	I	II	I	II	I	II	I	II	I	II
Mean (ms)	3.59	3.52	37.62	25.33	31.47	27.11	41.33	38.63	36.73	32.87
SD	1.69	0.8	23.3	10.88	11.28	1.14	10.91	2.55	11.1	1.52
P value	0.82		0.04		0.03		0.19		0.06	

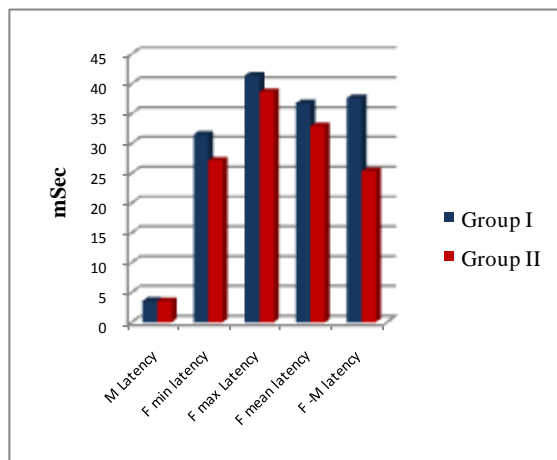


Figure 2 Comparison of different F wave latency parameters of median nerve in Group I and Group II

DISCUSSION

Brachial plexus injury causes disruption of nerve fibers. F wave abnormality specifically indicates motor fiber disruption as F wave is the response recorded in motor neurons. The normal values for F wave latency have been given by many studies.

Dumitru and Zwarts mentioned in their book the values of M latency as 3.5 ± 0.5 ms for median nerve. [4]

Garg et al in their study in normal population of Malwa region established the F_{min} latency in median nerve as 26.29 ± 2.13 ms in males and 25.98 ± 2.41 ms in females respectively. [5] Cornwall and Nelson in their study established the F_{min} latency in median nerve to be 24.5 ± 2.2 ms. [6] Eisen and Fisher suggested that for evaluating unilateral symptoms or signs, side to side comparison of F-wave latency is useful. They established the upper limits of asymmetry as 2.3 ms in median nerve. [7] Parmar and

Singh established in their study the upper limit of F_{min} latency to be 25.03 ± 2.31 ms in median nerve. [8]

Taksande and Jain in their study concluded that the minimal latency was most reliable and useful measurement. [9] Nelson et al established the upper limit of minimal F latency as 31 ms in female and 34.4 ms in normal males. They considered right to left asymmetry of minimal F latency exceeding 2 ms in hand and 4 ms in foot as abnormal. [10]

Eisen A and Hoirsch M suggested that F wave was useful in differentiating between distal and proximal entrapments. [11]

Since F wave is produced by antidromic conduction of impulse in a motor neuron, an increase in latency and decrease in amplitude is suggestive of lesion at the interface of peripheral and central part of a motor nerve. A decrease may be observed in M latency which is due to reduced inhibitory influences on peripheral part of the nerve.

The results in this study were quite in line with the previously established values. Though the sample is just 30 patients, further studies are required.

CONCLUSION

The median nerve F_{min} and F-M latencies are better parameters of measuring the severity of lesion and it is increased in brachial plexus injury. F wave studies combined with other electrodiagnostic studies can serve as an accurate non invasive investigation method for the evaluation of brachial plexus lesions and their prognosis.

REFERENCES

1. Rankine JJ. Adult traumatic brachial plexus injury. *Clinical radiology*. 2004;59:767-74
2. Iannotti JP, Williams GR, Jr. Injuries of the brachial plexus In:Kozin SH editor. *Disorders of the shoulder, diagnosis & management*. 2nd ed. Philadelphia: Lippincott Williams &Wilkins, 2007. p.1087-134.
3. Misra UK, Kalita J. *Clinical Neurophysiology*. 2nd ed. New Delhi: Elsevier; 2011.p.102-11.
4. Dumitru D, Zwarts MJ, Amato AA. *Special nerve conduction techniques*. In. *Electrodiagnostic Medicine*, 2nd Edition
5. Garg R, Bansal N, Kaur H, Arora KS. Nerve conduction studies in the upper limb in the malwa region-normative data. *J Clin Diagn Res*. 2013 Feb;7(2):201-4. doi: 10.7860/JCDR/2013/4804.2727. Epub 2013 Feb 1.
6. Cornwall MW, Nelson C. Median nerve F-wave conduction in healthy subjects. *Phys Ther*. 1984 Nov; 64(11):1679-83.
7. Eisen A, Fisher M. The F wave. In. Deuschl G, Eisen A editors. *Recommendations for the practice of clinical neurophysiology: Guidelines of the international Federation of Clinical Physiology*. Elsevier Science.BV.p.255-7.
8. Parmar LD, Singh A. The study of F-waves in normal healthy individuals. *The internet journal of neurology*. 2013; 16(1).
9. B Taksande, A Jain. "F" WAVE: Clinical Importance. *The Internet Journal of Neurology*. 2008; 10(2).
10. Cornwall MW, Nelson C. Median nerve F-wave conduction in healthy subjects. *Phys Ther*. 1984 Nov; 64(11): 1679-83.
11. Eisen A, Hoirsch M. The electrodiagnostic evaluation of spinal root lesions. *Spine (Phila Pa 1976)*. 1983 Jan-Feb; 8(1):98-106.

How to cite this article: Arvind A, Sood S, Singh R. Median nerve F wave study in traumatic brachial plexus injury. *Int J Health Sci Res*. 2015; 5(7):372-375.
