

*Case Report*

## **Idiopathic Unilateral Masseteric Hypertrophy - Report Of Two Cases And An Update**

Abdulla Mufeed<sup>1\*</sup>, Moideenkutty Gurukkal<sup>2</sup>, Shanoj RP<sup>3\*\*</sup>, Reshma V.J.<sup>4\*\*\*</sup><sup>1</sup>Reader, <sup>3</sup>Assistant Professor, <sup>4</sup>Sr. Lecturer<sup>\*</sup>Department of Oral Medicine & Maxillofacial Radiology, <sup>\*\*</sup>Department of Prosthodontics,<sup>\*\*\*</sup>Department of Oral Medicine & Radiology  
MES Dental College, Perinthalmanna, Kerala<sup>2</sup>Assistant Professor, Department of General Medicine, MES Medical College & Hospital, Kerala

Corresponding Author: Abdulla Mufeed

*Received: 08/05/2015**Revised: 26/05/2015**Accepted: 26/05/2015*

### **ABSTRACT**

Masseteric hypertrophy is one of the rare conditions presenting with facial swelling or asymmetry. It is not unusual for a clinician to misdiagnose this condition. Patients are usually concerned only about the facial esthetics as it remains asymptomatic. There is no uniform agreement on whether surgical correction is indicated or not. The authors describe two cases of unilateral masseteric hypertrophy with their imaging findings.

**Key words:** Masseteric hypertrophy, Facial asymmetry, Idiopathic hypertrophy.

### **INTRODUCTION**

Idiopathic hypertrophy of the masseter muscle is a rare disorder of unknown cause characterized by unilateral or bilateral enlargement of the masseter muscles. Idiopathic masseter muscle hypertrophy must be accurately diagnosed, as it may be mistaken for other diseases like parotid tumors, space infections bony pathologies and vascular lesions. A detailed history, through intra oral and extra oral examination and imaging modalities helps the diagnosis. It is a benign condition that usually does not require surgical intervention. Misdiagnosed cases due to lack of familiarity with this entity may lead to unnecessary biopsies and explorative surgeries.

### **CASE REPORTS**

#### **CASE 1**

A 13-year-old girl reported to the out-patient department with the chief complaint of swelling near the right angle of mandible since 15 months. She reported that the swelling was small initially and gradually increased to the present size. It was associated with occasional mild pain. There were no other symptoms and had no history of trauma, paraesthesia, trismus or dysphagia.

On examination, she presented a soft and non-tender swelling at the right angle of mandible measuring approximately 6 x 5 cm. (fig.1, fig.2) The overlying skin was normal in color and temperature was not raised. On clenching the masseter muscle was felt with definite borders. The ipsilateral

ear lobe was not raised and no regional lymphadenopathy was detected. There was no significant findings intra orally. Bimanual palpation during the muscle contraction revealed a definite increase in the bulk of masseter muscle. Clinical examination did not reveal any abnormality of lips, tongue, floor of mouth, soft palate, throat, alveolar mucosa, gingiva, temporomandibular joint or occlusion. In view of the history and clinical examination, a provisional diagnosis of Unilateral Massetric Hypertrophy of right side was made. The differential diagnosis included space infection, mumps and salivary gland neoplasm. However, there were no acute symptoms of space infection. Glandular salivation appeared normal, and no masses were detected on palpation. No significant alteration was observed in the panoramic radiograph (fig. 3). But the CT scan showed a clear enlargement of the right masseter muscle on axial sections. The density of right masseter was similar to that of left side masseter, indicating similar fibro-fatty content (fig.4, fig.5). As the lesion was very much evident in CT scan, patient was not advised for any further investigations. Correlating the clinical and imaging findings, diagnosis of idiopathic unilateral masseter muscle hypertrophy was made. No surgical intervention was indicated because the lesion was considerably small. Moreover, it is desirable to allow for the continuation of facial growth, by which the asymmetry can be naturally minimized considering the young age of patient.

## CASE 2

A twenty-year-old female patient reported to our department with complaints of a swelling on the left lower region of the face since two years. The swelling was gradual in onset and not associated with pain or discomfort. There was no history of trauma or accident. Medical and family histories were unremarkable.

A diffuse swelling was noticed involving the lower third of left side of face, approximately centered over the mandibular angle region (fig. 6). The swelling was around 2 cm in greatest diameter, roughly ovoid in shape. The skin over the region appears normal with no evidence of sinus opening or scarring. Palpation revealed a non-tender, soft to firm diffuse swelling. Intra oral examination did not show any visible or palpable changes (fig.7, fig.8). In view of the history and clinical examination, a provisional diagnosis of Unilateral Massetric Hypertrophy of left side was made. Mumps and salivary gland neoplasm were considered as differential diagnosis. No significant alteration was observed on panoramic radiograph. Ultrasonography of the right and left sides of face was done. An increased mass was seen on left side of face, density of which was comparable to that of muscle and continuous with masseter (fig.9, fig. 10). A final diagnosis of massetric hypertrophy was arrived at. No surgical intervention was recommended as the lesion was asymptomatic and considering the small size of swelling and young age of the patient.

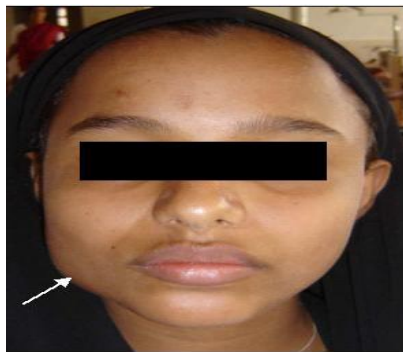

Fig.1

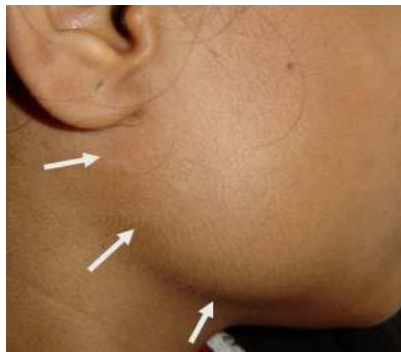

Fig.2

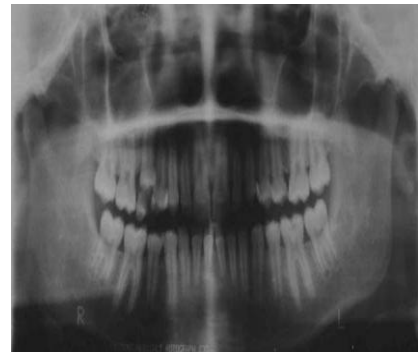


Fig. 3

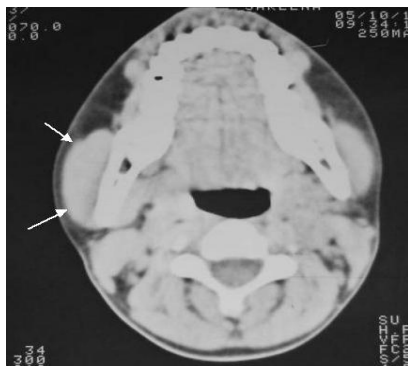


Fig. 4

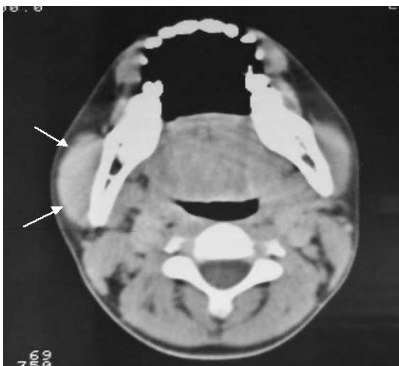


Fig. 5

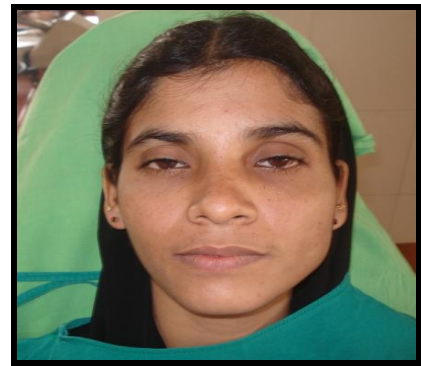

Fig.6

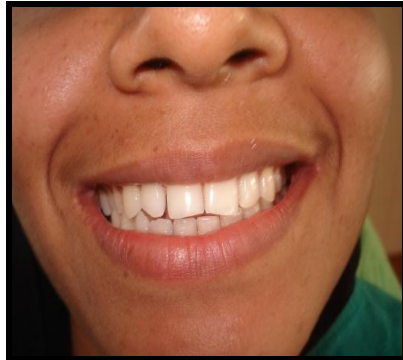

Fig.7

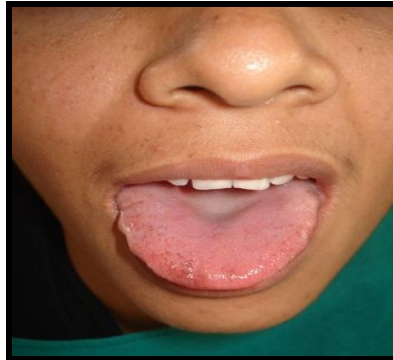

Fig. 8

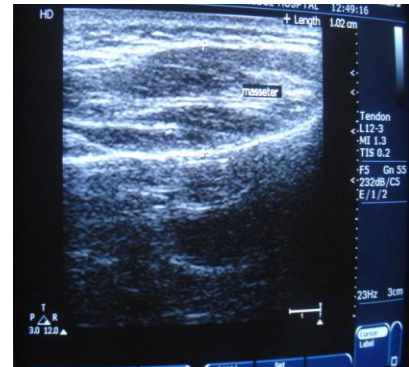


Fig.9

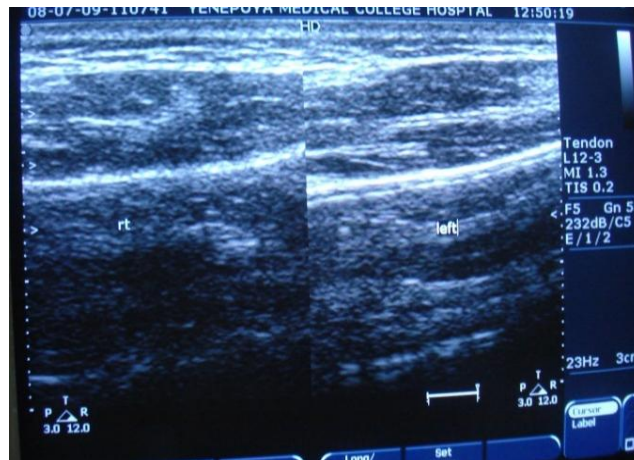

Fig. 10

**Figure legends:**

- Figure 1: Gross asymmetry due to swelling on the right side of face
- Figure 2: Swelling on the right angle of mandible
- Figure 3: OPG demonstrating no significant bony changes
- Figure 4: CT image (without contrast) showing enlargement of right masseter
- Figure 5: CT image (with contrast) showing enlargement of right masseter
- Figure 6: Diffuse swelling on left side of face
- Figure 7: No asymmetry or abnormality of tooth
- Figure 8: No asymmetry or abnormality of intra oral soft tissue structures
- Figure 9: Left masseter on USG
- Figure 10: Comparison of right and left masseter

**DISCUSSION**

The masseter, a thick quadrate masticatory muscle, arises from the

zygomatic arch and inserts into the inferior lateral aspect and angle area of the mandibular ramus. It is essential for adequate mastication and plays an important

role in facial aesthetics. Masticatory muscle enlargement is a rare condition which can be either congenital or acquired. [1] It presents unilaterally or bilaterally. Legg in 1880 described the first case in a 10 year old girl reporting enlargement of masseter and temporal muscles on both sides. [2] Hypertrophy may involve of all masticatory muscles (masseter, temporal and pterygoid) and is more common than isolated unilateral temporal or masseter muscle hypertrophy. [3] The etiology of masseter muscle hypertrophy has been attributed to a number of factors such as emotional stress, chronic bruxism, masseteric hyper-function and microtrauma. The term idiopathic masseter hypertrophy (IMMH) is used whenever a specific etiology is not evident. [4]

The diagnosis of MH can be done from clinical examination, history and muscle palpation. Muscle palpation test is associated with palpation of the muscle with fingers while the patient clenches his/her teeth so that the muscle is more prominent during contraction. With the muscle relaxed and the patient's mouth slightly open, extra-oral palpation using both hands will pinpoint the intramuscular location of the hypertrophy. [5] But imaging modalities such as ultrasound, CT and MRI may be helpful in showing homogeneous enlargement of the muscles. [1] MRI is a preferred technique for evaluating soft tissue while CT shows bony abnormalities better. Presenting complaints of the patients are usually of cosmetic concerns due to the obvious facial asymmetry as in the present cases and rarely they present with pain and discomfort due to tension on the hypertrophied muscle and limitation of mouth opening.

Therapy for masseteric enlargement is usually unnecessary, non-surgical modalities of treatment suggested include reassurance, tranquilizer or muscle relaxant, anti-anxietics and injection of very small dose of botulin toxin type A, a powerful neurotoxin (produced by the anaerobic organism *Clostridium botulinum*. When

injected in to muscle it causes interference with the neurotransmitter mechanism producing selective paralysis and subsequent atrophy of muscle. [6]

Excision of the internal layer of the masseter muscle and reduction of the thickened bone in the region of the mandibular angle via intraoral approach are also suggested treatments of choice. Complication from surgical incision of masseter includes Hematoma, facial nerve paralysis, infection and trismus.

## CONCLUSION

Masseter hypertrophy is a benign, asymptomatic enlargement of one or both masseter muscles. Proper clinical examination should be done and differential diagnosis of benign and malignant soft tissue lesions should be considered before a surgical treatment is planned, as most of the malignant skeletal muscle lesions and malignant parotid gland lesions may mimic masseter hypertrophy. The striking clinical features of a masseteric hypertrophy that may clinch the diagnosis are:

1. Asymptomatic slowly growing yet persistent enlargement in the mandibular angle region.
2. Non-tender, non-pulsatile, soft-fibrous growth with normal overlying skin.
3. Swelling that becomes prominent on clenching the teeth.

## REFERENCES

1. E Ozturk, H Mutlu, G Sonmez, HO Sildiroglu, CC Basekim, E Kizilkaya. Unilateral temporalis muscle hypertrophy with contralateral masseteric hypertrophy. Dentomaxillofacial Radiology 2007; 36:296–297.
2. Legg JW. Enlargement of temporal and masseter muscles on both sides. Trans Pathol Soc 1880; 31: 361–366.
3. Wilson PS, Brown AM. Unilateral temporalis muscle hypertrophy: case

- report. Int J Oral Maxillofac Surg 1990; 19:287–288.
4. Rispoli DZ, Camargo PM. Benign masseter muscle hypertrophy. Brazilian Journal of Otorhinolaryngology 2008; 74: 5.
  5. Sudhir R, Rajasekhar G, Nandagopal V, Gopal R. Esthetic Correction of Idiopathic Masseter Hypertrophy: Case Reports and Review. J Res Adv Dent 2013; 2:135-140.
  6. Smyth AG. Botulinum toxin treatment of bilateral masseteric hypertrophy, Br J Oral Maxillofac Surg. 1994;32: 29-33.

How to cite this article: Mufeed A, Gurukkal M, Shanoj RP et. al. Idiopathic unilateral masseteric hypertrophy - report of two cases and an update. Int J Health Sci Res. 2015; 5(6):658-662.

\*\*\*\*\*

#### **International Journal of Health Sciences & Research (IJHSR)**

#### **Publish your work in this journal**

The International Journal of Health Sciences & Research is a multidisciplinary indexed open access double-blind peer-reviewed international journal that publishes original research articles from all areas of health sciences and allied branches. This monthly journal is characterised by rapid publication of reviews, original research and case reports across all the fields of health sciences. The details of journal are available on its official website ([www.ijhsr.org](http://www.ijhsr.org)).

Submit your manuscript by email: [editor.ijhsr@gmail.com](mailto:editor.ijhsr@gmail.com) OR [editor.ijhsr@yahoo.com](mailto:editor.ijhsr@yahoo.com)