



Original Research Article

Surface Variations of Caudate Lobe and Its Clinical Implications

Joseph Abraham¹, Amrutha K V², Urmeese Biju Palatty²

¹Department of Anatomy, Government Medical College and Hospital, Chandigarh, India.

²Department of Anatomy, Amrita Institute of Medical Sciences and Research Centre, Cochin, Kerala, India.

Corresponding Author: Joseph Abraham

Received: 25/04/2015

Revised: 21/05/2015

Accepted: 22/05/2015

ABSTRACT

Introduction: The aim is to analyze the new anatomical variant of caudate lobe.

Materials and methods: 59 formalin fixed livers were collected from Department of Anatomy, Cochin, Kerala, India. Size, shape, accessory fissures, caudate process and papillary process of caudate lobe were noted.

Results: Rectangular shaped caudate lobe in 57.6 % (photo 1), bicornuate in 12% (photo2), pyriform in 18.6% (photo 3), inverted pyriform in 3.4%(photo 4), globular(photo 5) or heart shaped (photo 6) in remaining 10.2%. Vertical fissure extending upwards (photo 7) from lower boarder of caudate lobe was seen in 5.1%.Prominent papillary process (photo 8) was found on 3.4% cases. Oblique fissure on caudate lobe of the liver (photo 9) were found.

Conclusion: The findings of our study may be helpful for surgeons and radiologist to avoid possible errors in interpretations and subsequent misdiagnosis, and to assist in planning appropriate surgical approaches.

Key words- accessory fissures(AF),caudate lobe(CL), caudate process(CP), gall bladder(GB), inferior venecava (IVC), left lobe(LL), papillary process(PP), quadrate lobe(QL), right lobe(RL).

INTRODUCTION

The caudate lobe of the liver is described to be located on its posterior surface between inferior vena cava on the right, fissure for Ligamentum venosum on the left and porta hepatis anteriorly. Its right anterior part is connected to the right lobe of liver by caudate process. Below and to the left caudate lobe have small rounded papillary process. ^[1] The caudate lobe/ Spigelian lobe /Couinaud's segment I is a well demarcated anatomic segment of liver. Its separation is seen not only on the surface,

but also on the inside, with respect to blood supply and biliary drainage. There are many kinds of congenital abnormalities of the liver as agenesis of lobes, absence of its segments, deformed lobes, lobar hypotrophy or atrophy, transposition of the gall bladder. ^[2] Incidences of congenital anomalies of human liver are rare and occurrences of these are rarer than almost in any other organ of the body. ^[3,4] This study was carried out to ascertain the degree of anatomical independence of caudate lobe from rest of liver, to study morphology and

variations of caudate lobe to better the diagnosis and analysis of clinicopathological conditions such as cirrhosis of Liver. Although the segmental anatomy of the liver has been extensively researched, there are very few studies regarding the surface variations of the liver. Hence, we undertook this comprehensive study to observe and note the variations on the surface of the liver.

MATERIALS AND METHODS

59 formalin fixed livers were collected from Department of Anatomy. All the livers were apparently normal (any diseased or damaged livers were discarded) and belonged to adults of unknown age and gender. Any surface Variations from normal (as stated in Gray's anatomy) were noted, evaluated and photographed. The study was approved by Institutional ethical committee from our university. Shape of caudate lobe, accessory fissures were noted

RESULTS

Rectangular shaped caudate lobe in 57.6% (photo 1) bicornuate in 12% (photo2), pyriform in 18.6% (photo 3), inverted pyriform in 3.4%(photo 4), globular (photo 5) or heart shaped(photo 6) in remaining 10.2%. Vertical fissure extending upwards (photo 7) from lower boarder of caudate lobe was seen in 5.1%.Prominent papillary process (photo 8) was found on 3.4% cases. Oblique fissure on caudate lobe of the liver (photo 9) were found.

Table no: 1

Shape of caudate lobe	Percentage	Figures
Rectangular	57.6%	Photo 1
Bicornuate	12%	Photo 2
Pyriform	18.6%	Photo 3
Inverted pyriform	3.4%	Photo 4
Globular		Photo 5
Heart shaped	10%	Photo 6

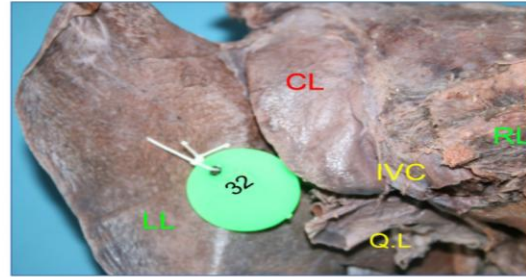


Photo 1

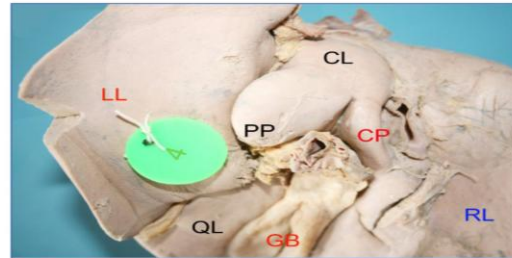


Photo 2

Photo 1. Photograph of posterior inferior aspect of liver showing rectangular caudate lobe.

Photo 2. Photograph of posterior inferior aspect of liver showing bicornuate caudate lobe. Papillary and caudate processes are extending to left and right lobe respectively

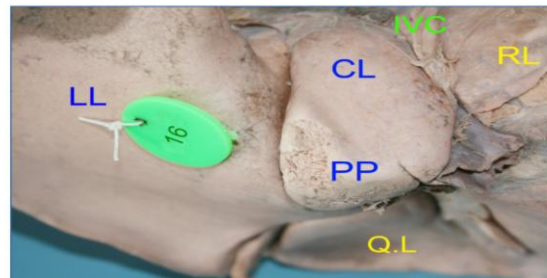


Photo 3

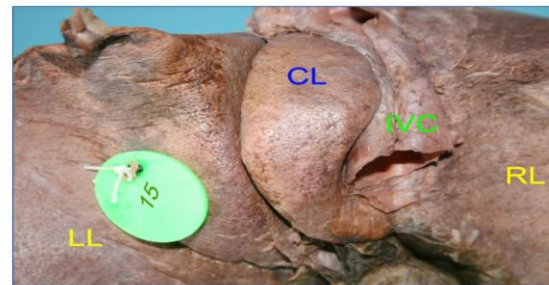


Photo 4

Photo 3. Photograph of posterior inferior aspect of liver showing pyriform caudate lobe. Papillary and caudate processes are extending to left and right lobe respectively. Also note inferior venecava and Q.L

Photo 4 Photograph of posterior inferior aspect of liver showing inverted pyriform caudate lobe. Also note inferior venecava lying right to the caudate lobe

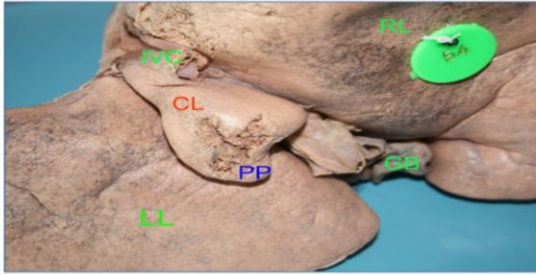


Photo 5

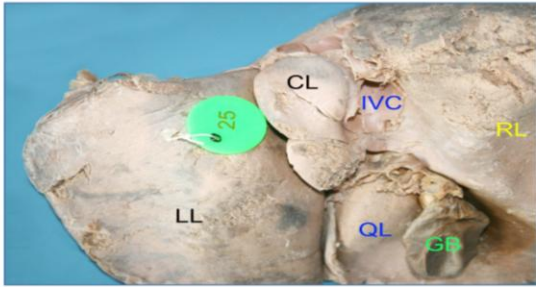


Photo 6.

Photo 5. Photograph of posterior inferior aspect of liver showing globular caudate lobe with papillary process. Right, left, caudate, lobes, gall bladder and inferior venecava can be seen.

Photo 6 Photograph of posterior inferior aspect of liver showing heart shaped caudate lobe .Also note right,left,caudate,quadrate lobes, gall bladder and inferior venecava

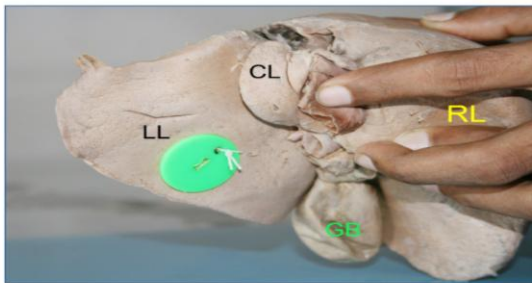


Photo 7

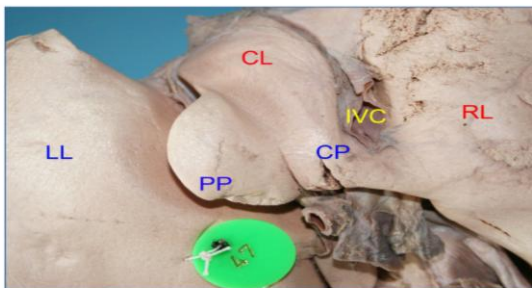


Photo 8

Photo 7 .Photograph of posterior inferior aspect of liver showing a vertical fissure on caudate lobe. . Right and left lobe can be seen.

Photo 8.Photograph of posterior inferior aspect of liver showing a prominent papillary process. Right, left, caudate lobes, and inferior venecava can be seen.

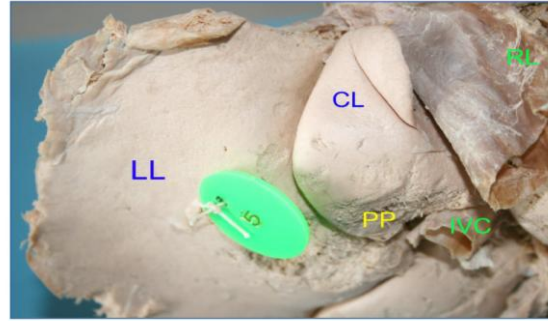


Photo 9

Photo 9 Photograph of posterior inferior aspect of liver showing a oblique fissure extending up on the caudate lobe. Also note papillary process, right, left lobe and inferior venecava

DISCUSSION

Morphological variations in caudate lobe were present in 24 (30%) specimens. Morphological variations in shape of caudate lobe were observed in 10 (12.5%) one of the specimens showed streak shaped hypo plastic caudate lobe. [5] We report Rectangular shaped caudate lobe in 57.6 % (photo 3) .Study of Sahni et al reported it as 94.5%. [6] The reason for this difference must be bodily habitus due to different set of population under study. We noted shapes of caudate lobe as bicornuate in 12% (photo2), pyriform in 18.6% (photo 4), inverted pyriform in 3.4%(photo 5),globular(photo 7) or heart shaped(photo 6) in remaining 10.2%. In another study, an abnormal, dumbbell like caudate lobe was found in one liver (1.81%). [7] In another study, enlargement of caudate process and paracaval portion was seen in 8 (10%) specimens. [5] Prominent papillary process (photo 10) was found on 3.4% cases. In another study, Enlargement of papillary process (*Spiegel's lobe* or *Couinaud's segment*) was seen in 4 (5%) specimens. [5] The papillary process of the caudate lobe was very large in one liver (1.81%). [7] Papillary process when examined on CT scan can be mistaken for enlarged lymph nodes. [8] Papillary process was absent in 33% cases. [6] A notch was noted on upper

border of caudate lobe (photo 8). Kogure et al. also noticed another notch along the inferior border in approximately half of the patients undergoing hepatectomy. ^[9,10] In an extensive study on variations of the liver, found notching along the inferior border of the caudate lobe in 18 percent of livers, a vertical fissure in 30 percent and prominent papillary process in 32 percent. In our study only one liver (1.81%) had a large papillary process. ^[10] There was a view that this external notch may be a vestige of the portal segmentation of the caudate lobe, as demonstrated in animal livers. Similarly the notch observed by the author may also be caused by portal segmentation of caudate lobe. ^[9] Vertical fissure extending upwards (photo 8) from lower boarder of caudate lobe was seen in 5.1%. Oblique fissure on caudate lobe of the liver (photo 9) were found. The accessory hepatic fissures are potential sources of diagnostic errors during imaging. Collection of any fluid in accessory fissures may be mistaken for a cyst, liver abscess or intrahepatic hematoma. ^[11] Notch or fissure separating papillary process from rest of the caudate lobe was seen in 2 (2.5%) specimens Vaibhav et al.(2014).A liver (photo 19) with unusual position of caudate, lobe was also noted.

CONCLUSION

In conclusion, Morphological variations of liver could be developmental in origin or due to the pressure given by diaphragm, peritoneal ligaments and other organs in relation with liver so developed during lifetime of a person .This study highlights the frequent occurrence of morphological variations on the caudate lobe of liver. The findings of our study may be helpful for surgeons and radiologist to avoid possible errors in interpretations and subsequent misdiagnosis, and to assist in planning appropriate surgical approaches.

ACKNOWLEDGEMENT

This research was supported by Dr. Minnie Pillay, HOD Anatomy. We thank our colleagues from Amrita Institute of Medical Sciences, Cochin, Kerala who provided insight and expertise that greatly assisted the research, although they may not agree with all of the interpretations of this paper.

We thank Dr. Biju Urmeese Palatty, assistant professor, Dept of Anatomy, for assistance and comments that greatly improved the manuscript.

REFERENCES

1. Banister LH et al (eds).1995.grays anatomy, 40th edn.Churchil Livingstone, London: 1164-1165
2. Susan Standring 2008.Gray's Anatomy: The anatomical Basis of Clinical Practice.40th edition, London: Churchill Livinstone, p1163-1174
3. Aktan ZA, Savas R., Pinar Y. and Arslan O. Lobe and segment anomalies of the liver. Journal of Anatomical Society of India.2001; (50), n. 1, p. 15-16.
4. Wakefield, PA. Congenital malformation of the liver-absence of the lobus spigelii, rudimentary quadrate and left lobes with enlargement of the right lobe. Journal of Anatomy and Physiology, 1898, vol. 33, n. 1, p. 50-53. PMID: 17232357 PMCID: PMC1327974.
5. Vaibhav Vasudevrao Phad S. A. Syed1, R. A. Joshi.Morphological Variations of Liver .International journal of health sciences and research. 2014; 4(9): 119-124
6. Sahni D, Jit I, Sodhi L. Gross anatomy of the caudate lobe of the liver. J Anat. Soc. India 2000; 49(2)123-126
7. Satheesha Nayak B .A Study on the Anomalies of Liver in the South Indian Cadavers. Int. J. Morphol. 2013; 31(2): 658-661
8. Yong Ho Auh, Alan Rosen et al. 1984.CT of the papillary process of the

- caudate lobe of the liver. AJR142:535-538.
9. Kogure K, Kuwano H, Fujimaki N and Makuuchi M. 2000. Relation among portal segmentation, proper hepatic vein and external notch of the caudate lobe in the human liver. Annals of surgery, 231), p. 223-8. PMID: 10674614. <http://dx.doi.org/10.1097/00000658-200002000-00011>
 10. Joshi SD, Joshi SS and Athavale SA. Some interesting observations on the surface features of the liver and their clinical implications. Singapore Medical Journal.2009; (50), n. 7, p. 715. PMID: 19644629.
 11. Auh YH, Lim JH, Kim KW, Lee DH, Lee MG, Cho KS. Loculated fluid collections in hepatic fissures and recesses: CT appearance and potential pitfalls. Radiographics. 1994 May; 14 (3): 529-40.

How to cite this article: Abraham J, Amrutha KV, Palatty UB. Surface variations of caudate lobe and its clinical implications. Int J Health Sci Res. 2015; 5(6):236-240.

International Journal of Health Sciences & Research (IJHSR)

Publish your work in this journal

The International Journal of Health Sciences & Research is a multidisciplinary indexed open access double-blind peer-reviewed international journal that publishes original research articles from all areas of health sciences and allied branches. This monthly journal is characterised by rapid publication of reviews, original research and case reports across all the fields of health sciences. The details of journal are available on its official website (www.ijhsr.org).

Submit your manuscript by email: editor.ijhsr@gmail.com OR editor.ijhsr@yahoo.com