



Original Research Article

## **Immunohistochemical Detection of Proliferative Tumor Cells in Cervical Cancer Using Monoclonal Antibody Ki-67**

Pradeep Sansanwal, Manoj Sankala, Gurpreet Singh, Megha Kathuria

Department of Pathology, Pt. B.D. Sharma PGIMS, Rohtak, India.

Corresponding Author: Manoj Sankala

Received: 24/04/2015

Revised: 15/05/2015

Accepted: 19/05/2015

### **ABSTRACT**

**Introduction:** Cancer of cervix is the second most common cancer among women worldwide. Various methods have been applied to determine the cell kinetic characteristics of excised tumour. In this study Ki-67 staining was carried out in cervical lesions and correlation of its expression was studied with histological grading of cervical carcinoma.

**Materials and methods:** A total of 100 cases comprising 25 non-malignant and 75 malignant lesions of cervix (SCC) were included. H&E and IHC staining were performed. For IHC, monoclonal antibody to Ki-67 nuclear antigen of mouse origin was used as primary antibody in 1:100 dilution and biotinylated goat antimouse as secondary antibody. Subsequently, Ki-67 labeling index was evaluated.

**Results:** Ki-67 positive cells were present in 1/3 basal layer in cases of cervicitis and squamous metaplasia with Ki-67 labeling index of 11% and 13% respectively. In low grade CIN, Ki-67 labeling index was 38% with positive cells in basal and middle layer of squamous epithelium. In high grade CIN, Ki-67 positive cells were present throughout whole thickness of squamous epithelium and labeling index 60%. Ki-67 labeling index was highest in poorly differentiated squamous cell carcinoma (37.4), least in well differentiated squamous cell carcinoma (23.4) and 31.2 in moderately differentiated.

**Conclusion:** Ki-67 immunostaining is helpful in grading CIN into low grade and high grade. It has linear correlation with histological grading of squamous cell carcinoma.

**Key Words:** CIN, Ki-67, Squamous cell carcinoma.

### **INTRODUCTION**

Cancer of cervix is the second most common cancer among women worldwide. In developing countries, among women, it accounts for 80% of cases. Worldwide cervical carcinoma alone is responsible for about 5% of all cancer deaths in women. <sup>[1]</sup>

Histological grading, mitotic index, lymphatic permeation and inflammatory reaction are useful parameters to diagnose cancer, predict the behavior and prognosis

of cancer and to assist in treatment selection.

<sup>[2,3]</sup> Other methods have been applied to determine the cell kinetic characteristics of excised tumour. Ki-67 monoclonal antibody utilized to demonstrate proliferating cells in G1, S, G2 and M phases of cell cycle. Ki-67 antigen is expressed by all proliferating cells during G1, S, G2 and M phases of cell cycle; while cells in quiescent phase G0 consistently lack this antigen. <sup>[4]</sup> It's use has provided information about the tumour cell

kinetics and provided useful prognostic information. [3]

The present study was conducted to study Ki-67 staining in cervical lesions and correlation of its expression with histological grading of cervical carcinoma.

## MATERIALS AND METHODS

The study was conducted on 100 cases comprising 25 non-malignant lesions and 75 malignant lesions (SCC) of cervix.

The hematoxylin & eosin stained slides were reviewed. The slides with representative areas were identified and corresponding blocks chosen.

Two microsections of 4-5  $\mu$ m thickness were prepared from each paraffin embedded block, one on albumin coated slide for H&E staining, and the other one on poly-L-lysine coated slide for IHC. H&E and IHC staining were subsequently performed on these sections.

Stained microsections were examined for specific histological changes, mitotic index in particular defined by number of mitosis (all phases) per 50 high power fields.

For IHC, monoclonal antibody to Ki-67 nuclear antigen of mouse origin was used as primary antibody in 1:100 dilution and biotinylated goat antimouse as secondary antibody.

Streptavidin biotin peroxidase method was used as a secondary detection system.

Sections from a well fixed, preserved breast carcinoma were used as a positive control, while the same section of breast carcinoma was stained simultaneously by omission of application of primary antibody being replaced by serum, thus acting as a negative control.

Ki-67 staining with brown granular nuclear reactivity dispersed over nucleus with focal denser nucleoli was taken to be positive. Subsequently, Ki-67 labeling index was evaluated (percentage of positively stained cells per 100 neoplastic cells) after counting at least 1000 cells in each case.

## RESULTS

The present study comprised a total of 100 cases, 25% benign and intraepithelial lesion of uterine cervix. 12 were diagnosed as cervicitis, 7 were squamous metaplasia and remaining 6 as CIN. Maximum patients were in the age group of 41-50 years (37 out of 100), almost equally distributed in rural and urban population (53% and 47% respectively). Maximum numbers of women were multigravida (97%) with 50% of them having attained menopause.

The presenting symptoms for many of the women were more than one with maximum number (32%) as postmenopausal bleeding. The presenting sign for most of them was discharge (26%), some with foul smelling discharge (46.15%), blood stained (34.61%) or whitish discharge (19.23%). 50% of women revealed cervix which bled on touch.

Ki-67 positive cells were present in 1/3 basal layer in cases of cervicitis and squamous metaplasia with Ki-67 labeling index of 11% and 13% respectively. In low grade CIN, Ki-67 labeling index was 38% with positive cells in basal and middle layer of squamous epithelium. In high grade CIN, Ki-67 positive cells were present throughout whole thickness of squamous epithelium and labeling index 60%.

**Table 1: Ki-67 immunostaining in benign and intraepithelial lesions of uterine cervix**

Diagnosis	Number of cases	Ki-67 positivity			Ki-67 labeling index
		1/3 <sup>rd</sup> basal layer	1/3 <sup>rd</sup> middle layer	1/3 <sup>rd</sup> superficial layer	
Cervicitis	12	+	-	-	11%
Squamous metaplasia	7	+	-	-	13%
Low grade CIN	4	+	+	-	38%
High grade CIN	2	+	+	+	60%

Mitotic index was highest in poorly differentiated squamous cell carcinoma (62/50 hpf), in moderately differentiated squamous cell carcinoma it was 54/50 hpf and least in well differentiated (42/50 hpf).

**Table 2: Relationship between tumour grade and mitotic index**

Tumour grade	Number of cases	Average mitotic index
Well differentiated	15	42/50 hpf
Moderately differentiated	42	54/50 hpf
Poorly differentiated	18	62/50 hpf

Ki-67 labeling index was highest in poorly differentiated squamous cell carcinoma (37.4), least in well differentiated squamous

cell carcinoma (23.4) and 31.2 in moderately differentiated.

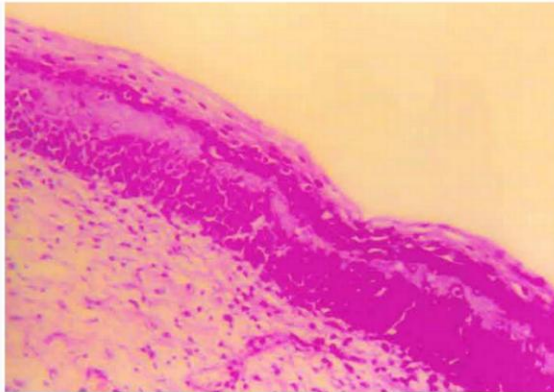
**Table 3: Relationship between tumour grade and average Ki-67 labeling index**

Tumour grade	Number of cases	Positive Ki-67 staining	
		Range	Mean
Well differentiated	15	13.4-34.6	23.4
Moderately differentiated	42	15.4-48.2	31.2
Poorly differentiated	18	15.6-58.4	37.4

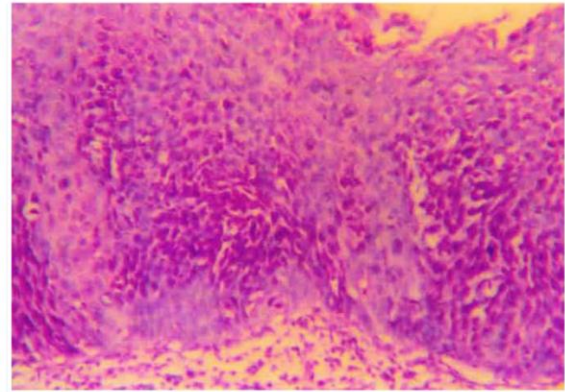
Both the proliferation markers, Ki-67 positivity and mitotic index were highest in poorly differentiated squamous cell carcinoma, i.e. 37.4 and 62/50 hpf respectively and least in well differentiated squamous cell carcinoma, i.e. 23.4 and 42/50 hpf respectively.

**Table 4: Relationship between tumour grade, Ki-67 positivity and mitotic index**

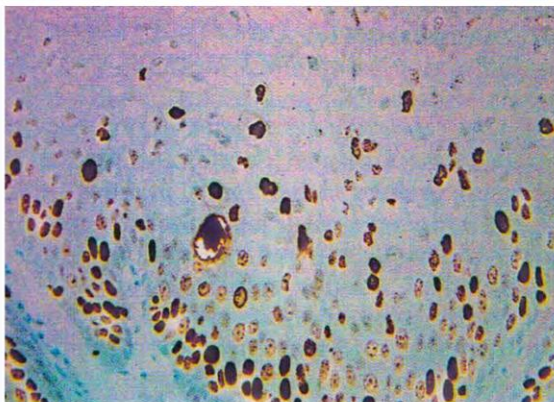
Tumour grade	Number of cases	Positive Ki-67 staining (%)	Mitotic index
Well differentiated	15	23.4 (13.4-34.6)	42/50 hpf
Moderately differentiated	42	31.2 (15.4-48.2)	54/50 hpf
Poorly differentiated	18	37.4 (15.6-58.4)	62/50 hpf



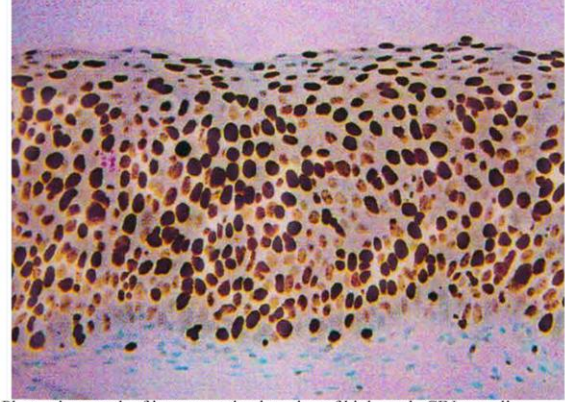
Photomicrograph of H&E stained section of low grade CIN (H&E x 100X)



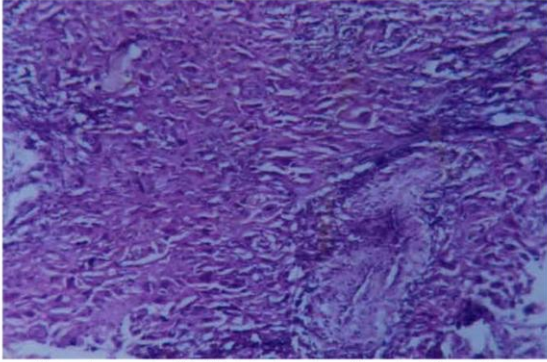
Photomicrograph of H&E stained section of high grade CIN (H&E x 100X).



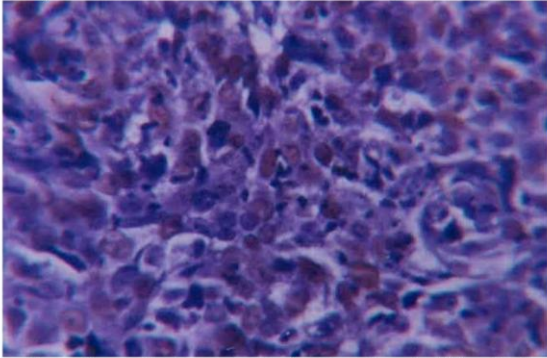
Photomicrograph of immunostained section of low grade CIN revealing Ki-67 positivity in lower and middle 1/3rd of squamous epithelium (IH x 100X).



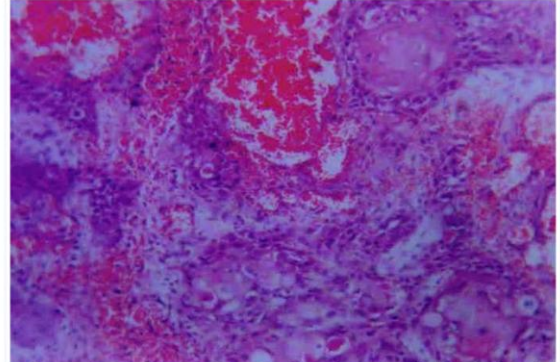
Photomicrograph of immunostained section of high grade CIN revealing Ki-67 positivity throughout the thickness of squamous epithelium (IH x 100X).



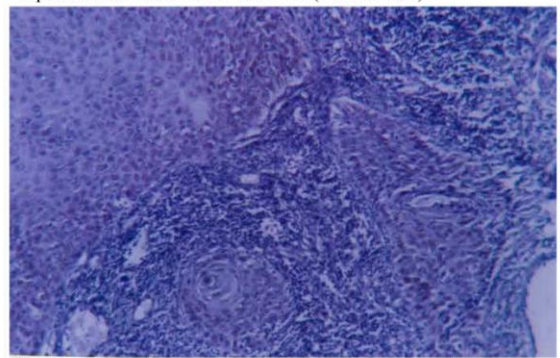
Photomicrograph of H&E stained section of poorly differentiated squamous cell carcinoma of cervix (H&E x 40X).



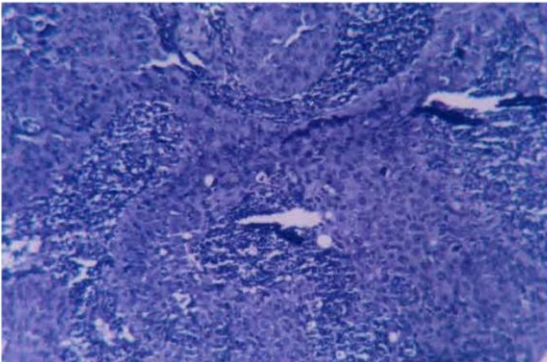
Photomicrograph of immunostained section of poorly differentiated squamous cell carcinoma of cervix (IH x 40X).



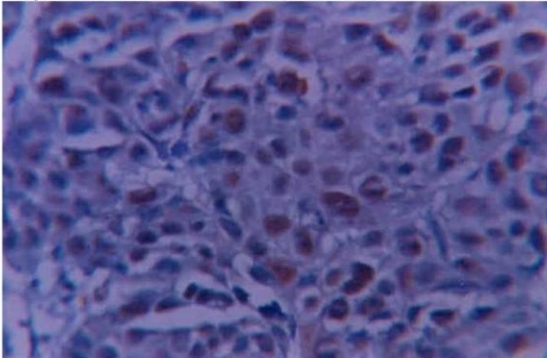
Photomicrograph of H&E stained section of well differentiated squamous cell carcinoma of cervix (H&E x 40X).



Photomicrograph of immunostained section of well differentiated squamous cell carcinoma of cervix (IH x 40X).



Photomicrograph of H&E stained section of moderately differentiated squamous cell carcinoma of cervix (H&E x 40X).



Photomicrograph of immunostained section of moderately differentiated squamous cell carcinoma of cervix (IH x 40X).

## DISCUSSION

Squamous cell carcinoma of cervix is a common gynaecological malignancy. The clinical stage of cervical cancers remains the main determinant of prognosis.

<sup>[5]</sup> Histological grading, mitotic index, lymphatic permeation and inflammatory reaction have been found useful parameters to predict behavior and prognosis of cancer. IHC and use of monoclonal antibody against transferrin receptor of Ki-67 has also been found useful. <sup>[3]</sup>

In our study, most of the women presented with clinical suspicion of carcinoma cervix. Cases of cervicitis and squamous metaplasia showed Ki-67 positive cells limited to lower 1/3 of stratified squamous epithelium in accordance with findings of Al-Saleh W et al, Averette HE et al and Schellhas HG et al. <sup>[6-8]</sup>

Percentage of Ki-67 positive cells in case of cervicitis and squamous metaplasia

were 11 and 13 respectively near to 14 and 11 observed by Al-Saleh W et al. [6]

Proliferation is an important factor in grading CIN lesions into low grade and high grade due to difference in distribution of proliferation markers in the epithelial layer of uterine cervix. [9,10]

In low grade CIN lesions, Ki-67 positive cells were present in lower and middle 1/3 of stratified squamous epithelium, while in high grade, they were present in all layers of squamous epithelium in accordance with findings of Al-Saleh W et al, Kruse A et al and Butten J et al. [6,11,12]

Percentage of Ki-67 positive cells in low grade and high grade CIN lesions were 38% and 60% respectively. Al-Saleh W et al had reported 36% and 62% respectively. [6]

In our study, we noted a significant increase in percentage of Ki-67 antigen positive cells in squamous intraepithelial lesion as compared with that in cervicitis or squamous metaplasia and in high grade squamous intraepithelial lesion as compared with that in low grade squamous intraepithelial lesion. In addition, a shift was also seen in expression of this antigen from parabasal cells to intermediated and superficial layer. These results are in accordance with other data reporting higher number of mitotic figures and increased labeling indices for 3H thymidine or PCNA with increasing dysplasia. [13-15]

The potential usefulness of determining the proliferative index of tumours lies in the application of this knowledge in predicting the behavior and prognosis of individual tumours and in formulating treatment strategies based thereon. [16]

In our study, average mitotic index in well, moderately and poorly differentiated squamous cell carcinoma in 50 hpf was 40, 52, and 58 respectively with highest in poorly differentiated carcinoma. Wong FWS et al had reported 42, 54 and 62 with

highest in moderately differentiated squamous cell carcinoma. [3]

The mean ki-67 labeling index in well, moderated and poorly differentiated squamous cell carcinoma were 23.4, 31.2 and 37.4 respectively with highest value in poorly differentiated similar to that reported by Chung TKH et al. [5]

A linear correlation was observed between histological grade Ki-67 index and mitotic index in squamous cell carcinoma of cervix with highest value in poorly differentiated carcinoma.

Sachin et al demonstrated that Ki-67 staining correlates well with other measures of cell proliferation and reported that Ki-67 staining and mitotic count correlates in some but not all tumour types. [17]

## CONCLUSION

Ki-67 immunostaining is helpful in grading CIN into low grade and high grade. Ki-67 immunostaining has linear correlation with histological grading of squamous cell carcinoma.

## REFERENCES

1. WHO (1997). The World Health Report 1997, Report of the Director General WHO.
2. Graem N, Helweg-Lausen K. Mitotic activity and delay in fixation of tumour tissue. Acta Path Microbiol Scand [A]. 1979;87:375-8.
3. Wong FWS. Immunohistochemical detection of proliferating tumour cells in cervical cancer using monoclonal antibody Ki-67. Gynecol Obstet Invest. 1994;37:123-6.
4. Gerdes J, Lemke H, Baisch H, Wacker HH, Schwab U, Stein H. cell cycle analysis of a cell proliferation associated human nuclear antigen defined by the monoclonal antibody Ki-67. J Immunol. 1984;133:1710-5.
5. Chung TKH, Cheung TH, Wong FWS, Wong YF. Ki-67 and AgNOR's staining

- in squamous cell carcinoma of the cervix: A comparison. *Gynaecol Obstet Invest.* 1994;37:127-9.
6. Al-Saleh W, Delvenne P, Greimers R, Fridman V, Dogen S, Boniver J. Assessment of Ki-67 antigen immunostaining in squamous intraepithelial lesions of uterine cervix. *Anatomic pathology. Am J Clin Pathol.* 1995;104(2):154-60.
  7. Averette HE, Weinstein GD, Frost P. Autoradiographic analysis of cell proliferation kinetics in human genital tissues:I. Normal cervix and vagina. *Am J Obstet Gynecol.* 1970;108:8-17.
  8. Schellhas HF, Health G. Cell renewal in the human cervix uteri: A radioautographic study of DNA, RNA and protein synthesis. *Am J Obstet Gynecol.* 1969;104:617-32.
  9. Kamer SA, Yalman D, Ozer E, Sayhan S, Hanhan M, Ozsaran A, et al. Changes of Ki-67 index in squamous cell carcinoma of the cervix during the early course of radiotherapy and prediction of prognosis. *Eur J Gynaecol Oncol.* 2003;24(3-4):287-92.
  10. Steven SA. The hematoxylin. In: Bancroft JD, Steven SA, editors. *Theory and Practice of Histological Techniques.* 3rd ed. London: Churchill Livingstone; 1990.p.107-17.
  11. Kruse AJ, Baak JPA, de Bruin PC. Ki-67 immunoquantitation in cervical intraepithelial neoplasia (CIN): a sensitive marker for grading. *J Pathol.* 2001;193:48-54.
  12. Demeter LM, Stoler MH, Broker TR, Chow LT. Induction of proliferating cell nuclear antigen in differentiated keratinocytes of human papillomavirus infected lesions. *Hum Pathol.* 1994;25:343-8.
  13. Mittal KR, Demmopoulos RI, Goswami S. Proliferating cell nuclear antigen (cyclin) expression in normal and abnormal cervical squamous epithelia. *Am J Surg Pathol.* 1993;17:117-22.
  14. Tanaka T. Proliferative activity in dysplasia, carcinoma in situ and microinvasive carcinoma of uterine cervix. *Path Res Pract.* 1986;181:531-9.
  15. Rubio CA, Lagerlof B. Proliferating and non-proliferating cell compartments in cervical dysplasia and carcinoma in situ. *Acta Pathol Microbiol Scand.* 1975; 883:189-91.
  16. Shackney SE, Mc Cormack GW, Cuchural GJ. Growth rate patterns of solid tumours and their relation to responsiveness to therapy. *Ann Intern Med.* 1978;89:107-21.
  17. Hitchcock CL. Ki-67 staining as a means to simplify analysis of tumor cell proliferation. *Am J Clin Pathol.* 1991;96 (4):444-6.

How to cite this article: Sansanwal P, Sankala M, Singh G et. al. Immunohistochemical detection of proliferative tumor cells in cervical cancer using monoclonal antibody ki-67. *Int J Health Sci Res.* 2015; 5(6):166-171.

\*\*\*\*\*