

Case Report

Haemorrhagic Ascites: A Rare Presentation of Peritoneal Endometriosis

Swati Sharma^{1*}, Arisetty Himabindu^{2*}, Nawin Kumar^{1**}, Manna Valiathan^{3*}¹Associate Professor, ²Junior Resident, ³Professor,
*Department of Pathology, **Department of Surgery,

Kasturba Medical College, Manipal University, Manipal, Karnataka, India

Corresponding Author: Swati Sharma

*Received: 29/04/2015**Revised: 22/05/2015**Accepted: 26/05/2015*

ABSTRACT

Endometriosis is defined as the presence of endometrial glands and/ or stroma at extrauterine sites. These ectopic endometrial implants can occur nearly anywhere in the body. We here report a rare presentation of peritoneal endometriosis in a 32 years old female who presented with haemorrhagic ascites and posed a diagnostic dilemma.

Key words- Ascites, endometriosis, peritoneum.

INTRODUCTION

Endometriosis is a common benign disorder of the female genital system usually seen in reproductive age group. This is a rare cause for haemorrhagic ascites. Only 63 cases have been described in the literature so far. ⁽¹⁾ Common gynaecologic disorders associated with ascites include ovarian tumours, ovarian hyperstimulation syndrome and Meig's syndrome. ⁽²⁾

CASE REPORT

A 32 year old female presented to the Surgery outpatient department of a tertiary care hospital with complaints of abdominal distension since 3 months and fatigue for last 2 months. Abdominal distension was insidious in onset and gradually progressive. It was not associated with abdominal pain. The patient had no

menstrual abnormalities, jaundice, vomiting or bowel disturbances. On examination, flanks were full. A vague mass was noted in the periumbilical area which was soft, lobulated and non-tender. This was associated with shifting dullness. Routine haematological and biochemical investigations were normal. Diagnostic laparoscopy was performed. Intra-operative, abdomen was found to be filled with haemorrhagic fluid. Around 2500 ml was drained. Further, exploration revealed multiple large peritoneal deposits, along with foci of mucinous material deposited at multiple sites (Figure 1). Adhesions were found between the small bowel and the abdominal wall. A clinical diagnosis of pseudomyxoma peritonei/ tuberculosis of the abdomen were suspected. Peritoneal deposits biopsy and ascitic fluid were sent

for pathologic examination. Peritoneal fluid analysis showed numerous hemosiderin laden and foamy macrophages. There was no evidence of malignancy. Peritoneal biopsy showed multiple endometrial glands in late proliferative to early secretory phase in endometrial stroma with fibrocollagenous areas showing degenerative changes, cholesterol clefts and clusters of hemosiderin macrophages (Figure 2,3). Biopsy was suggestive of peritoneal endometriosis. Patient was referred to Gynecology department for further management.

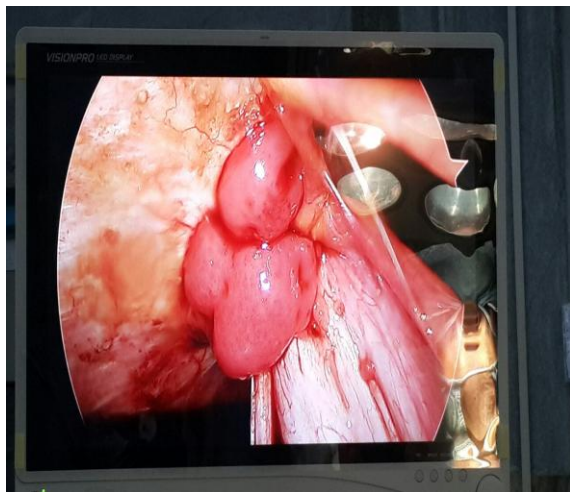


Figure 1- Large peritoneal deposits on laparoscopy

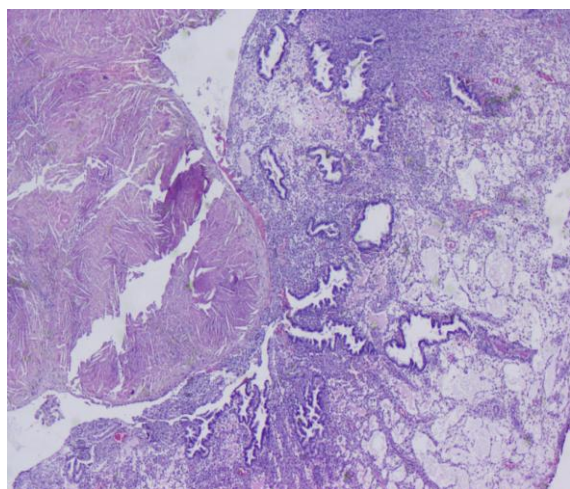


Figure 2- Multiple endometrial glands with endometrial stroma, H&E X 20

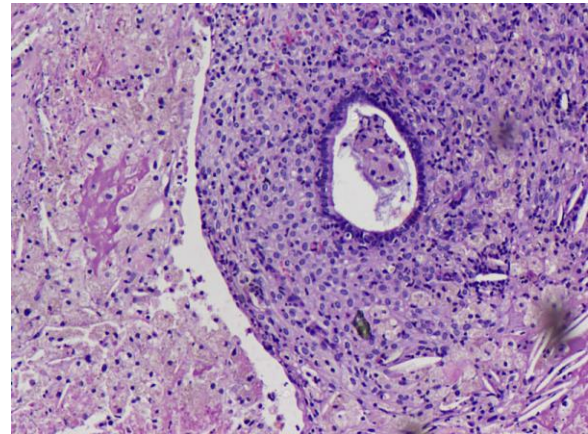


Figure 3- Degenerative changes, cholesterol clefts and clusters of hemosiderin macrophages, H & E X100

DISCUSSION

The term endometriosis was first coined first in the year 1921 by Sampson et al. ⁽³⁾ The incidence of endometriosis in the general female population is not known. This is a common benign condition overall affecting 5-10% of females in their reproductive age. ⁽⁴⁾ However, in women undergoing evaluation for infertility and dysmenorrhea/ pelvic pain its incidence is nearly 30%, and 40%–50% respectively. ⁽⁵⁾ Implanted ectopic endometrial tissue usually occurs at serosal surface of the ovaries, other common locations being the fallopian tubes, pelvic peritoneum and pelvic ligaments. Other atypical locations documented are abdominal wall, peritoneum, gastrointestinal, urinary tract, chest and cerebrum. ⁽⁴⁾ Few cases with malignant transformation have also been reported. Extraovarian endometriosis with malignant transformation has been found to have a prevalence of 0.8-0.9%. Usually malignant transformation to endometrioid carcinoma is noted. ⁽⁶⁾ Pathogenesis of endometriosis has been described in literature with various theories such as implantation theory, coelomic metaplasia, direct extension, regurgitation theory etc but the precise mechanism completely describing this condition is yet to be established. ⁽⁷⁾

The first description of endometriosis presenting with haemorrhagic ascites was by Brews in the year 1954. ⁽⁸⁾ Hemorrhagic ascites is defined as ascitic fluid containing more than 50,000 red blood cell per cubic millimeter. ⁽⁹⁾ This ascitic fluid volume drained can range from 150 -10,000 ml. ⁽¹⁰⁾ Report of recurrent ascites with recurrent endometriosis has also been described. ⁽¹¹⁾ Bernstein et al ⁽¹²⁾ in 1961 proposed that rupture of the chocolate cysts release blood and endometrial cells into the peritoneal cavity which causes haemorrhagic ascites. But later ascites was found to be associated in cases without any rupture of chocolate cysts. Hence the possibility of irritation on serosal surfaces caused by free blood in the peritoneal cavity leading to formation of ascites and dense adhesions was proposed. ⁽¹³⁾ Peritoneal endometriosis is reported in a wide range of age varying from 19- 51 years and abdominal distension being the most common clinical presentation seen in 71.4% of the patients. ⁽¹⁾ The other common symptoms are abdominal pain, menstrual abnormalities like dysmenorrhea, menometrorrhagia etc, anorexia and weight loss. However, our patient did not have any menstrual complaints, weight loss or anorexia. Pleural effusion is found to be associated with ascites in these cases and described in 38.1% patients. More commonly it is noted in nulliparous (66.7%) black African women(52.4%). ⁽¹⁾

The other causes of haemorrhagic ascites include peritoneal tuberculosis, carcinomatosis and pancreatic malignancy. ⁽¹⁴⁾ The diagnosis of peritoneal endometriosis can be considered after clinically excluding other causes and can be confirmed on intra-operative laparotomy/ laparoscopic evaluation followed by a histopathologic diagnosis. Characteristically, on microscopy, endometriosis shows few endometrial glands with or without

associated endometrial stroma along with haemorrhage. Our case on peritoneal biopsy showed the typical picture.

Treatment of endometriosis can be medical or surgical. It depends on the severity of symptoms, age and the patient's desire to maintain or restore fertility. For medical treatment drugs such as danazol, gonadotropin releasing hormone agonists, oral contraceptive pills and other progesterone agents are used. These drugs create a state of pseudo pregnancy, pseudo menopause or chronic anovulation, hereby reducing the normal and ectopic endometrial tissue by making it inactive and atrophic. Usually medical treatment is opted for cases with dyspareunia and pelvic pain. Patients with associated infertility are treated surgically with laparoscopic ablation or with advanced assisted reproductive techniques so as to preserve fertility.

CONCLUSION

Peritoneal endometriosis presenting as haemorrhagic ascites is a rare presentation. This case was unique as the patient had no associated menstrual complaints. Clinically, pseudomyxoma peritonei or tuberculosis was suggested. However, histopathology was diagnostic for peritoneal endometriosis. We emphasize that a differential diagnosis of endometriosis should be considered in a young female presenting with ascites.

REFERENCES

1. Gungor T, Kanat-Pektas M, Ozat M, Zayifoglu Karaca M. A systematic review: Endometriosis presenting with ascites. Arch Gynecol Obstet. 2011;283(3):513–8
2. Mumtahana fidia;jiao jun;cui baoxia. A Rare Presentation of Endometriosis with Recurrent Massive Hemorrhagic Ascites which Can Mislead. Int J womens Heal Reprod Sci. 2014;2(1)

3. Sampson JA. Perforating hemorrhagic (chocolate) cysts of the ovary. *Am J Obstet Gynecol* 1921;2:526-528
4. Agarwal N, Subramanian A. Endometriosis – Morphology, Clinical Presentations and Molecular Pathology. *J Lab Physicians*. 2010;2(1):1–9
5. Sait KH. Massive ascites as a presentation in a young woman with endometriosis: a case report. *Fertil Steril*. 2008;90(5):2015–7
6. Marchand E, Hequet D, Thoury A, Barranger E. Malignant transformation of superficial peritoneal endometriosis lesion. *BMJ Case Rep*. 2013;2013:007730
7. Witz C A. Current concepts in the pathogenesis of endometriosis. *Clin Obstet Gynecol*. 1999;42:566–85
8. Brews A. Endometriosis including endometriosis of the diaphragm and Meigs' syndrome. *Proc Roy Soc Med*. 1954;47:461
9. Morgan TL, Tomich EB, Heiner JD. Endometriosis presenting with hemorrhagic ascites, severe anemia, and shock. *Am J Emerg Med*. 2013;31(1):272
10. Muneyyirci-Delale O, Neil G, Serur E, Gordon D, Maiman M, Sedlis a. Endometriosis with massive ascites. *Gynecol Oncol*. 1998;69(1):42–6
11. Ekoukou D, Guilherme R, Desligneres S, Rotten D. Endometriosis with massive hemorrhagic ascites: a case report and review of the literature. *J Gynecol Obstet Biol Reprod*. 2005;34(4):351–9
12. Bernstein JS, Perlow V, Brenner JJ. Massive ascites due to endometriosis. *Am J Dig Dis*. 1961;6:1–7
13. Samora-mata J, Feste JR. *JSLs Endometriosis Ascites: A Case Report*. 1999;229–31
14. Shabeerali TU, Rajan R, Kuruvilla a. P, Noronha S, Krishnadas D, Shenoy KT, et al. Hemorrhagic ascites: Are we missing endometriosis? *Indian J Gastroenterol*. 2012;31(4):195–7

How to cite this article: Sharma S, Himabindu A, Kumar N et. al. Haemorrhagic ascites: a rare presentation of peritoneal endometriosis. *Int J Health Sci Res*. 2015; 5(6):729-732.
