

*Case Report*

## Unusual Cardiac Emergency in a Healthy Young Woman Following Gynecological Surgery: A Rare Case Report

Kavitha G<sup>1\*</sup>, Rathna Ramamoorthy<sup>2\*</sup>, Shanmugasundaram<sup>1\*\*</sup>, Rajarajeshwari S<sup>3\*</sup>

<sup>1</sup>Assistant Professor, <sup>2</sup>Associate Professor, <sup>3</sup>Professor and Head,

\*Department of Obstetrics and Gynecology, \*\*Department of Cardiology,  
Velammal Medical College Hospital and Research Institute, Madurai, Tamil Nadu, India.

Corresponding Author: Kavitha G

Received: 18/04/2015

Revised: 08/05/2015

Accepted: 11/05/2015

### ABSTRACT

Takotsubo cardiomyopathy is a rare reversible cardiac condition often preceded by emotional or physical stress. Diuretics and beta-blockers are commonly used for the treatment. It has an excellent prognosis with prompt multidisciplinary management. This case report describes a 35 year old female patient who developed Takotsubo cardiomyopathy in the immediate post-operative period following laparotomy for ovarian cystectomy under general anesthesia. Patient was effectively managed and discharged after complete recovery following 15 days stay in the hospital.

**Keywords:** Takotsubo cardiomyopathy, non-ischemic cardiomyopathy, ovarian-cystectomy.

### INTRODUCTION

Takotsubo cardiomyopathy also known as transient apical ballooning syndrome [1] is a type of non-ischemic cardiomyopathy. The name of the condition is derived from the shape of the left ventricle which resembles a Japanese pot used to trap an octopus (tako in Japanese means octopus, tsubo means pot). The incidence of takotsubo cardiomyopathy is 1-2% of patient presenting with an acute myocardial infarction. [2] The most common symptoms are chest pain (44%), dyspnea (28%), [3] pulmonary edema, syncope and rarely cardiogenic shock. Typically, there is hypokinesis or akinesis of mid and apical segments of the left ventricle with hyperkinesis of the basal walls, producing a

balloon like appearance of the distal ventricle during systole on echocardiography. The common ECG findings are ST segment elevation typically in the precordial leads, but the ECG can be normal or show T or Q wave abnormalities, [4] and a small rise in cardiac troponin T is invariably seen. Coronary angiography typically demonstrates normal vessels. Acute complications of stress cardiomyopathy are heart failure, tachyarrhythmias, bradyarrhythmias, mitral regurgitation, cardiogenic shock, [5-8] left ventricular outflow obstruction, apical thrombus formation and stroke.

## CASE REPORT

A 35 year old nulliparous female with ASA grade-1, weighing 73kg was planned for laparotomy with left ovarian cystectomy. Her medical history revealed primary infertility and pituitary microadenoma for which she was on treated with cabergoline, seven years back. Her surgical history includes laparoscopic adhesiolysis with left ovarian cyst decompression one year back diagnosed while investigating for primary infertility. She was not on any medication. Baseline vital signs were within normal limits. On examination her respiratory and cardiovascular system was normal. All preoperative imaging and tests including serum prolactin (21.33ng/dl) were normal.

In the operating theatre procedure was done under general anaesthesia and monitored with standard non-invasive monitors. Pre-oxygenation was done with 100% FiO<sub>2</sub> for 5 minutes. Then general anesthesia was induced with fentanyl and propofol. Once manual ventilation was confirmed, atracurium was administered intravenously, laryngoscopy was performed and endotracheal intubation was done. General anesthesia was maintained with isoflurane in oxygen and air. Patient underwent laparotomy with adhesiolysis and ovarian-cystectomy. Patient was hemodynamically stable till the end of the procedure. The patient was extubated uneventfully and shifted to the post-operative ward. Patient developed severe hypotension (80/50mm Hg) and tachycardia (145bpm) within half an hour of surgery. Respiratory rate was 18 and SPO<sub>2</sub> was 92% with normal air. With the suspicion of intra-abdominal hemorrhage, intravenous fluids were rushed, arrangements for blood transfusion were made and emergency ultrasound was done to look for intra-abdominal collection, but there was no significant collection.

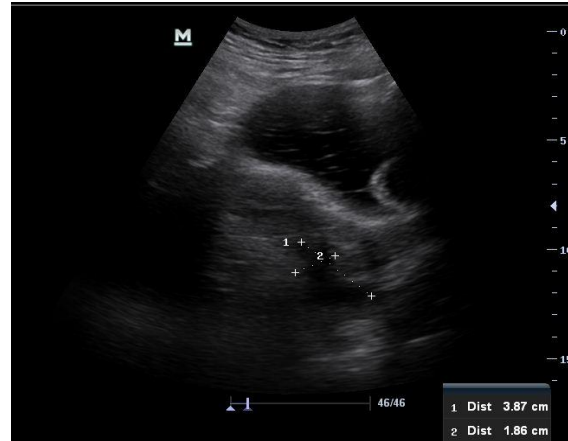


Figure 1: USG abdomen and pelvis revealed no intra-abdominal collection.

On auscultation all the lung fields were clear and S<sub>3</sub> gallop was heard, an emergency physician was called. ECG showed sinus tachycardia with low voltage complexes and poor R wave progression.

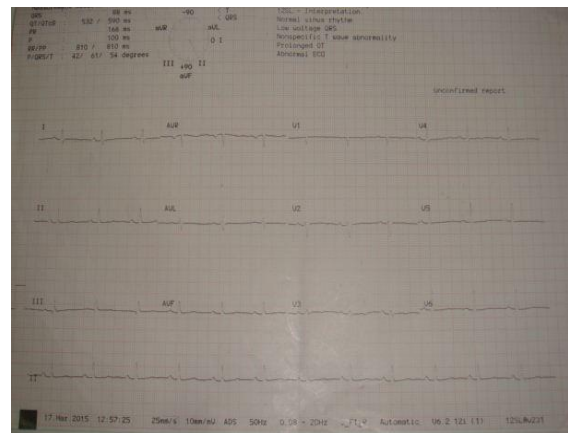


Figure 2: Preoperative ECG showing normal heart rate.

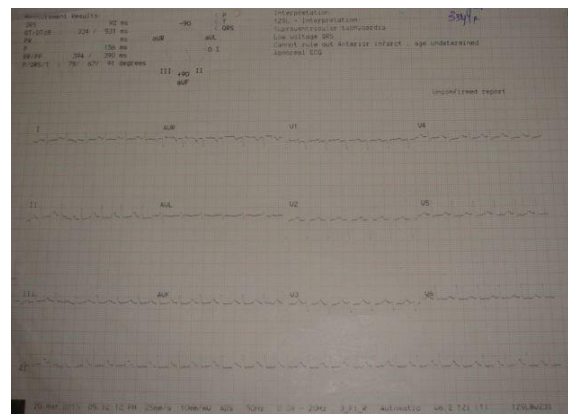

Figure 3 :Post-operative ECG shows sinus tachycardia, low voltage complexes and poor R wave progression.

X-ray revealed cardiomegaly. Cardiologist was consulted and echocardiography was done which showed hyperkinetic basal segment with dyskinetic

mid and distal left ventricular segment and ejection fraction of 26% with mild MR and LV dysfunction.

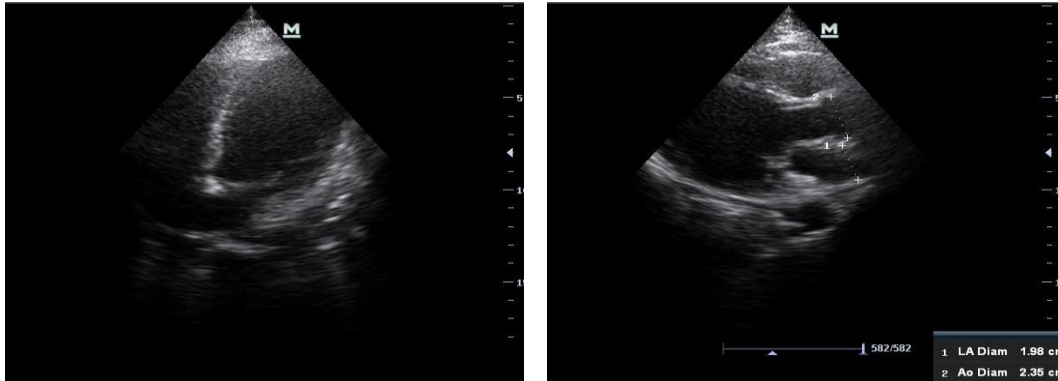


Figure 4: Echocardiography showing dilated and dyskinetic mid and distal left ventricular segment.

The Troponin T levels were normal. With the suspicion of stress-cardiomyopathy, the patient was shifted to SICU. The patient gradually developed respiratory distress and brought out pink frothy sputum with bilateral basal crepitations on auscultation, which indicated the onset of pulmonary edema. Patient was started on Furosemide, Beta-blocker, Atorvastatin, Digoxin, Enalapril, Torsemide, low molecular weight heparin prophylaxis, NTG drip (adjusted according to BP), restricted fluid intake. She was followed up with echocardiography to look for development of complication. Patient improved within 48hrs of starting treatment and was shifted from SICU to ward on 6<sup>th</sup> post-operative day and discharged after complete recovery.

## DISCUSSION

Takotsubo cardiomyopathy is a transient left ventricular dysfunction that clinically mimics acute coronary syndrome.<sup>[9]</sup> It is also known as broken heart syndrome or stress induced cardiomyopathy. The etiology of the disease is multifactorial and the proposed causes include elevated plasma catecholamine levels, abnormal response to

catecholamine, vasospasm and failure of microvasculature. The catecholamine levels can reach 7-34 times higher than normal values and 2-3 times higher than levels in patients with myocardial infarction.<sup>[10]</sup> Stress cardiomyopathy is much more common in women than men.<sup>[5-7,11,12]</sup> It primarily affects post-menopausal women. In a review of ten prospective series women accounted for 80-100% of cases with a mean age of 61-76 years.<sup>[11]</sup>

The Mayo-clinic diagnostic criteria are a useful tool for diagnosis of the condition. A risk score has been proposed to predict the likelihood of acute heart failure based on the presence or absence of the following three variables: age more than 70 years, presence of physical stressor and left ventricular ejection fraction (LVEF) less than forty percent.<sup>[13]</sup> The likelihood of developing acute heart failure was less than 10% in the absence of these risk factors. With one, two or three risk factors present, the risk was approximately 28%, 58% and 85% respectively.

Despite the severity of acute illness, this condition is a transient disorder managed with supportive therapy. At present there are no optimal medical regimens

available, but it is reasonable to treat these patients with the standard medication for left ventricular systolic dysfunction. These include angiotensin converting enzymes inhibitors, beta blockers, and diuretics with cautious fluid resuscitation in patients with hypotension. Treatment with aspirin is suggested in the presence of co-existing coronary atherosclerosis. Anticoagulants are needed if intraventricular thrombus is detected.

There are some perioperative management goals and guidelines like providing adequate anxiolysis with psychological and pharmacological approach, considering regional anesthesia versus general anesthesia, minimizing sympathetic stimulation by a brief laryngoscopy, smooth intubation and extubation, avoiding hemodynamic instability, choosing anesthetic agents with least myocardial depressant effect for induction and maintenance, avoiding volume overload, providing adequate pain relief can prevent occurrence of Takotsubo cardiomyopathy. Mortality rate of around 1-3% [14] and recurrence rate of 3.5% [15] has been reported.

The reason for Takotsubo cardiomyopathy in our patient who was a young woman with no co morbidities could be because of the stress related to the surgical procedure, as it was the second procedure for the ovarian cyst and the anxiety about her fertility preservation. Our patient presented as shock, which is an unusual presentation of the disease, the most common presentation being chest pain.

## CONCLUSION

Acute cardiac complications occur infrequently in young women in the immediate post-operative period and some of the cardiac conditions are rare and provide a diagnostic challenge to the treating gynecologist. The most common diagnosis

for a patient with tachycardia and hypotension in the immediate post-operative period is hemorrhage, if volume replacement does not improve the hemodynamic condition the gynecologist has to think of possible differential diagnosis and involve relevant medical specialists early to achieve the best outcome for the patient. The patients have a favorable outcome once recovered from the acute stage of the disease and the long term prognosis is excellent.

## REFERENCES

1. Eshtehardi P, Koestner SC, Adorjan P, et al. Transient apical ballooning syndrome- clinical characteristics, ballooning pattern, and long-term follow-up in a Swiss population. *Int J cardiol* 2009 jul;135(3):370-5.
2. Prasad A, Kerman A, Rihal CS. Apical ballooning syndrome (Tako-Tsubo or stress cardiomyopathy): a mimic of acute myocardial infarction. *Am Heart J* 2008;155(3):408-417.
3. Miki M, Atsuo I, Eiji T, et al. Takotsubo cardiomyopathy after Cesarean: case report and published work review of pregnancy-related cases. *J Obstet Gynaecol Res* 2014 Jun;40(6):1534-39.
4. Akashi YJ, Nakazawa K, Sakakibara M, et al. The clinical features of takotsubo cardiomyopathy. *QJM* 2003 Aug;96(8):563-73.
5. Bybee KA, Kara T, Prasad A, et al. Systematic review: transient left ventricular apical ballooning: a syndrome that mimics ST-segment elevation myocardial infarction. *Ann Intern Med* 2004 Dec7;141(11):858.
6. Tsuchihashi K, Ueshima K, Uchida T, et al. Transient left ventricular apical ballooning without coronary artery stenosis: a novel heart syndrome mimicking acute myocardial infarction. Angina Pectoris-Myocardial Infarction Investigations in Japan. *J Am Collcardiol* 2001 Jul;38(1):11-8.
7. Sharkey SW, Lesser JR, Zenorich AG, et al. Acute and reversible

- cardiomyopathy provoked by stress in women from the united states. *Circulation* 2005 Feb1;111(4):472-9.
8. Desmet WJ, Adriaenssens BF, Dens JA. Apical ballooning of the left ventricle: first series in white patients. *Heart* 2003 Sep;89(9):1027-31.
  9. Gemenetzis G, Gourgiotis S, Aravosita P, et al. Takotsubo cardiomyopathy: a hidden enemy of hypovolemic patients? *Am J Emerg Med* 2013 Jan;31(1): 262.e5-7.
  10. Wittstein IS, Thiemann DR, Lima JA, et al. Neurohumoral features of myocardial stunning due to sudden emotional stress. *N Engl J Med* 2005 Feb;352(6):539-48.
  11. Akashi YJ, Goldstein DS, Barbaro G, et al. Takotsubo Cardiomyopathy: a new form of acute, reversible heart failure. *Circulation* 2008 Dec16;118(25):2754-62.
  12. Kurowski V, Kaiser A, Von Hof K, et al. Apical and mid ventricular transient left ventricular dysfunction syndrome (takotsubo cardiomyopathy): frequency, mechanisms, and prognosis. *Chest* 2007 Sep;132(3):809-16.
  13. Madhavan M, Rihal CS, Lerman A, et al. Acute heart failure syndrome in apical ballooning syndrome (takotsubo/stress cardiomyopathy): clinical correlates and mayo clinic risk score. *J Am Coll Cardiol* 2011 Mar22;57(12):1400-1.
  14. Bhojraj S, Sheth S, Pahlajani D. Postoperative takotsubo cardiomyopathy. *Ann Card Anaesth* 2014 Apr-Jun;17(2):157-60.
  15. Gianni M, Dentali F, Grandi AM, et al. Apical ballooning syndrome or Takotsubo cardiomyopathy: a systematic review. *Eur Heart J* 2006 Jul; 27(13):1523-9.

How to cite this article: Kavitha G, Ramamoorthy R, Shanmugasundaram et. al. Unusual cardiac emergency in a healthy young woman following gynecological surgery: a rare case report. *Int J Health Sci Res.* 2015; 5(6):715-719.

\*\*\*\*\*

#### **International Journal of Health Sciences & Research (IJHSR)**

#### **Publish your work in this journal**

The International Journal of Health Sciences & Research is a multidisciplinary indexed open access double-blind peer-reviewed international journal that publishes original research articles from all areas of health sciences and allied branches. This monthly journal is characterised by rapid publication of reviews, original research and case reports across all the fields of health sciences. The details of journal are available on its official website ([www.ijhsr.org](http://www.ijhsr.org)).

Submit your manuscript by email: [editor.ijhsr@gmail.com](mailto:editor.ijhsr@gmail.com) OR [editor.ijhsr@yahoo.com](mailto:editor.ijhsr@yahoo.com)