

*Case Report*

Tuberculous Tenosynovitis of both Flexor and Extensor Tendons at Wrist with Carpal Involvement

Ravikumar K^{1*}, Nishanth A^{2**}, Nanjundappa HC^{3*}¹Associate Professor, ²Assistant Professor, ³Professor and Chief;

*Department of Orthopaedics M.V.J Medical College and Research Hospital, Bangalore, India.

**Department of Orthopaedics, Kasturba Medical College, Manipal, MAHE University, Manipal, India.

Corresponding Author: Nishanth A

*Received: 05/03/2015**Revised: 25/03/2015**Accepted: 04/04/2015*

ABSTRACT

Introduction: Tuberculous tenosynovitis of hand accounts for only 1% of cases of musculoskeletal tuberculosis, usually involving the flexor tendons of the hand, rarely the extensor tendons. Appearance of melon seed bodies though not pathognomonic of T.B should make the clinician suspect T.B. The diagnosis of T.B tenosynovitis is often missed as it either mimics other clinical conditions or has an atypical presentation.

Case report: We report a case report of a 30 year old male patient who presented with tuberculous tenosynovitis of both flexor and extensor tendons of wrist along with involvement of the carpal bones.

Conclusion: Tuberculous tenosynovitis should not be missed due to its atypical presentations. Clinician should always keep in mind that tuberculosis can emerge in varied forms. An accurate and timely diagnosis, appropriate surgery and anti-tubercular chemotherapy may eradicate these infections and prevent complications.

Keywords: Tuberculous tenosynovitis with carpal bone involvement, Melon seed bodies.

INTRODUCTION

Extrapulmonary tuberculous involvement of the musculoskeletal system is uncommon, accounting for only 10% of tuberculosis cases. [1] Among the musculoskeletal tuberculosis, occurrence of Tuberculous tenosynovitis of the hand is very rare and accounts for about 1% of cases with musculoskeletal TB, usually involving the flexor tendons of the hand. [2,3] Very few cases of tuberculosis of tendon sheath involving both the flexor and extensor tendons have been reported in the literature.

[1] Involvement of carpal bones in

tuberculous tenosynovitis is extremely rare and to our knowledge no such case has been reported. We report a rare case of tuberculous tenosynovitis involving both flexor and extensor tendons of the wrist, along with the involvement of carpal bones.

CASE PRESENTATION

A 30 year old male patient came with complaints of progressive pain and swellings over dorsal and palmar aspect of wrist (Fig-1 and 2) of wrist for the past two months. The pain, a mild, dull aching, started insidiously and gradually worsened

with time. There was no history of fever, loss of weight or appetite, night sweats, malaise or fatigue, trauma, pain in other joints of the body, morning stiffness or continuous use of vibratory tools. On examination there were localized tender swelling of 5x3 cm and 4x2 cm over the ulnar and radial border respectively on the palmar aspect of wrist and another fusiform swelling over ulnar border of hand on dorsal aspect measuring 5x3 cm. Movements of wrist were restricted and painful. Cross fluctuation was present on the volar aspect with a gurgling sound. Laboratory investigations revealed erythrocyte sedimentation rate of 90 mm/hr. Fine needle aspiration cytology showed features suggestive of ganglion. Chest radiograph was normal. Radiograph of wrist showed destruction of the pisiform bone and a lytic lesion in the scaphoid (Fig-3). Ultrasound studies of the wrist showed circumferential thickening of the tendon of flexor carpi ulnaris, flexor pollicis longus, and extensor digiti minimi.

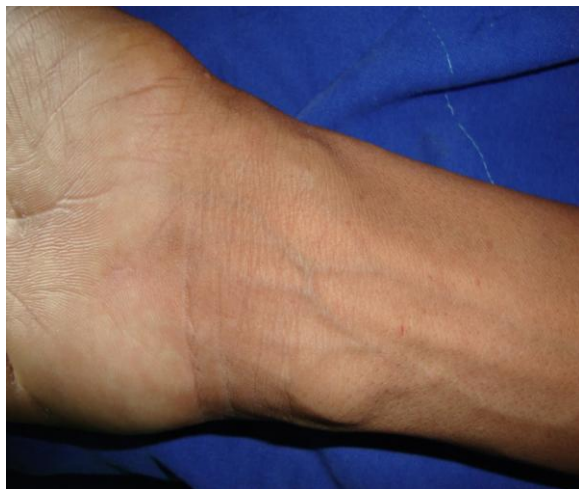

Figure 1: swelling on flexor aspect of the wrist

Exploration & excision biopsy of swelling was planned. Intra-operatively the tendon sheaths of flexor carpi ulnaris, flexor pollicis longus and extensor digiti minimi were found to be hypertrophied along with

presence of large 'melon seed bodies' within the sheath (Fig-4).

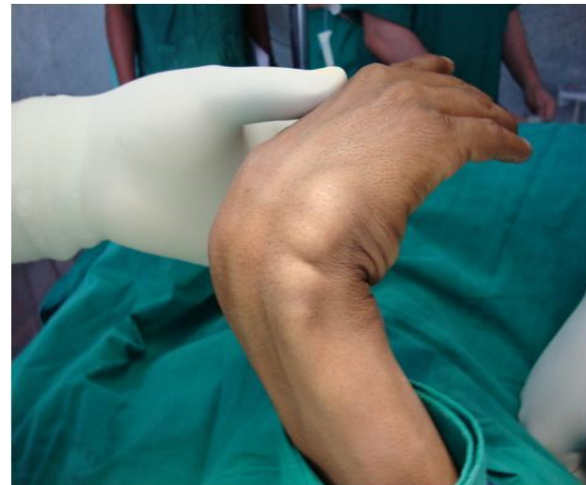

Figure 2: swelling on extensor aspect of the wrist

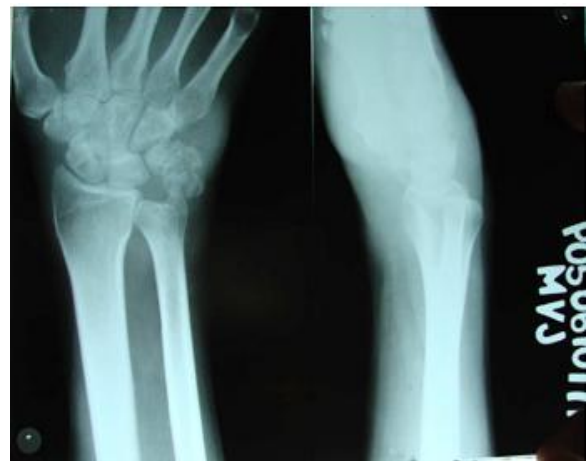

Figure 3: Lysis of the pisiform and scaphoid

The hypertrophied tendon sheaths were excised. During the post operative period patient was immobilized in slab for period of 3 weeks. Histopathological studies were suggestive of chronic granulomatous inflammation with epithelioid cell granuloma (Fig-5). Mycobacterium tuberculosis polymerase chain reaction (PCR) was positive. The Patient was started on antitubercular treatment and Mobilization of the wrist was started after 3 weeks. The antitubercular treatment was continued for period of 1 year. Patient was followed up for a period of one year. There has been no

evidence of recurrence at end of follow up. Patient had palmar flexion of 50 degrees and dorsiflexion of 60 degrees Modified Mayo wrist score was 65.

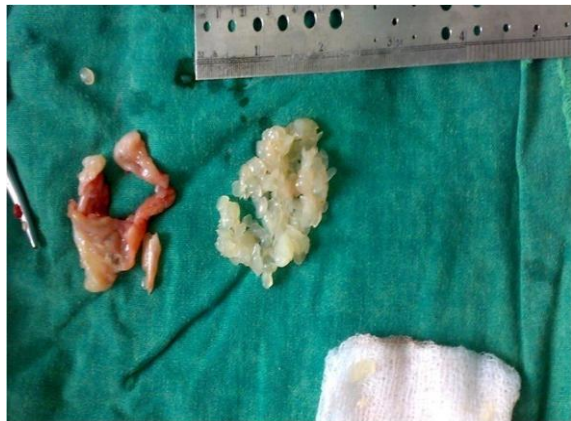

Figure 4: Hypertrophied tendon sheath and melon seed bodies

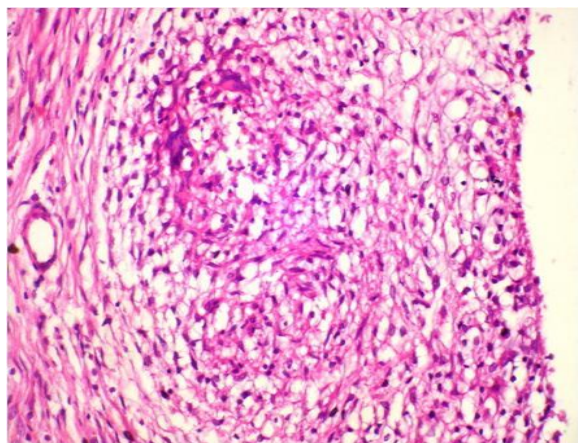


Figure 5: Histopathology of tendon sheath showing epithelioid granuloma.

DISCUSSION

Tuberculosis is still endemic disease in many developing countries. Isolated tuberculous disease of synovial sheath is a rare manifestation of tuberculosis and diagnosis is often missed. [1] Extrapulmonary tuberculous involvement accounts for only 10% of tuberculosis cases. Although the tendon sheaths constitute uncommon target of extra-articular tuberculosis, it remains the leading cause for chronic tenosynovitis. [4] Isolated tuberculous disease of the synovial sheath or

bursa occurs rarely. The mode of spread is by hematogenous route or from neighboring diseased structure.

The disease may present in one of four stages depending on duration of infection and host immunity. In the first stage, a serous exudate alone is present. In the second stage, granulation tissue, tenosynovial proliferation, and rice bodies appear. In the third stage, infection invades the tendon and tendons may be frayed, infiltrated, ruptured. This takes about three years to occur. In the fourth stage, and only very late, the infection spreads to adjacent joints or bones. [5] In our case involvement of pisiform was due spread of infection through sheath of flexor carpi ulnaris which encloses the pisiform bone. The lytic lesion seen in scaphoid was due to the scalloping effect of hypertrophied flexor pollicis longus tendon.

Rice bodies occurring in joints affected by tuberculosis were first described in 1895. [6] The infected synovium gets thickened and with movements & friction the fibrinous exudates get moulded to resemble rice bodies or melon seeds, their appearance is a sign of chronic granulomatous disease, it should be noted that melon seed or rice bodies are not pathognomonic of tuberculosis as they can occur in other conditions like rheumatic diseases including systemic lupus erythematosus, seronegative arthritis and infectious diseases like atypical mycobacterial infections.

When rice or melon seed body formation is found, we should always keep tuberculous tenosynovitis in mind, especially in patients who have a history of tuberculosis exposure, reside in an endemic region, are of advanced age or have immune deficiencies. [7,8]

A radical excision of all involved synovium and removal of necrotic tissue plus all melon-seed/rice bodies followed by

anti-tubercular therapy is curative in biopsy proven cases. [9,10] In advanced stages when arthritis has set in patient may benefit from proximal row carpectomy or wrist arthrodesis depending on carpal involvement apart from anti-tubercular drug therapy.

T.B tenosynovitis has a tendency for local recurrence, with more than 50% of cases recurring within a year of treatment, so close follow-up should be carried out in every case. [11]

CONCLUSION

T.B. tenosynovitis should not be missed due to its atypical presentations. Clinician should always keep in mind that tuberculosis can occur in varied forms. An accurate and timely diagnosis, appropriate surgery and anti-tubercular chemotherapy may eradicate these infections and prevent complications.

Competing Interests: The authors declare that they have no competing interests.

Consent: The patient has given necessary consent for the case report to be published.

Abbreviations

T.B. - tuberculosis

REFERENCES

1. Hitesh Lall, Suman Kumar Nag, Vijay Kumar Jain, Rahul Khare, Deepak Mittal. Tuberculous extensor tenosynovitis of wrist with extensor pollicis longus rupture: a case report.

- Journal of medical case reports 2009; 3: 142.
2. Hodgson AR, Smith TK, Gabriel Sister. Tuberculosis of wrist. With a note on chemotherapy. Clin Orthop 1972; 83: 73-83.
3. Pimm L H, Waugh W. Tuberculous tenosynovitis. J Bone Joint Surg (Br) 1957; 39: 91-101.
4. Tuli SM. Tuberculosis of skeletal system. New Delhi Jaypee 2010.
5. Mukund. R. Patel, G.N. Malaviya, Alan. M. Sugar. Green's operative hand surgery. 5th edition: Elsevier Churchill Livingstone; 2005.
6. Reise H. Die Reiskorpschen in tuberculs erkrankten synovialsacken [in German]. Dtsch Z Chir 1895; 42:1.
7. Min Hsiang, Ko-Chang, Kuo-Feng Huang. Tuberculous tenosynovitis with rice body formation. ANZ journal of surgery 2011; 81: 572.
8. Jaovisidha S, Chen C, Ryu K N, Siriwongpairat P, Pekanbaru P, Sartoris D J, Resnick D. Tuberculous tenosynovitis and bursitis: imaging findings in 21 cases. Radiology 1996; 201: 507-13.
9. Bush DC, Schneider LH. Tuberculosis of the hand and wrist. J Hand Surg [Am] .1984; 9: 391-8.
10. Leung PC. Tuberculosis of the hand. Hand 1978; 10:285-91.
11. Regnard PJ, Barry P, Isselin J. Mycobacterium tenosynovitis in flexor tendons of hands: a report of five cases. J hand surg[Br] 1996.21(3): 351-354.

How to cite this article: Ravikumar K, Nishanth A, Nanjundappa H.C. Tuberculous tenosynovitis of both flexor and extensor tendons at wrist with carpal involvement. Int J Health Sci Res. 2015; 5(5):558-561.
