

*Case Report***Hemiballismus: A Rare Manifestation of Stroke**Shankarappa M Mudgal<sup>1</sup>, Srinivas Kosgi<sup>2</sup>, Vaishali N Hegde<sup>3</sup><sup>1</sup>Associate Professor, Department of Medicine, Raichur Institute of Medical Sciences, Raichur, Karnataka<sup>2</sup>Associate Professor, Department of Psychiatry, Dharwad Institute of Mental and Neurosciences (DIMHANS), Dharwad 580008<sup>3</sup>Plot No 25 "Sumukha" 2<sup>nd</sup> Cross SripadNagar, Dharwad, India.

Corresponding Author: Srinivas Kosgi

*Received: 08/02/2015**Revised: 02/04/2015**Accepted: 11/04/2015***ABSTRACT**

Hemiballismus, severe form of chorea is a very rare movement disorder characterized by wide amplitude, flinging movements, involving the proximal limbs of one side of the body. A lesion in the contralateral sub-thalamic nucleus of the basal ganglia, results in the appearance of flailing, ballistic, undesired movements of the limbs. Hemiballismus as a result of stroke occurs in only about 0.45 cases per hundred thousand stroke victims. Even at such a small rate, stroke is by far the most common cause of hemiballismus. A stroke causes tissue to die due to a lack of oxygen resulting from an impaired blood supply. In the basal ganglia, this can result in the death of tissue that helps to control movement. As a result, the brain is left with damaged tissue that sends damaged signals to the skeletal muscles in the body. We present a case of 48 years old male who presented to the emergency with the history of sudden onset of continuous involuntary flinging movements involving right upper and lower limbs for four hours. Tobacco smoking, Type I obesity, hypertriglyceridemia, low levels of high density lipoprotein and high blood pressure in acute phase were identifiable risk factor for cerebrovascular event in this patient. On medication there has been significant decrease in the involuntary flinging movements within forty eight hours and complete resolution of involuntary movements after five days. Vascular Hemiballismus a rare movement disorder, long-term prognosis of patients with vascular hemiballismus is similar to that of other stroke patients.

**Key words:** hemiballismus, stroke, risk factors.

**INTRODUCTION**

Hemiballismus is a very rare movement disorder, caused in most cases by a decrease in activity of the sub-thalamic nucleus of the basal ganglia, resulting in the appearance of flailing, ballistic, undesired movements observed on the contra lateral side of the body. [1-4] This disorder is extremely rare. Hemiballismus can result

from stroke, non-ketotic hyperglycemia, tuberculomas, complications from HIV infection, demyelinating plaques, amyotrophic lateral sclerosis, neoplasm, vascular malformations, traumatic brain injury etc. [5-8] Just because a patient suffers from one of these disorders does not mean they will also suffer from hemiballismus. We present a case of hemiballismus

presenting as clinical manifestation of stroke with complete recovery with therapy. The purpose of presentation of this case is to highlight the fact that hemiballismus is a rare movement disorder, may be the one of the clinical manifestations of stroke, which could have good prognosis on early detection and pharmacological treatment.

### CASE PRESENTATION

A 48 years old male agriculturist presented to the casualty with the history of sudden onset of continuous involuntary movements involving right upper and lower limbs for four hours.

The patient had a history of smoking tobacco for 10 years amounting. Patient's history for Epilepsy, Hypertension, Diabetes Mellitus, Tuberculosis, alcoholic and use of any medications was ruled out.

On examination patient was conscious and oriented, but anxious while examining. Patient was afebrile; Vitals recorded showed Pulse 80/min, regular, Blood Pressure 150/96 mm of Hg, Respiratory Rate 20/ min.

Body Mass index; 33.5 (Type-I obesity)

Examination for cardiovascular system, respiratory system and per abdomen examination did not reveal any abnormalities.

Nervous system did not reveal any abnormalities in Higher Mental functions and Cranial Nerves examination. Patient was observed to have involuntary movements at the proximal joints of both right upper and lower limbs but more prominent in upper limb. Movements were wild, rapid, flinging movements with wide radius, occurring continuously, sometimes violent. Patient could not sleep due to violent movements. No abnormal movements were detected in left upper and lower limbs.

Laboratory Investigations showed : Hemoglobin 14.5 g%, Total WBC count 10900 cells/cu.mm, Differential count N 74,

L 20, M2, E 4; Blood urea 28 mg/dl, Serum creatinine 1.2 mg/dl, Liver functions tests within normal limits.RBS 80 mg/dl. He had serum Sodium of 139/dmEq/L, Potassium 4.2 mEq/L; serum ASO Titre was < 180 IU, ANA was negative. Lipid profile; Total cholesterol; 159(N= <200), Triglycerides; 219 (N=<150), HDL; 30(>30), LDL; 102(N=<100), VLDL 43 (N=<40)

MRI Imaging (I-IV): T2, FLAIR hyper intensities scattered in left lentiform and caudate nuclei with restricted diffusion suggestive of acute infarct involving left basal ganglia (Lentiform and caudate nuclei). Date: 3August 2014

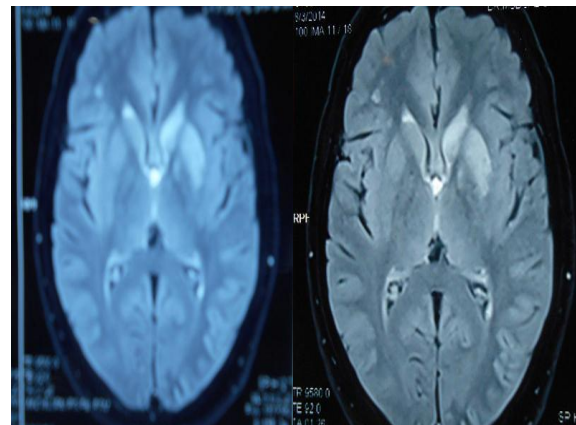


Image-I

Image-II

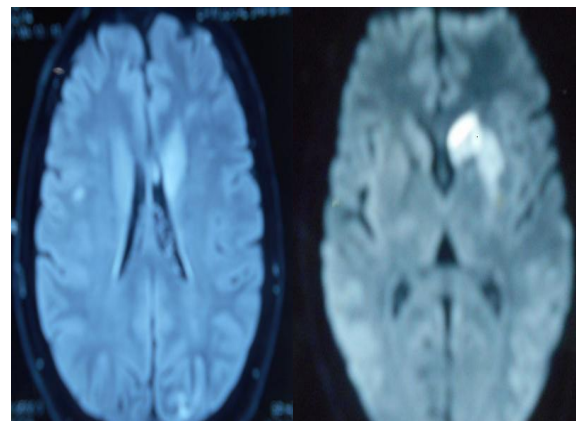


Image- III

Image-IV

Patient was started on injection Haloperidol and Enoxiparin. At the end of 48 hours, involuntary movements significantly diminished. Though blood pressure was

high, no intervention was done, as any attempt to lower the blood pressure during acute phase (i.e. within two weeks) of stroke lowering blood pressure may further compromise ischaemic areas because of loss of cerebral auto regulation. [9] For hypertriglyceridemia patient was started on Atorvastation 20mg.

Patient was discharged with advice for physiotherapy after observation for total seven days and involuntary movements had completely disappeared. No recurrence of neurological symptoms after seven days and monthly follow ups.

## DISCUSSION

Choreic movements can be generalized or focal or involving one side of body. Chorea presents with different patterns, hemi chorea presents as exaggerated balancing of the upper limb with tendency to extend the limb beyond the torso and opening the hand while walking. When associated with sustained muscular contractions, the term choreoathetosis is used. Furthermore, when the choreoathetotic movements are strikingly wide and exaggerated, they are termed ballism. One sided involvement is called as hemiballismus, as reported in this case. [1,10,11]

Hemiballismus is a rare movement disorder being five hundred times rarer than Parkinson's disease. Hemiballismus means 'half ballistic', referring to the violent, flailing movements observed on one side of the body. Meyers was first to define ballism as "Ceaseless, repetitive and complex but constantly varying, large amplitude involuntary movements of the proximal parts of the limbs". Involuntary movements are due to decreased in activity of the sub thalamic nucleus of the basal ganglia. Movements are often violent with wide amplitudes of motion tend to increase during active states and decrease during relaxation

and sleep. Movements result in distress and disability. [5,6,12]

Hemiballismus is a diagnostic challenge because it can be a symptom of multiple diseases as mentioned above. [5-8]

Hemiballismus as a result of stroke (Vascular Hemiballismus) is observed in about 0.45 cases per thousand stroke victims. [2] Even at small rate it is common cause of hemiballismus. Lack of oxygen due to ischemia causes tissue damage in basal ganglia controlling involuntary movements resulting into hemiballistic movements. [5]

Case presented is though rare but cannot be missed as atypical presentation of stroke. Some of the identifiable risk factors (smoking tobacco, Type I obesity, hypertriglyceridemia and low levels of high density lipoprotein and high blood pressure in acute phase) might have favored appearance of cerebrovascular event. Review of literature by Aleksandar Ristic et al on Long-Term Prognosis of Vascular Hemiballismus has found 27 cases of hemiballismus due to first ischemic strokes. [12] Search in data base we came across one case report of not exactly hemiballismus but vascular hemi chorea with similar clinical profile in 58 years old male with untreated high blood pressure, type II obesity, smoking cigarettes and moderate alcohol intake with three days history of hemichoreic involuntary movements MRI imaging showing hyper intensity in the right poster lateral thalamic region suggestive of ischemic cerebrovascular disease and carotid Doppler showing atheromatous plaque in bilateral internal carotid arteries and soft atheroma in common carotid artery. [13]

Risk factors like alcohol and high blood sugar levels were rule-out, because of limitation of investigation resources at the hospital carotid Doppler was not carried out. However anticoagulant therapy using low molecular weight heparin (Enoxiparin) was

given in acute phase and atorvastatin as a prophylactic therapy for dyslipidemia. Patient was discharged on haloperidol which is indicated in controlling hemiballistic movements with advice of life style modification, physiotherapy and monthly follow-up. On regular monthly follow up past six months there is no recurrence of involuntary movements and spontaneously high blood pressure found in acute phase was normalized and maintained within normal limits even on follow-ups not warranting any pharmacological intervention. Long-term prognosis of patients with vascular hemiballismus is similar to that of other stroke patients as reviewed by Aleksandar Ristic et al. [12] Therefore prognosis of this patient is benign, but its long-term prognosis is not specifically determined by the hemiballismus but by the cerebral vascular events and by controlling modifiable risk factors. Review of Parees series, shown complete remission in 73% of patients on follow up for seventeen months. The other series that included follow up reported a complete remission in 96.43% of cases. All patients received only neuroleptic drugs on the acute phase of the disorder. [14-18]

Considering these findings we expect our patient with good prognosis provided control of risk factors. Vascular hemiballismus has a low rate of prevalence, thus case presented add on to the case series and such atypical presentations of stroke should not be ignored

## CONCLUSION

Hemiballismus a rare movement disorder may be one of the clinical manifestations of stroke, which could completely recover on early detection and prompt management.

## REFERENCES

1. Crossman AR.2000. Functional anatomy of movement disorders. *Journal of Anatomy*. 196:519–525.
2. Jankovic J. 2009.Treatment of hyperkinetic movement disorders. *Lancet Neurology*. 8:844–856.
3. Hawley JS, Weiner WJ.2011. Hemiballismus, Current concepts and review. *Parkinsonism Related Disorders*; Sep 17.
4. Gale, J. T, Amirnovin R., Williams Z, Flaherty A. W. et al.2008.Symphony to cacophony: Pathophysiology of the human Basal Ganglia in Parkinson disease. *Neuroscience and Biobehavioral Reviews*.32:378–387. .
5. Das, R.R, Romero J.R, Mandel A.2005. Hemiballismus in a patient with Contra lateral Carotid Artery Occlusion. *Journal of the Neurological Sciences*.238: S392–S392.
6. Postuma R.B, Lang A.E. 2003. Hemiballismus: revisiting a classic disorder". *Lancet Neurology*. 2 (11): 661–668.
7. Kim H.J, Moon W.J, Oh J, et al. 2008. Sub-thalamic lesion on MR imaging in a patient with non-Ketotic hyperglycemia-induced hemiballismus". *American Journal of Neuroradiology*. 29 (3): 526–527.
8. Gamez J, Corbera-Bellalta M, Mila M et al.2008. Chorea-ballismus associated with familial amyotrophic lateral sclerosis. A clinical, genetic, and neuropathological study. *Movement Disorders*.23 (3): 434–438.
9. Maxine A Papadakis, Stephen J McPhee.2013. Cerebral Infarction; Current medical diagnosis and treatment. 52<sup>nd</sup> edn, p. 981-982 Pub: Mc Graw Hill and Co.Lange Medical Publications.
10. Hawley JS, Weiner WJ.2011. Hemiballismus, Current concepts and review. *Parkinsonism Related Disorders*.
11. Gimenez-Munoz A, Alarcia R, Ledesma L et al.2008. Pseudoballismus secondary

- to spinal trauma. *Neurologia*. 23 (5): 315–318.
12. Aleksandar Ristic, Jelena Marinkovic, Natasa Dragasevic et al. 2002. Long-Term Prognosis of Vascular Hemiballismus. *Stroke*. 33:2109-211 accessed website at <http://stroke.ahajournals.org/content/33/8/2109.full> on 08Feb 2015
  13. Barbara M.A, Andres E. B, Jairo R et al. 2014. Vascular hemichorea: case report and review. *Medwave*. 4;14(3).
  14. Parees I, Hernandez-Vara J, Alvarez-Sabin J. et al. 2010. Post-stroke hemichorea: observation-based study of 15 cases. *Rev Neurol*. 51:460-464.
  15. Zijlmans J.C. 2011. Vascular chorea in adults and children. *Handbook of Clinical Neurology*. 100:261-70.
  16. Handley A, Medcalf P, Hellier K et al. Movement disorders after stroke. *Age Ageing*. 2009; 38(3):260-6.
  17. Galiano R, Juni J, Castillo A et al. 2000. Vascular Hemi-chorea. Clinical-radiological correlation. *Rev Neurol*. 30 (5):409-11.
  18. Redondo L, Chacón J, Valencia J et al. 1996. Symptomatic chronic hemi chorea of a vascular lesion in the contra lateral putamen. *Rev Neurology*. 24 (127):303-5.

How to cite this article: Mudgal SM, Kosgi S, Hegde VN. Hemiballismus: a rare manifestation of stroke. *Int J Health Sci Res*. 2015; 5(5):517-521.

\*\*\*\*\*

#### **International Journal of Health Sciences & Research (IJHSR)**

#### **Publish your work in this journal**

The International Journal of Health Sciences & Research is a multidisciplinary indexed open access double-blind peer-reviewed international journal that publishes original research articles from all areas of health sciences and allied branches. This monthly journal is characterised by rapid publication of reviews, original research and case reports across all the fields of health sciences. The details of journal are available on its official website ([www.ijhsr.org](http://www.ijhsr.org)).

Submit your manuscript by email: [editor.ijhsr@gmail.com](mailto:editor.ijhsr@gmail.com) OR [editor.ijhsr@yahoo.com](mailto:editor.ijhsr@yahoo.com)