



Computed Tomography- An Overview in Orofacial Diagnosis

Syed Shahbaz^{1*}, Girish Katti^{2*}, Sreenivasrao Ghali^{1*}, Chandrika Katti^{1**}, Jayesh J. Unnithan^{1***}

¹Sr. Lecturer, ²Principal, HOD & Professor,

*Department of Oral Medicine & Radiology, **Department of Orthodontia,
Al-Badar Dental College and Hospital, Gulbarga.

***Department of Oral Medicine & Radiology, Al-Azhar Dental College and Hospital, Kerala.

Corresponding Author: Syed shahbaz

Received: 11/03/2015

Revised: 15/04/2015

Accepted: 17/04/2015

ABSTRACT

Computed Tomography (CT) scan is a noninvasive imaging modality that uses special X-ray equipment to produce multiple images of inside of the body and a computer to join them together in cross-sectional views of the area being studied. The technologic advances in CT made over the last 25 years have made it possible for CT to be an integral component of the dentist's diagnostic armamentarium. CT can be used to image the extent of pathologic conditions as well as help to unravel complex facial fractures. This paper reviews the applications of CT in dentistry.

Keywords: CT, Orofacial diagnosis, Dentistry.

INTRODUCTION

The use of X-rays is an integral part of clinical dentistry, with some form of radiographic examination is necessary in majority of patients. As a result, radiographs are often referred to as the clinician's main diagnostic aid. [1] Diagnosis of maxillofacial lesions poses a great challenge to the clinicians, due to the complex anatomical pattern and diversity of the lesions of skull and jaw bones. The shape, density and thickness of the patient's tissues, principally the hard tissues, will also affect the radiographic image. Therefore, when viewing two-dimensional radiographic images, the three-dimensional anatomy responsible for the image must be considered. [2]

Two-dimensional X-ray images remained the basis of clinical radiology until

the early 1970s. The invention of computed tomography in 1972 by Sir Godfrey Hounsfield is considered to be the greatest innovation in the field of radiology, which has the unique ability to produce 3-dimensional images. [3,4] Computed tomography (CT) revolutionized the medical imaging modalities. CT is a digital and mathematical imaging technique that creates tomographic sections. Each tomograph shows sharply defined tissues in that section, structures outside the section are blurred. CT is one of the most important methods of radiological diagnosis. It delivers non-superimposed, cross-sectional images of the body, which can show smaller contrast differences than conventional X-ray images. CT enables differentiation and quantification of both hard and soft tissues. [4] This review intends to overview the applications of

Computed Tomography in orofacial diagnosis.

History:

The discovery of X-rays by Sir Wilhelm Conrad Roentgen in 1895 was one of the major milestones in the history of modern medicine, allowing for the first time a non-invasive look inside the patient. The invention of computed tomography is considered to be the greatest innovation in the field of radiology since the discovery of X-rays. This cross-sectional imaging technique provided diagnostic radiology with better insight into the pathogenesis of the body, thereby increasing the chances of recovery. Over the last 30 years, an array of imaging modalities has been developed that has enhanced the already versatile x-ray generating equipment and film used in conventional image production. [1,3,4]

The initial use of computed tomography (CT) for applications in radiological diagnostics during the seventies sparked a revolution in the field of medical engineering. And even throughout the eighties, a CT examination lost little if any of its special and exclusive character. In the meantime, however, times have changed. Today computed tomography represents an accurate and established technology which has advanced to become an indispensable and integral component of routine work in clinics and medical practices. [5]

The development of the first clinical CT scanner began in 1967 with Godfrey N. Hounsfield at the Central Research Laboratories of EMI, Ltd. in England. While investigating pattern recognition techniques, he deduced, independent of Cormack, that x-ray measurements of a body taken from different directions would allow the reconstruction of its internal structure. [3] CT technique was first invented by a British Engineer Sir Godfrey Hounsfield at EMI Central Research Laboratories and independently by a South African born Physicist Dr. Alan. McLeod Cormack of

Tufts University. The first clinically available CT device was installed at London's Atkinson- Morley Hospital in September 1971, after further refinement on the data acquisition and reconstruction techniques. [5]

A mile stone in the history of CT scan systems was the invention of the first whole body CT scanners by Dr. Robert S Ledley of George Town University Medical Centre in 1973. This scanner is the basis of the fundamental design of present day CT scan machines. [6] Hounsfield and Cormack shared the Nobel Prize in Medicine for their inventions in medicine in 1979 and Hounsfield was awarded with a Knighthood for his contributions to the field of medicine and Science. [1,7]

Equipment:

❖ THE X-RAY GANTRY

➤ The x-ray tube.

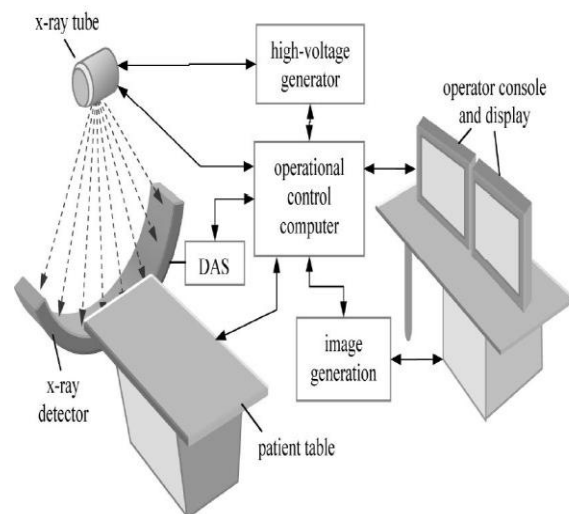
- Stationary anode energized continuously.
- Rotating anode operated in impulse mode.

➤ The radiation detector.

- Scintillation detectors.
- Gas detectors.

➤ The ancillary components.

❖ THE COMPUTER SYSTEM. [1-4]



Schematic diagram of a CT system

Overview of Indications:

- Investigations of intracranial diseases including tumors, hemorrhage and infarcts.
- Investigations of suspected intracranial and spinal cord damage following trauma to the head and neck.
- Assessment of fractures involving:
 - The orbits and nasoethmoidal complex.
 - The cranial base.
 - The odontoid peg.
 - The cervical spine.
- Tumor staging-assessment of site, size and extent of benign and malignant tumors affecting:
 - The maxillary antra.
 - The base of the skull.
 - The pterygoid region.
 - The pharynx.
 - The larynx.
- Investigations of tumors and tumor like discrete swellings intrinsic and extrinsic to the salivary glands.
- Investigation of the temporomandibular joint.
- Preoperative assessment of maxillary alveolar bone height and thickness before inserting implants. ^[1-4,6]

Applications in Maxillofacial Region:

CT has wide applications in dentistry. CT is used to identify and delineate complicated fractures, evaluation of the presence and extent of clinically suspected pathology in head and neck region including infections, tumors, cysts, malignancies & the bony components of the temporomandibular joint (TMJ), also used to assess sites for pre-surgical implant planning and evaluation of the paranasal sinuses. CT is valuable in the radiologic examination of pathology. When the lesion appears to be confined to the jaws, standard intraoral or panoramic radiographs are usually sufficient. When the lesion extends into the

neck or the maxillary or anywhere in the soft tissues of the head, CT imaging is useful in determining the nature and extent of the normal anatomy & pathology. With image reconstruction capabilities that allows the radiologist to provide a three-dimensional image to the surgeon which will help in planning treatment. Additionally, the ability of CT to image the low-contrast structures will help to determine the contents of the pathological spaces before any invasive procedure. ^[5-7]

Osteomyelitis:

Osteomyelitis is an inflammatory condition of bone that involves the medullary cavity and adjacent cortex most commonly involving dental source of infection. It occurs more frequently in mandible than in maxilla. CT reveals the exact location and extent of infection as well as the relationship between soft tissue and bony lesions. The role of CT in diagnosis of maxillofacial infections is to define precise location and extent. The spread of infection can be defined on CT scans according to appearance of fascial spaces. In the evaluation of osteomyelitis, both bone trabecular patterns and extent of soft tissue inflammation should be assessed. ^[8,9]

Pagets Disease:

Systemic disease of bone radiographic appearance of reabsorption of bone secondary to increased osteoblastic activity. As disease evolves, osteoblastic activity becomes predominant; resulting in the formation of thick, spongy (but brittle) matrix. CT shows highly thickened skull base, similar changes also expressed in the calvaria, pelvis and in long bones. Bone window settings with CT scans reveal this bone to be less compact than in normal. ^[6]

Fibrous Dysplasia:

Idiopathic disorder in which medullary bone is replaced by poorly organized and loosely woven bone that is also expanded compared with normal adjacent bone monostatic type (75%)

common, Affects the frontal, ethmoid, sphenoid bones and facial bones. Radiographically ground glass appearance / ivory appearance of affected bone with expansion of middle table blending into inner and outer table is evident. CT appearance consists of exaggerated size and contour of facial, paranasal and orbital structures. The exuberant growth has variegated appearance with soft tissue and fibrous matrix interspersed with bony elements. CT images of fibrous dysplasia on bone windows can display the range of opacification like radiolucency, ground glass and cotton wool. The soft tissue window generally displays mineralized tissue as white. [7]

Central Giant Cell Granuloma:

Non neoplastic process, usually discovered on routine radiographic examination, typically occurring as well defined unilocular to multilocular radiolucency that may be associated with cortical expansion. It is a proliferative process, asymptomatic, idiopathic, histologic lesions of jaws developing from unrecognized or untreated hyperparathyroidism also called as brown's tumor. CT images usually reveal prominent expansion and thinning of cortical plates. [4,8]

CT of the Skull Base

CT examination is required to identify the extent of involvement of base of skull pathology accurately for various degrees of planning of surgery and for therapeutic prognosis. Careful radiologic evaluation of the skull base is essential in patients with malignant tumors of the brain. CT detects soft tissue pathology as well and is the preferred examination, especially for lesions involving the foramina. Depending on the nature of the lesion and its relative orientation to the scan plane, coronal sections may provide more meaningful demonstration of pathology for the surgeon than do the axial ones. Imaging of the brain

base should be performed with and without contrast enhancement. The use of contrast may be quite helpful in defining pathology that often occurs in this region. [8,9]

Meningiomas:

They are usually slow growing tumors with broad dural attachment. These tumors expand intracranially with growth & include those arising from olfactory, parasellar, pterion, clival, sellar, petrous and foramen magnum regions. Imaging of this neoplasm is best performed on CT scan, as tumor often show signal characteristics similar to those of normal brain with MRI imaging. They appear slightly dense prior to contrast infusion with variable amounts of vasogenic edema. Following contrast injection, the lesion almost demonstrates dense homogeneous contrast enhancement. Imaging is better performed in coronal plane than in the axial. [10,11]

CT of Neck:

Expanding interest in neck imaging has been prompted by high resolution CT, which is sensitive and reliable in the evaluation of various disease processes coupled with a detailed physical examination and modern endoscopy, imaging has become indispensable in the characterization and staging of neck pathology. CT provides essential information about the deep extension of clinically detected masses and may delineate additional clinically unsuspected lesions. Contrast enhanced CT is used in defining the extent of deep neck infections, in distinguishing inflammation from abscess. [12]

Advantages:

- Structural relationship of hard and soft tissues can be observed directly. Differences between tissues that differ in physical density by less than 1 percent can be distinguished.
- The ability to rotate images and to add or subtract structural

components permits relationships to be studied.

- Contiguous structures can be separated and normal hidden surfaces examined in detail.
- Accurate linear and volumetric measures can be made.
- Changes in linear or volumetric measures can be determined by sequential scans.
- Eliminates superimposition of images of structures outside the area of interest.
- A single CT imaging procedure consisting of either multiple contiguous or one helical scan can be viewed as images in the axial, coronal or sagittal planes, depending on the diagnostic task.
- Very small amounts, and differences, in X-ray absorption can be detected. This in turn enables:
 - Detailed imaging of intracranial lesions
 - Imaging of hard and soft tissues
 - Excellent differentiation between different types of tissues, both normal and diseased
- Images can be manipulated.
- Axial tomographic sections are obtainable.
- Reconstructed images can be obtained from information obtained in the axial plane.
- Images can be enhanced by the use of IV contrast media (so altering the patient) providing additional information.
- Superimposition of Structures can be avoided.
- Image Acquisition In Cross-Sectional Or Other Planes:
- Soft-Tissue Imaging:
- Adjustment of Radiographic Contrast. [3,4]

Limitations:

- Since the measurements or pixels that form the image represent discrete subdivisions of space, the effect of blurring is much greater than in conventional radiographic systems.
- The resolution of the image is also limited by the size represented by the pixel, which is generally greater than the size of the silver specks that form the conventional radiographs.
- The detail of a computed tomographic image is not as fine as that obtainable on other radiographs.
- Its application in longitudinal monitoring of implant prosthesis is limited and contraindicated because of the image artifact created by metals that would obscure the information.
- Very thin contiguous or overlapping slices may result in a generally high dose investigation
- Metallic objects, such as fillings may produce marked streak or star artefacts across the CT image.
- The equipment is very expensive.
- Inherent risks associated with IV contrast agents. [3,13]

CONCLUSION

Computed tomography revolutionized medical radiology in the early 1970s. Since that time, CT technology has developed dramatically, taking advantage of developments in computer hardware and detector technology. Among the various advanced modalities of CT, Cone Beam Computed Tomography (CBCT) is the most explored and utilized investigative modality in dentistry. The development and rapid commercialization of CBCT technology dedicated to imaging the maxillofacial region will undoubtedly increase dental practitioner access to 3D radiographic assessments in clinical dental practice.

CBCT imaging provides clinicians with sub-millimetre spatial resolution images of high diagnostic quality with relatively short scanning times (10-70 seconds) and a reported radiation dose equivalent to that needed for 4 to 15 panoramic radiographs. To conclude, the benefits of properly performed and clinically justified CT examinations should always outweigh the risks for an individual; unnecessary exposure is associated with unnecessary risk.

REFERENCES

1. Jiang Sieah. Computed tomography: Principles, design, artifacts and recent advances. 2nd ed. Washington: SPIE; 2009
2. White SC, Pharaoh MJ. Oral Radiology: Principles and Interpretation 6th ed. St. Louis: Mobsy; 2004
3. Freny R Karjodkar. Textbook of Dental and maxillofacial radiology. 2nd ed. New Delhi: Jaypee Brothers Medical Publishers; 2009
4. Eric whaites. Essentials of dental radiography and radiology. 3th ed. Edingurgh: Churchil Livingstone Publications; 2002
5. Anil ghom. Essential of dental radiology. 1st ed. New Delhi: Jaypee Brothers Medical Publishers; 2010
6. Brooks S. Computed tomography. Dent Clin North Am 1993;57-89
7. Parks E. Computed tomography applications for dentistry. Dent Clin North Am 2000;43-56
8. Thomas E.U. Diagnostic imaging of maxillofacial infections. Oral Maxillofac Surg Clin N Am 2003;67-75
9. Kuwamata. Three dimensional computed tomography imaging in dentistry. Kuwamata. Dent Clin North Am 2000;23-45
10. James J. Abrahams. Dental CT Imaging: A Look at the Jaw. Radiol 2001; 219:334-45.
11. Garvey CJ. Computed tomography in clinical practice. Br Med J 2002; 49-78.
12. Young-Joo K, Ju-dong. Application of radiographic images in diagnosis and treatment of deep neck infections with necrotizing fasciitis: a case report. Imag Sci Dentis 2011; 41: 189-93.
13. Herbert L.F, Tex H. Drawbacks and Limitations of Computed Tomography. Inst J. 2004; 31(4): 345-8.

How to cite this article: Shahbaz S, Katti G, Ghali S et. al. Computed tomography- an overview in orofacial diagnosis. Int J Health Sci Res. 2015; 5(5):399-404.
