

*Case Report*

Laparoscopic Nephron Sparing Surgery in Solitary Renal Tumors

Vishakha R. Kalikar, Dimple V. Thakkar, Roy V. Patankar, Hemant R. Pathak

The Institute for Special Surgery, Joy Hospital, Chembur, Mumbai

Corresponding Author: Vishakha R. Kalikar

*Received: 08/02/2015**Revised: 23/03/2015**Accepted: 30/03/2015*

ABSTRACT

Nephron Sparing surgery is an established curative treatment in patients with single, small and localized renal tumors. We encountered a patient with a right renal lower pole tumor measuring 4x3 cm with aberrant vascular anatomy. After appropriate investigations it was decided to excise the tumor with a nephron sparing surgery or a laparoscopic partial nephrectomy, the aim being to preserve renal function and greater long term renal sufficiency.

Key words: Solitary renal tumors, nephron sparing, laparoscopic surgery.

INTRODUCTION

Laparoscopic radical nephrectomy in cases of long term follow up has been shown to provide shorter hospital stay and effective cancer control with no significant difference in survival rates with open radical nephrectomy. ⁽¹⁾ Laparoscopic radical nephrectomy has established its role as a standard care of management for renal neoplasms. But since the last few years, partial nephrectomy or nephron sparing surgery has been established as a standard treatment for patients with a solitary kidney and also for patients with a single, small renal tumor even if the kidney function of the contralateral kidney is normal.

CASE REPORT

A 54 year old patient presented with history of one episode of sudden onset

painless hematuria. Serial investigations were done and the hemogram, renal function parameters and electrolytes were within normal range. Urine examination revealed plenty of red blood corpuscles. Ultrasonography of the abdomen revealed a right renal lower pole tumor measuring 4x3 cm. A CT abdomen with a renal angiography was done to delineate the anatomy that revealed a dual right renal arterial supply and a single renal vein draining directly into the IVC from the tumor. The CT showed an enhancing lesion at the right renal lower pole. Distant metastasis was ruled out. In the view of a small sized tumor in an elderly patient, it was decided to do a laparoscopic nephron sparing surgery.

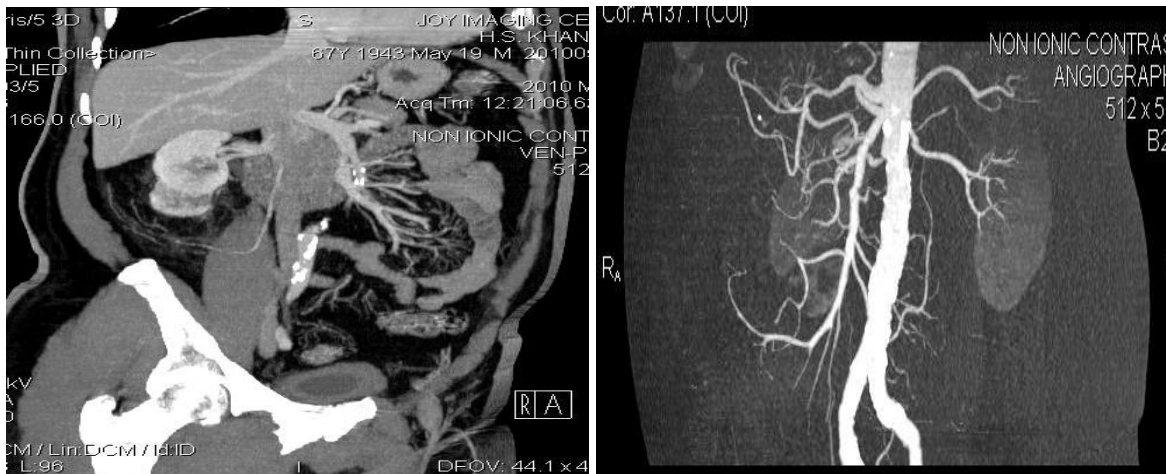


Figure 1: CT angiography showing right lower polar renal tumour.

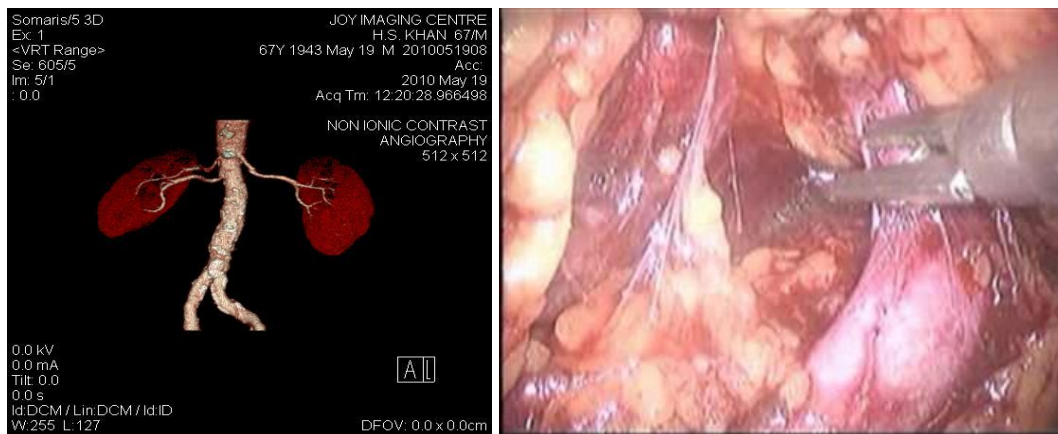


Figure 2: Renal vessels being clipped.

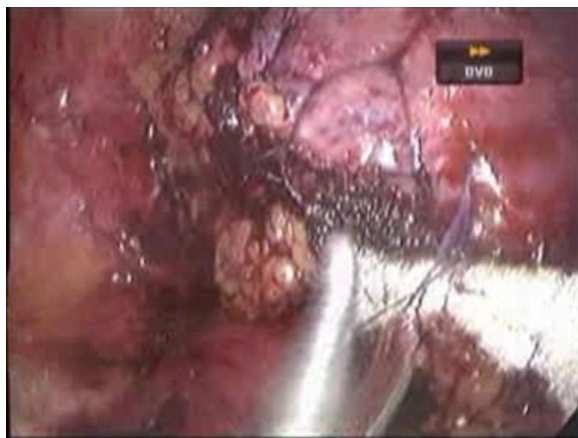

Figure 3: Bolsters being applied.

With the patient in left lateral position, pneumoperitoneum was created. Ports were placed in the right subcostal region in the mid-clavicular, anterior axillary, mid-

axillary line and posterior axillary line. Hepatic flexure of the transverse colon was mobilized medially.

Gerota's fascia was cleared on the healthy kidney one cm on all the sides of the tumor, keeping it intact on the tumor. Renal vessels were dissected and both renal arteries were separately identified and clamped with laparoscopic bull dog vascular clamps and the aberrant renal vein was clipped. The tumor with one cm of renal parenchyma was excised using a combination of bipolar and monopolar energy. Pre-operatively prepared bolsters of surgical (Ethicon) wrapped over gel foam were used to pack the open parenchyma and it was approximated over the bolsters. Clamps of the arteries were released and

hemostasis was achieved, warm ischemia time being 22 minutes. A drain was placed and the tumor was exteriorized in a specimen bag to avoid spillage through a grid iron incision taken by joining the central ports. Specimen was sent for histopathological examination which confirmed it to be an oncocytoma contrary to the enhancing lesion on the CT suspecting a renal cell carcinoma. Post operative recovery of the patient was uneventful with serum creatinine in the normal range and no urinary leak. He was discharged on post operative day 4 and remains normal at 6 months of follow up.

DISCUSSION

Laparoscopic nephron sparing surgery was first reported in 1993 in a patient with a lower pole calyceal diverticulum containing a calculus. Hemostasis was aided through use of a renal tourniquet cinched down around the lower pole of the kidney. Further application of this concept of parenchymal compression was investigated by Cadeddu and colleagues⁽²⁾ with application of cable ties circumferentially to the kidney to aid in hemostasis. Laparoscopic nephron sparing surgery continues to evolve along two therapeutic technical avenues: hilar clamping with ischemia versus no hilar clamping. Development of a laparoscopic Satinsky clamp has achieved en bloc control of the renal hilum to allow cold knife excision of the mass, with laparoscopic repair of the collecting system if needed. In patients such as ours with aberrant arterial supply and abnormal venous drainage a good working knowledge of vascular anatomy is mandatory prior to laparoscopic nephron sparing surgery. Yoshimura and colleagues⁽³⁾ reported use of a microwave tissue coagulator for laparoscopic nephron sparing surgery without hilar clamping. The most bothersome and common intraoperative complication of nephron

sparing surgery is excessive bleeding. To prevent this, attention to detail, Meticulous dissection and ligation of the intraparenchymal vessels is of utmost importance. Urinary leaks are often seen due to injury but most often can be managed conservatively. A small leak is usually common but it doesn't need any further management and stops spontaneously.

Nephron sparing surgery has shown to reduce the risk of progression to chronic renal failure.^(4,5) In a matched comparison study, Lau found out that after ten years, 12.4% patients who had undergone a radical nephrectomy had renal insufficiency (defined by serum creatinine >2mg/dl) compared to just 2.3% of nephron sparing surgery cases. This was more obvious in a rapidly ageing society with people who have a longer longevity. In comparison with a laparoscopic nephron sparing surgery, open nephron sparing surgery has an overall recurrence rate of 0-ten %.^(4,5)

Data from the Mayo Clinic and Memorial Sloan-Kettering Cancer Center, indicate that radical nephrectomy and Nephron sparing surgery provide equally effective curative treatment for such patients who present with a single, small (<4 cm), and clearly localized Renal cell carcinoma.^(6,7,8)

Oncocytomas are small upto 4 cm, benign tumors in origin. They are very rare with an incidence as low as one in 2 lakh individuals. They are solid neoplasms and hence a histopathological examination is necessary to differentiate them from renal cell carcinomas. Microscopically they are eosinophilic, polygonal, granular cytoplasm while in gross inspection on cut section they have a central dense fibrous band with fibrous trabeculae extending out in stellate pattern.

The benefits of laparoscopy for the kidney have clearly been demonstrated in terms of less pain, decreased convalescence time, and decreased narcotic requirements.

(1,9) The benchmarks for long-term success of both laparoscopic approaches for radical nephrectomy and nephron sparing surgery will be defined by oncologic principles. Five year outcome data on actuarial disease-free survival will assess the success of these procedures. Janetschek and colleagues (10) reported 13.3-month follow-up for laparoscopic radical nephrectomy and 22.2-month follow-up for wedge resection without any significant difference in oncological outcome. Cambell et al reviewed their extensive experience of 259 such procedures for renal tumors and concluded that nephron sparing surgery can be safely performed with preservation of renal function in renal tumors.

CONCLUSION

Laparoscopic nephron sparing surgery has a shorter duration of hospital stay and effective cancer control compared to open radical nephrectomy with no significant difference in survival. Laparoscopic nephron sparing surgery for renal tumors has clearly demonstrated low morbidity and efficient cancer control compared to open procedures. The rates for local recurrence and metastasis are low and actuarial survival is high. A preoperative CT with angiography is mandatory for clear visualization of renal anatomy which is important to gain vascular control and minimize warm ischemia time. Laparoscopic nephron sparing surgery is technically feasible and has low morbidity.

REFERENCES

1. Chan DY, Cadeddu JA, Jarrett TW, et al. Laparoscopic radical nephrectomy: cancer control for renal cell carcinoma. *J Urol*. 2001;166:2095–2210.
2. Cadeddu JA, Corwin TS, Traxer O, et al. Hemostatic laparoscopic partial nephrectomy: cable-tie compression. *Urology*. 2001;57:562–566
3. Yoshimura K, Okubo K, Ichioka K, et al. Laparoscopic partial nephrectomy with a microwave tissue coagulator for small renal tumor. *J Urol*. 2001;165:1893–1896
4. Uzzo RG, Novick AC. Nephron sparing surgery for renal tumors: indications, techniques and outcomes. *J Urol*. 2001;166:6–18
5. Montie JE, Novick AC. Partial nephrectomy for renal cell carcinoma. *J Urol*. 1992;148:1835
6. Hafez KS, Novick AC, Butler BP. Management of small solitary unilateral renal cell carcinomas: impact of central versus peripheral tumor location. *J Urol* 1998;159:1156-60
7. Lerner SE, Hawkins CA, Blue ML, et al. Disease outcome in patients with low stage renal cell carcinoma treated with nephron sparing or radical surgery. *J Urol* 2002;167:884-9.
8. Lee CT, Katz J, Shi W, Thaler HT, Reuter VE, Russo P. Surgical management of renal tumors 4 cm or less in a contemporary cohort. *J Urol* 2000; 163:730-6.
9. Clayman RV, Kavoussi LR, Soper JN. Laparoscopic nephrectomy. *N Engl J Med*. 1991;324:1370.
10. Janetschek G, Jeschke K, Peschel R. Laparoscopic surgery for stage 1 renal cell carcinoma: radical nephrectomy and wedge resection. *Eur Urol*. 2000;38:131.

How to cite this article: Kalikar VR, Thakkar DV, Patankar RV et. al. Laparoscopic nephron sparing surgery in solitary renal tumors. *Int J Health Sci Res*. 2015; 5(4):345-348.
