



Short Communication

## Osteometric Dimension of Incus in Gujarati Population

Jayesh Rathava<sup>1</sup>, Pratik Trivedi<sup>2</sup>, Urvik Kukadiya<sup>1</sup>

<sup>1</sup>Tutor, Department of Anatomy, Shree M P Shah Medical College, Jamnagar, Gujarat, India.

<sup>2</sup>Tutor, Department of Anatomy, GMERS, Junagadh, Gujarat, India.

Corresponding Author: Jayesh Rathava

Received: 27/02/2015

Revised: 24/03/2015

Accepted: 27/03/2015

### ABSTRACT

**Background:** This study was conducted to find out Osteometric dimension of incus in Gujarati Population which is very helpful in Ossicular replacement in ossicular chain pathology.

**Aim:** To study the normal morphometric value of incus.

**Materials and methods:** Present study was carried out on 60 incus bone in anatomy department at 3 medical colleges namely Govt. Medical College, Bhavnagar, Shri M.P. Shah Govt. Medical College, Jamnagar and P.D.U Medical College, Rajkot. The present study was conducted after approval from the institutional ethics committee.

**Results:**

The mean total length of incus was  $6.43 \pm 0.29$  mm, ranging from a minimum of 5.7 mm to maximum of 7.06 mm.

The total mean width of incus was  $4.99 \pm 0.32$  mm, ranging from a minimum of 4.01 mm to maximum of 5.64 mm.

The mean of Maximal distance between the tips of the processes of incus was  $5.82 \pm 0.44$  mm, ranging from a minimum of 5.00 mm to maximum of 6.75 mm.

**Conclusion:** Incus is most stable bone among ossicles. All above osteometric dimension of incus is useful for incus prosthesis in Ossicular replacement surgery.

**Key words:** Osteometric dimension, Ossicles, Incus, Gujarati population.

### INTRODUCTION

The malleus found to be the most resistant ossicle to erosion in chronic suppurative otitis media whereas incus was found to be the most susceptible. The incidence of ossicular erosion was found to be much greater in unsafe CSOM than in safe CSOM. [1]

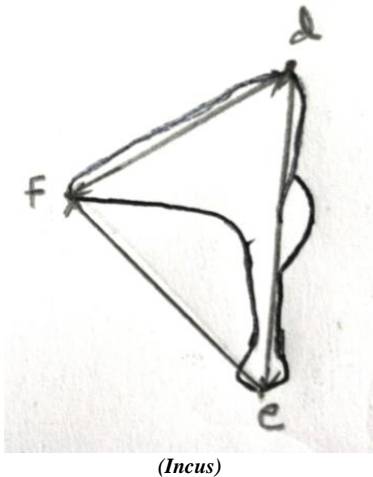
An ideal graft is that which is biocompatible, inexpensive, easy to sterilize,

readily available, technically easy to use, and gives good hearing results. [2]

Total ossiculoplasty is a reliable technique in children. Long-term hearing outcomes are stable and satisfactory, but luxation can occur at any time. Preoperative ABG and footplate status are negative predictive factors of auditory results. [3]

## MATERIALS AND METHODS

Study the morphometric analysis of 60 Incus in people of Gujarat constituted the study material. The ear ossicles were collected from Anatomy department of three medical colleges namely Govt. Medical College, Bhavnagar, Shri M.P. Shah Govt. Medical College, Jamnagar and P.D.U Medical College, Rajkot. The present study was conducted after approval from the institutional ethics committee.



**Total length of incus (mm):** (d-e) maximal distance between the superior edge of the body and the end of long process. [4]

**Total width of incus (mm):** (d-f) maximal distance between the superior edge of the body and the end of short process. [4]

**Maximal distance between the tips of the short process and long process of incus (mm):** (e-f). [4]

## RESULTS

The table 1: showing that the mean value of the length of incus was 6.43 mm. The maximum value of length of incus was 7.06 mm. The minimum value of the length of incus was 5.70 mm and standard deviation was 0.29 mm. The mean value of width of incus was 4.99 mm. The maximum value of width of incus was 5.64 mm. The

minimum value of width of incus was 4.01 mm and standard deviation was 0.32 mm. The mean value of the distance between the processes was 5.82 mm. The maximum value of the distance between the processes was 6.75 mm. The minimum value of the distance between the processes was 5.00 mm and standard deviation was 0.44 mm.

**Table 1: Showing mean, maximum, minimum and standard deviation values of the length of incus, width of incus and maximum distance between two processes.**

Statistics	Mean (mm)	Max (mm)	Min (mm)	SD (mm)
Length of Incus	6.43	7.06	5.70	0.29
Width of incus	4.99	5.64	4.01	0.32
Maximum distance b/w two processes of incus	5.82	6.75	5.00	0.44

## DISCUSSION

- **Total Length of Incus (mm):**

In Present study (2013), the mean total length of incus (6.43 mm) was almost similar with reported by Arsenburg et al (1981) [5] (6.4 mm) and Unur E et al (2002) [4] (6.47 mm).

In Present study (2013), the total length of incus was higher than reported by Harneja NK and Chaturvedi RP (1973) [6] (3.14 mm).

- **Total width of Incus (mm):**

In Present study (2013), the total width of incus (4.99 mm) was higher than reported by Harneja NK and Chaturvedi RP (1973) [6] (1.82 mm) and Unur E et al (2002) [4] (4.88 mm).

- **Maximal Distance Between The Tips of The Processes of Incus (mm):**

In Present study (2013), the mean of Maximal distance between the tips of the processes of incus (5.82 mm) was lower than reported by Unur E et al (2002) [4] (6.12mm).

**Total Length of Incus (mm):**

Researcher	Study population	Sample size	Min (mm)	Max (mm)	Mean (mm)	SD (mm)
Harneja NK and Chaturvedi RP (1973) <sup>[6]</sup>	Rajasthan	30	2.80	3.75	3.14	0.19
Arsenburg et al (1981) <sup>[5]</sup>	India	22	6.04	6.93	6.40	0.24
Unur E et al (2002) <sup>[4]</sup>	Turkey	40	-	-	6.47	0.55
Present study (2013)	Gujarat	60	5.7	7.06	6.43	0.29

**Total Width of Incus (mm):**

Researcher	Study population	Sample size	Min (mm)	Max (mm)	Mean (mm)	SD (mm)
Harneja NK and Chaturvedi RP (1973) <sup>[6]</sup>	Rajasthan	50	1.60	2.25	1.82	0.14
Unur E et al (2002) <sup>[4]</sup>	Turkey	40	-	-	4.88	0.47
Present study (2013)	Gujarat	60	4.01	5.64	4.99	0.32

**Maximal Distance between the Tips of the Processes of Incus (mm):**

Researcher	Study population	Sample size	Min (mm)	Max (mm)	Mean (mm)	SD (mm)
Unur E et al (2002) <sup>[4]</sup>	Turkey	40	-	-	6.12	0.43
Present study (2013)	Gujarat	60	5.00	6.75	5.82	0.44

**CONCLUSION**

Incus is most stable bone among ossicles. All above osteometric dimension of incus is useful for incus prosthesis in Ossicular replacement surgery.

**REFERENCES**

1. Varshney S , Nangia A, Bist S., Singh R.K., Gupta N., Bhagat S.; Ossicular Chain Status in Chronic Suppurative Otitis Media in Adults; Indian J Otolaryngol Head Neck Surg (October–December 2010);volume 62;issue 4;page no.421–426;
2. Kandakure V., Thakur G, Thote A, Kausar A, Gilada A, Survase R; Behaviour of Ossicular Grafts in Otitis Media; *IOSR Journal of Dental and Medical Sciences (IOSRJDMS)*; (Sep-Oct. 2012); Volume 1; Issue 3; Page no. 32-36.
3. Nevoux J, Moya-Plana A, Pierre Chauvin P, Denoyelle F, Garabedian E; Total Ossiculoplasty in Children Predictive Factors and Long-term Follow-up; Arch Otolaryngol Head Neck Surg. 2011; volume137, issue 12; page no.1240-1246.
4. Unur E, Ulger H, and Ekinici N; Morphometrical and Morphological Variation of Middle Ear Ossicles in the Newborn; Erciyes Medical Journal; 2002; volume 24; Issue 2; page no.57-63.
5. Arsensburg B, Harrell M, Nathan H; The Human Middle Ear Ossicles: Morphometry and Taxonomic Implications; J Hum Evol; 1981; Volume 10; Page No.199-205.
6. Harneja NK, Chaturvedi RP; A Study of the Human Ear Ossicles. Indian J Otol.; 1973; Volume 25; Page No. 154-160.

How to cite this article: Rathava J, Trivedi P, Kukadiya U. Osteometric dimension of incus in Gujarati population. Int J Health Sci Res. 2015; 5(4):292-294.

\*\*\*\*\*