



Original Research Article

## Outcome of Surgical Correction of Hallux Valgus Deformity by Chevron-Akin Double Osteotomy- A Prospective Study

Ashok Priyadarshi<sup>1\*</sup>, Ranajit Panigrahi<sup>2\*</sup>, Amita Kumari Mahapatra<sup>3\*\*</sup>, Nishit Palo<sup>1\*</sup>, Hatia Marandi<sup>2\*</sup>,  
Manas Ranjan Biswal<sup>4\*</sup>

<sup>1</sup>Resident, <sup>2</sup>Fellow Arthroscopy, Seoul, South Korea. <sup>2</sup>Associate Professor, <sup>3</sup>Assistant Professor, <sup>4</sup>Professor,  
<sup>\*</sup>Department of Orthopaedics, <sup>\*\*</sup>Department of Physiology, Hi-Tech Medical College, Odisha.  
<sup>2</sup>Visiting Consultant & Senior Arthroscopic Surgeon at Sparsh Hospitals & Critical Care Pvt Ltd.

Corresponding Author: Ranajit Panigrahi

Received: 25/02/2015

Revised: 17/03/2015

Accepted: 17/03/2015

### ABSTRACT

**Introduction:** Hallux valgus is one of the commonest forefoot deformities; with an estimated prevalence of 23% to 35%. Despite the large number of correction procedures, controversy still remains regarding the best procedure for severe deformity correction.

**Purpose:** The purpose of this study was to analyze the clinical and radiological outcomes of Chevron-Akin double osteotomy in moderate-to-severe hallux valgus deformity. We evaluated prospectively 16 patients during August'12 to December'14 who underwent Chevron-Akin double osteotomy for correction of moderate to severe hallux valgus deformity. Preoperative and postoperative AOFAS scores, patient satisfaction, and radiographic data (HVA, IMA and DMAA) were used to evaluate the effectiveness of the procedure. Complications were recorded. Mean follow up was of 22 months (range 18–27 months).

**Results:** The average preoperative AOFAS score of 52 (range, 34–76) improved ( $p < 0.01$ ) to 90.3 (range, 58–100), the averaged HVA of  $37^{\circ}$  (range,  $18^{\circ}$ – $55^{\circ}$ ) improved ( $p < 0.01$ ) to  $18^{\circ}$  (range,  $4^{\circ}$ – $33^{\circ}$ ), and the averaged IMA of  $17^{\circ}$  (range,  $10^{\circ}$ – $24^{\circ}$ ) improved ( $p < 0.01$ ) to  $9^{\circ}$  (range,  $0^{\circ}$ – $15^{\circ}$ ). A mean of  $19^{\circ}$  of HVA and  $8^{\circ}$  of IMA correction was obtained at the final follow ups, DMAA improved by  $4^{\circ}$ .

**Conclusion:** Combined Chevron-Akin osteotomy compares favorably with the other metatarsal and phalangeal osteotomy in correction of moderate to severe hallux valgus deformity with no compromise of joint motion with a good satisfaction rate on radiographic correction and clinical outcomes.

**Key words:** hallux valgus, Chevron-Akin osteotomy, pain, deformity

### INTRODUCTION

Hallux valgus is one of the commonest forefoot deformities, with an estimated prevalence of 23% to 35%. [1] Hallux valgus (lateral deviation of the great toe) is not a single disorder but a complex deformity of the first ray that frequently is

accompanied by deformity and symptoms in the lesser toes. It consists of lateral subluxation of the first metatarsophalangeal joint, metatarsus primus varus, and lateral deviation of the sesamoids. [2]

The reasons for hallux valgus in an individual case are hard to define. The

deformity can often be attributed to ill-fitting shoes and sometimes there is a familial disposition. Heredity is likely to be a major predisposing factor, with up to 68% of patients showing a familial tendency. [3] Women are much more commonly affected than men, because they frequently wear narrow constricting high-heeled shoes and often have more flexible soft tissues. [4-6] Hyper mobility of the first tarsometatarsal joint is thought by some [7,8] to be a causative component in some cases of hallux valgus. The role of pes planus is complex, though it is unlikely that it is an important initiating factor in hallux valgus but in the presence of pes planus the progression of hallux valgus is more rapid. [9]

Non-operative treatment may alleviate symptoms but does not correct the deformity of the big toe. Surgery is indicated if the pain persists. Surgical treatment of this deformity involves correction of alignment with an appropriately chosen metatarsal osteotomy and other soft tissue releases. [10] Despite the large number of techniques described for hallux valgus correction, controversy still remains regarding the best procedure to use, especially for severe deformities.

Distal chevron osteotomy is a widely accepted method for the correction of mild and moderate hallux valgus deformity. [11,12] Akin-type phalangeal osteotomy is mostly used as an adjunctive procedure that can complement toe correction provided by a closing base wedge osteotomy, distal metaphyseal osteotomy, or McBride-type bunionectomy [13-15] and is rarely indicated as primary and sole procedure for correction of hallux valgus deformity.

In this study we analyzed the clinical and radiological results of combined Chevron-Akin double osteotomy for correction of moderate to severe hallux valgus deformity with an average 22 months follow up.

## MATERIALS & METHODS

This was a prospective study evaluating the outcome of Chevron-Akin double osteotomy for correction moderate to severe hallux valgus deformity with an average 22 months follow up. Once the present research project was approved by the ethical committee of our institution, 16 consecutive patients from August'12 to December'14, with moderate to severe hallux valgus deformity underwent distal Chevron-Akin double osteotomy at our hospital after they declared their consent to participate in the study.

**Inclusion Criteria:** Male/Female patients, Age 30-60 years, with a painful bunion and an adequate range of movement with moderate to severe hallux valgus deformity. Deformity was considered moderate when the HVA (hallux valgus angle) was  $20^{\circ}$  to  $40^{\circ}$  and IMA (intermetatarsal angle) was  $14^{\circ}$  to  $20^{\circ}$  and severe when HVA  $> 40^{\circ}$  and IMA  $> 20^{\circ}$ .

**Exclusion criteria:** Patients with rheumatoid arthritis failed previous hallux valgus surgery and symptomatic and/or radiological osteoarthritis of the first metatarsophalangeal joint, severe first tarsometatarsal instability, severe osteoporosis, and open epiphyseal plates.

**Methodology:** The main operative indication for the surgery was pain and deformity in the forefoot, especially near the first metatarsophalangeal joint, refractory to non-operative management. Non-operative management included accommodating shoes or orthotic devices, non-steroidal anti-inflammatory medications or a combination of these methods.

**Clinical assessment:** Patient's demographic data was recorded. Preoperatively, all patients underwent an assessment of pain level and functional limitation using AOFAS hallux score questionnaire. The AOFAS hallux score questionnaire was again completed at the final follow up. This

scoring system consisted of a 100-point scale divided into three main categories: pain, function, and alignment. The pain and function portions were answered by the patient. The physical examination items were completed by the primary surgeon. Higher scores indicated better function. Additionally, the patients were asked at final follow up if they were satisfied with the overall results of the surgery, satisfied with reservations, or unsatisfied,

**Radiographic assessment:** was performed according to standardized procedures using weight-bearing dorsoplantar and lateral radiographs preoperatively and postoperatively at 2, 6, and 12 weeks and reviewed by one individual. The HVA and the IMA were measured.

The HVA was measured using the intersection of the bisection of the first metatarsal and proximal phalanx. Normal values for the HVA range from  $10^{\circ}$  to  $15^{\circ}$ . [16] Patients having HVA  $>20^{\circ}$  were included in the study.

The IMA was measured as the angle formed by the intersection of the bisection of the first and second metatarsals. Normal values for the IMA range from  $7^{\circ}$  to  $90^{\circ}$ . [16] Patients with IMA  $>14^{\circ}$  were included in the study. The distal metatarsal articular angle

(DMAA) (normal  $< 10^{\circ}$ ) is the angle between the articular surface of the head and shaft of the first metatarsal.

**Surgical technique:** All osteotomies were performed by the same surgeon. Surgical procedure included following steps:

Medial eminence removal-a midside incision was made over the first MTP joint from midshaft of the proximal phalanx to approximately midshaft of the metatarsal. An inverted L or lenticular medial capsulotomy was used to expose the medial eminence. The medial eminence was excised with a power saw. V-shaped intracapsular osteotomy was performed through the first metatarsal head, taking care to ensure that each cut was made precisely to give stability. A Kirschner wire was drilled medial to lateral through the first metatarsal head, aiming at the head of the fourth metatarsal and inclined  $20^{\circ}$  plantarly. Two cuts were made with an oscillating power saw, such that they formed an angle of  $60^{\circ}$  proximal to the drill hole. After the capital fragment was freely mobile, it is displaced laterally by approximately 3 mm (fig.1). When the joint surfaces were in correct alignment and the metatarsal head was in place, the capital fragment was impacted firmly onto the metatarsal shaft.

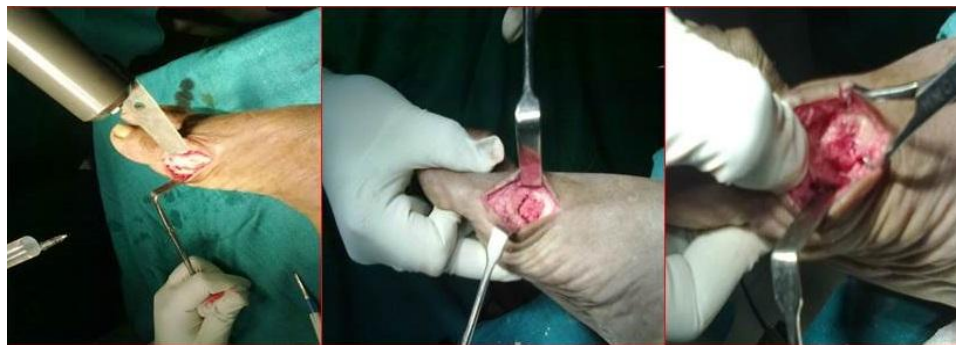


Figure 1: Surgical Technique: Medial eminence removal,, Distal Chevron Osteotomy with Lateral displacement of MT Head.

The resulting projection of the first metatarsal was removed.

Proximal phalanx was exposed subperiosteally, and a phalangeal closing wedge osteotomy was performed. The cut

was made away from the articular surface so as to parallel the concavity of the base of the proximal phalanx, and a 1-mm wedge of bone was removed. Vicryl suture was placed from the periosteum on the distal side of the cut through the proximal undisturbed capsular tissues to maintain the osteotomy

closure. Kirschner wire fixation done. Medial capsulorrhaphy- the medial capsule was closed with absorbable sutures to hold the toe in the corrected position. The skin was closed with interrupted sutures, and a bulky compressive dressing was applied (fig.2)

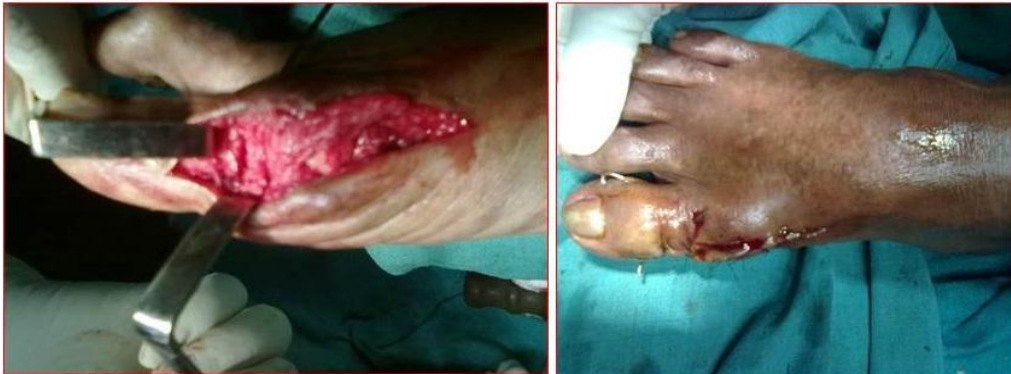

Figure 2: Surgical Technique: Wedge of bone removal with Clinical photograph after Surgery

The postoperative protocol allowed immediate weight bearing on the heel or lateral side of the foot in a postoperative shoe with crutches for balance during the first 2 weeks. Because of the frequent tendency towards swelling, patients were advised to keep the affected foot raised for much of the time during the first 2 weeks. Once wounds were healed and sutures removed, active and assisted motion of the metatarsophalangeal joint was of the great toe was encouraged. The pin was removed, and an elastic bandage was used to hold the corrected toe position. The patients were wearing sneakers at 4 to 6 weeks, depending on the amount of swelling. At 4 weeks, the wearing of shoes was gradually resumed. Patients usually started walk normally after 8 to 12 weeks.

**Statistical evaluation:** The preoperative data was compared with the results at follow up using the paired Student's t test at the 95% significance level ( $p=0.05$ ) and p value obtained.

## RESULTS

Of the 16 patients 6 were men and 10 women with a mean age of 48 years (range 30-60 years). Minimum follow up was of 18 months (mean 22 months; range 18–27 months). Demographic data of patients are represented in table 1.

Table 1. Normal distribution of data for the patients (n=16)

Variables	
Male	10
Female	6
Mean Age(years)	48
Mean AOFAS score(pre-op, post-op)	52,90.3 ( $p<0.01$ )

The average preoperative AOFAS score of 52 (range,34-76) improved ( $p<0.01$ ) to 90.3 (range, 58-100), indicating an acceptable functional restoration of the forefoot, reduction of pain, ability to wear shoes and correction. Patients returned to wearing dress shoes in 3-4 months. Seventy-nine percent of patients were satisfied, 15% were satisfied with reservations, and 6% were not satisfied with their results. 90% would recommend the procedure to a friend.

The average preoperative HVA of  $37^{\circ}$  (range  $18^{\circ}$ – $55^{\circ}$ ) improved ( $p<0.01$ ) to  $18^{\circ}$

(range 4–33<sup>0</sup>), and the average preoperative IMA of 17<sup>0</sup> (range 10–24<sup>0</sup>) improved (p<0.01) to 9<sup>0</sup> (range, 0–15<sup>0</sup>). A total 19<sup>0</sup> of HVA and 8<sup>0</sup> IMA corrections was obtained. Not much difference was seen in DMAA, it

was an average 15<sup>0</sup> pre-operatively and 11<sup>0</sup> post-operatively (p<0.05). Pre-operative and post-operative HVA, IMA and DMAA are represented in table 2.

**Table 2. Radiographic results (data are mean)**

Measurements	Pre-operative	At Final Follow-up	Mean correction	p-value
Hallux valgus angle (degrees)	37	18	19	<0.01
Inter-metatarsal angle (degrees)	17	9	8	<0.01
Distal metatarsal articular angle (degrees)	15	11	4	<0.05

Immediate post-operative complication was seen in one case with wound infection that resolved with oral antibiotics. Good postoperative range of movement of great toe was obtained subjectively and objectively. Malunion after pin removal was seen in one case. Recurrence was seen in none. In no case there was shortening of the first metatarsal. Degenerative changes of first MTP joint was seen in two cases.

## DISCUSSION

Painful hallux valgus is a common clinical problem especially in women. Mann, Rudicel and Graves [17] have shown that patients present with restriction in the wearing of their shoes in 80%, pain over the medial eminence (bunion) in 70%, cosmetic concerns in 60% and pain underneath the second metatarsal head in 40%. Deformities of the lesser toes such as corns and calluses are often a source of symptoms and are largely due to insufficiency of the first ray and overcrowding. Synovitis of the second metatarsophalangeal joint with pain and swelling is particularly painful.

The pathogenesis of hallux valgus has been well described by Stephens. [18] Its pathogenesis is complex. It is generally accepted that an imbalance of the extrinsic and intrinsic foot muscles and the ligamentous structures is involved. It causes

symptoms on the medial edge of the foot, the sole, and the small toes in three particular ways. [1] First and foremost is pain in the bunion, the pressure-sensitive prominence on the medial side of the head of the first metatarsal. It hurts to wear a shoe. Furthermore, the valgus deviation of the great toe often results in a lack of space for the other toes causing them to be displaced, usually upwards, leading to pressure against the shoe termed hammer toe or claw toe. Finally, normal function of the forefoot relies heavily on the great toe pressing down on the ground during gait. Since the valgus deformity stops this happening to a sufficient degree, metatarsal heads II–V are overloaded. The resulting pain is referred to as transfer metatarsalgia.

In our study we found the preoperative AOFAS score improved postoperatively by 38 points (52 to 90.3), with 94% of patients satisfied and 90% of patients stating they would recommend the procedure to a friend. Other studies have showed similar improvements in AOFAS scores: Bai L Bet al [19] 54.7 to 92.9, Choi YR et al [20] 49 to 92, and Philipp L et al [21] by 21.5 points.

Zettl R et al [22] in their study of moderate to severe hallux valgus deformity correction with proximal crescentic osteotomy and distal soft-tissue release found a better correction with HV angle

improved from averaged  $41.1^{\circ}$  to  $14.6^{\circ}$  and IM angle from  $17.8^{\circ}$  to  $7.8^{\circ}$ , but it was associated with complications like hallux varus and hardware failure.

In our study we obtained a mean correction of  $19^{\circ}$  ( $37^{\circ}$  to  $18^{\circ}$ ) in HVA and of  $8^{\circ}$  ( $17^{\circ}$  to  $9^{\circ}$ ) in IMA as compared  $14.3^{\circ}$  and  $4.1^{\circ}$  obtained by Mitchell LA et al [23] with Chevron-Akin double osteotomy. If we review previous literatures on Chevron osteotomy combined with other procedures different studies have varying degree of deformity correction. Bai LB et al, [19] combined distal chevron osteotomy with distal soft tissue procedure for moderate to severe hallux valgus deformity and found an improvement in HVA from  $36.2^{\circ}$  to  $12.4^{\circ}$  in HVA and from  $17.1^{\circ}$  to  $7.3^{\circ}$  in IMA. Philipp L et al [21] compared Chevron osteotomy with Chevron-Akin double osteotomy and obtained a mean improvement in HVA of  $10.6^{\circ}$  in the Chevron group and of  $17.5^{\circ}$  the Chevron-Akin group. These findings suggests that Chevron-Akin double osteotomy is an effective and practicable procedure and compares favorably with isolated Chevron osteotomy and other combined procedures in correction of moderate to severe hallux valgus deformity.

A concern with the Chevron and other distal osteotomies is the development of avascular necrosis of the first metatarsal head with a reported incidence of between 0% and 20% [24-27] but in our study there was no incidence of avascular necrosis. There was no significant shortening of the first metatarsal with the double osteotomy. Degenerative changes of the first metatarsophalangeal joint were seen in two cases with intra-articular extension of the Akin osteotomy. In one case, malunion occurred after pin removal due to shifting of the Chevron osteotomy. In no case recurrence was seen.

Our results indicate that distal Chevron metatarsal osteotomy and Akin

phalangeal osteotomy through one medial incision provides a safe, effective and reliable means of correcting moderate to severe hallux valgus deformity, with high levels of patient satisfaction and low incidence of complications. The advantages include that the procedure is simple, early ambulation is possible, and there is no dorsal scarring.

The clinical outcome of the present study seems to be good in most cases, but large-scale randomized trials are still needed to verify the efficacy of the Chevron-Akin double osteotomy in correction moderate to severe hallux valgus deformity.

## CONCLUSION

Surgery for hallux valgus, while technically demanding, has a high rate of success in appropriately selected patients. The Chevron-Akin double osteotomy is a safe, effective technique for moderate to severe hallux valgus deformities providing tremendous inherent stability, thus retaining the benefit of early mobilization with no compromise of joint motion, with a superior deformity correction and a high patient satisfaction rate. Based on radiographic correction and clinical outcomes, this procedure may be indicated for the treatment of moderate to severe hallux valgus deformities.

**Funding statement:** This research received no specific grant from any funding agency in the public, commercial or not-for-profit sectors.

**Conflict of Interest:** The authors have no financial or other conflict of interest to declare and no financial or other relationships leading to conflict of interest.

## REFERENCES

1. Wülker N, Mittag F: The treatment of hallux valgus. Dtsch Arztebl Int 2012; 109(49): 857–68.
2. Okuda R, Kinoshita M, Morikawa J, Jotoku T, Abe M. Distal soft tissue

- procedure and proximal metatarsal osteotomy in hallux valgus. *Clin Orthop Relat Res.* 2000; 379:209-217.
3. Glynn MK, Dunlop JB, Fitzpatrick D. The Mitchell distal metatarsal osteotomy for hallux valgus. *J Bone Joint Surg [Br]* 1980;62-B:188-91.
  4. Nguyen US, Hillstrom HJ, Li W, et al.: Factors associated with hallux valgus in a population-based study of older women and men: the MOBILIZE Boston Study. *Osteoarthritis Cartilage* 2010; 18: 41-6.
  5. Lam SL, Hodgson AR. A comparison of foot forms among the non-shoe and shoe wearing Chinese population. *J Bone Joint Surg [Am]* 1958;40-A:1058-62.
  6. Kato S, Watanabe S. The etiology of hallux valgus in Japan. *Clin Orthop* 1981; 157:78-81.
  7. Myerson MS, Badekas A. Hypermobility of the first ray. *Foot Ankle Clin* 2000;5:469-84.
  8. Klaue K, Hansen ST, Masquelet AC. Clinical, quantitative assessment of first tarsometatarsal mobility in the sagittal plane and its relation to hallux valgus deformity. *Foot Ankle Int* 1994; 15:9-13.
  9. Robinson AHN, Limbers JP. Modern concepts in the treatment of hallux valgus. *J Bone Joint Surg [Br]* 2005;87-B:1038-45.
  10. Gallentine JW, Deorio JK, Deorio MJ. Bunion surgery using locking-plate fixation of proximal metatarsal chevron osteotomies. *Foot Ankle Int.* 2007;28:361-368.
  11. Kwiatkowski TC, Anderson RB, Davis WH, Gill LH, Kiebzak GM. Chevron osteotomy in patients  $\geq 55$  years of age for treatment of hallux valgus deformity. Read at the Annual Meeting of the American Academy of Orthopaedic surgeons, New Orleans, Louisiana March 20, 1998.
  12. Leventen E.O. The chevron procedure. *Orthopedics* 1990;13: 973-76.
  13. Colloff B, Weitz E: Proximal phalangeal osteotomy in hallux valgus. *Clin Orthop* 1967; 54:105.
  14. Goldberg I, Bahar A, Yosipovitch Z: Late results after correction of hallux valgus deformity by basilar phalangeal osteotomy. *J Bone Joint Surg* 1987;69A:64.
  15. Frey C, Jahss M, Kummer F: The Akin procedure: an analysis of results. *Foot Ankle* 1991;12:1.
  16. Jones S, Al Hussainy HA, Ali F, Betts RP, Flowers MJ. Scarf osteotomy for hallux valgus: a prospective clinical and pedobarographic study. *J Bone Joint Surg Br.* 2004;86:830-836.
  17. Mann RA, Rudicel S, Graves SC. Repair of hallux valgus with a distal soft-tissue procedure and proximal metatarsal osteotomy: a long-term follow-up. *J Bone Joint Surg [Am]* 1992;74-A:124-9.
  18. Stephens MM. Pathogenesis of hallux valgus. *Eur J Foot Ankle Surg* 1994;1:7-10.
  19. Bai LB, Lee KB, Seo CY, Song EK, Yoon TR. Distal chevron osteotomy with distal soft tissue procedure for moderate to severe hallux valgus deformity. *Foot Ankle Int.* 2010 Aug; 31(8):683-8.
  20. Choi YR, Lee HS, Jeong JJ, Kim SW, Jeon IH, Lee DH, Lee WC. Hallux valgus correction using transarticular lateral release with distal chevron osteotomy. *Foot Ankle Int.* 2012 Oct;33(10):838-43.
  21. Philipp L; Christine F; Franz K; Jens S; Joachim G; Martin H. Clinical outcome after Chevron-Akin double osteotomy versus isolated Chevron procedure: a prospective matched group analysis. *Archives of Orthopaedic & Trauma Surgery* Jan 2012;132(1):9.
  22. Zettl R, Trnka HJ, Easley M, Salzer M, Ritschl P. Moderate to severe hallux valgus deformity: correction with proximal crescentic osteotomy and distal soft-tissue release. *Arch Orthop Trauma Surg.* 2000;120(7-8):397-402.

23. Mitchell LA, Baxter DE. A Chevron-Akin double osteotomy for correction of hallux valgus. *Foot Ankle*. 1991 Aug;12(1):7-14.
24. Donnelly RE, Saltzman CL, Kile TA, Johnson KA. Modified chevron osteotomy for hallux valgus. *Foot Ankle Int* 1994;15:642-5.
25. Green MA, Dorris MF, Baessler TP, Mandel LM, Nachlas MJ. Avascular necrosis following distal Chevron osteotomy of the first metatarsal. *J Foot Ankle Surg* 1993;32:617-22.
26. Horne G, Tanzer T, Ford M. Chevron osteotomy for the treatment of hallux valgus. *Clin Orthop* 1984;183:32-6.
27. Meier PJ, Kenzora JE. The risks and benefits of distal first metatarsal osteotomies. *Foot Ankle* 1985;6:7-17.

How to cite this article: Priyadarshi A, Panigrahi R, Mahapatra AK et. al. Outcome of surgical correction of hallux valgus deformity by chevron-akin double osteotomy- a prospective study. *Int J Health Sci Res*. 2015; 5(4):18-25.

\*\*\*\*\*

**International Journal of Health Sciences & Research (IJHSR)**

**Publish your work in this journal**

The International Journal of Health Sciences & Research is a multidisciplinary indexed open access double-blind peer-reviewed international journal that publishes original research articles from all areas of health sciences and allied branches. This monthly journal is characterised by rapid publication of reviews, original research and case reports across all the fields of health sciences. The details of journal are available on its official website ([www.ijhsr.org](http://www.ijhsr.org)).

Submit your manuscript by email: [editor.ijhsr@gmail.com](mailto:editor.ijhsr@gmail.com) OR [editor.ijhsr@yahoo.com](mailto:editor.ijhsr@yahoo.com)