



Original Research Article

## **Nephrotoxic Effects of Methanolic Extract Of *Azadirachta Indica* (Neem) Root Bark on the Histology of Adult Wistar Rats**

Onimisi, BO<sup>1</sup>, Nadabo YA<sup>2</sup>, Musa SA<sup>3</sup>, Musa MA<sup>1</sup>

<sup>1</sup>Department of Anatomy, College of Health Sciences, Usmanu Danfodiyo University, Sokoto. <sup>2</sup>Department of Anatomy, Faculty of Medicine, Kaduna State University, Kaduna.

<sup>3</sup>Department of Human Anatomy, Faculty of Medicine, Ahmadu Bello University, Zaria.

Corresponding Author: Onimisi, BO

Received: 14/02/2015

Revised: 15/03/2015

Accepted: 18/03/2015

### **ABSTRACT**

*Azadirachta indica* (neem) is a versatile medicinal plant that has been consumed for its plausible medicinal applications and pharmacological activities. Thus, extensive investigation is needed to evaluate its safety index. This study evaluated the histological effects of neem root bark on the kidneys of 24 adult wistar rats divided into 4 groups of A, B, C and D with 6 animals each. Group A served as the control and was administered normal saline, while groups B, C and D which served as the experimental groups received 500mg/kg, 1000mg/kg, 2000 mg/kg of methanolic extract of neem root bark orally respectively for three weeks. The rats were sacrificed at the end of the treatment and the kidneys were excised and fixed in 10% formol saline for routine histological study. Histopathological examination using H & E revealed normal histological architecture of the cortex and medulla in the control group A. For the treated group B, focal area of necrosed glomerulus and mononuclear cellular infiltration was seen in the cortex. In the medulla however, there was no significant histopathologic findings. In groups C and D, the cortex showed focal area of necrosed glomeruli and tubular cells. Pyknotic, karyorhexic, macrophagic cells infiltration and wider tubular lumen were also observed, with no significant histopathologic findings in the medulla. Based on the above findings, this study showed that Neem root bark extract is nephrotoxic at certain specific doses; hence, care must be taken of its consumption.

**Keywords:** *Azadirachta indica*, Kidney, Nephrotoxic, Wistar rats.

### **INTRODUCTION**

The role of medicinal plants in complementary medicine has received tremendous attention globally. Moreover, the World Health Organization estimates that up to 80% of people still rely mainly on traditional medicine, such as herbs. <sup>[1]</sup> And up to 90% of the populations of certain African countries still depend exclusively on herbs for their healthcare. <sup>[2]</sup> Therefore, the

continuous appraisal of these plants for safety and toxicity profile is paramount. Neem (*Azadirachta indica* A.Juss) belongs to the family *Meliaceae* and is one of the most versatile and eco-friendly trees of tropical regions which are now widely distributed in south Asia and parts of Africa. <sup>[3]</sup>

Several medicinal applications and pharmacological activities of various parts

of neem are well known, the oil, bark and leaf extract have been therapeutic used as folk medicine to control leprosy, respiratory disorders and also, general health promoter. [4] Solvent extracts and products of neem have been reported to be anti inflammatory, antinociceptive, antipyretic antioxidant, spermicidal, antidiabetic, anticancer among others. [5-8] It was demonstrated that Neem leaf aqueous extract effectively suppresses oral squamous cell carcinoma induced by 7, 12-dimethylbenzathracene (DMBA) as revealed by reduced incidence of neoplasm. [9] Anti fertility effect of neem oil was also studied and suggested to be a novel method of contraception [10,11] Oral administration of neem leaf has been reported to show anti-fertility in mice. [12]

The aqueous extract of neem leaf has been found to offer protection against paracetamol induced liver necrosis in rats. [13] Toxicological appraisal of the crude ethanolic extract of *A. indica* stem bark intraperitoneally administered at the doses of 100, 200, 400, 800, 1600, 3200 mg/kg body weight to adult swiss albino rats of both sexes has been reported to yield a dose related clinical signs of toxicity such as (anorexia, dehydration, malaise, respiratory depression, coma and death) as well as histopathological changes in the kidney, trachea, bronchi, bronchioles, and lungs. [14] The ethanolic root extract has also been documented to exhibit a dose dependent hepatotoxicity, but the aqueous extract was not injurious to the liver. [15] The aim of this work is to investigate the effects of methanolic extract of Neem (*Azadirachta indica*) root bark at doses: 500, 1000 and 2000mg/kg body weight on the histomorphology of the kidney of wistar rat.

## **MATERIALS AND METHODS**

Twenty four (24) Wistar rats consisting of twelve (12) females and twelve (12) males weighing between 170g to 250g

were obtained and kept in plastic cages in the animal house of department of Human Anatomy, Faculty of medicine Ahmadu Bello University Zaria to standardize and acclimatize for a period of two weeks. The animals were randomly distributed into four groups (A-D) of six animals each. Animals in Group A served as the control and were administered normal saline, while groups B, C and D which served as the experimental groups received 500 mg/kg, 1000 mg/kg, 2000 mg/kg of methanolic extract of neem root bark orally respectively for three weeks.

Meanwhile, the acute toxicity study of the methanolic extract of neem root bark was carried out using Lorke's method (1983) and the LD<sub>50</sub> was above 5000 mg/kg body weight. The neem root was collected from Wusasa, Zaria, Nigeria. The bark was collected after which it was dried under shade and pounded into powdered form. This was done having identified the plant in the Department of Biological Science ABU Zaria, where a vouchers specimen No 900151 was deposited.

Following the three weeks treatment with methanolic extract, the rats were sacrificed and the kidneys were excised and fixed in 10% formol saline for routine histological study. Histopathological examination was done using H & E stain. The histological slides were observed under the microscope with magnification of X400 and X 200 and the photomicrograph taken.

## **RESULTS & DISCUSSION**

Neem plant has long been consumed for its enormous and credible medicinal purposes, thus, the need for toxicological analysis of neem plant since its controlled dosage has not been established. [16] Moreso, toxicity studies in animals are commonly used to assess potential health risk in humans caused by intrinsic adverse effects of chemical compounds/plant extracts. [17-19]

These adverse effects may manifest significant alterations in the normal functioning and histomorphology of the organ as well as the levels of biomolecules such as enzymes and metabolic products. [20]

From the present study, the micro-architectural appearance of the cortex and medulla of the kidneys from the wistar rats in the control group showed a normal histological appearance (Figure 1 (a) and (b)), as against the kidneys from the rats in the experimental groups.

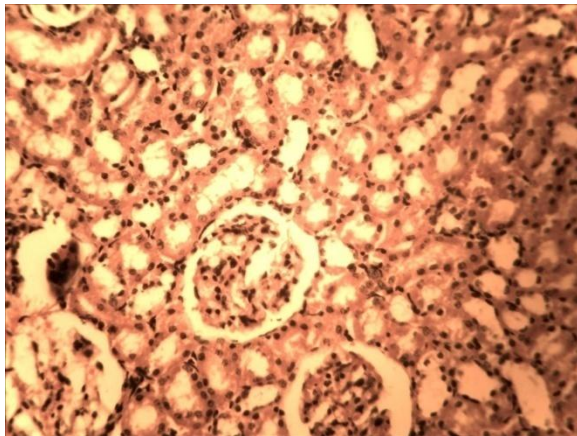


Figure 1 (a): Showing photomicrograph of normal histological architecture of cortex of kidney from group A. Note glomerulus, distal convoluted tubule and proximal convoluted tubule. (H/E x 250).

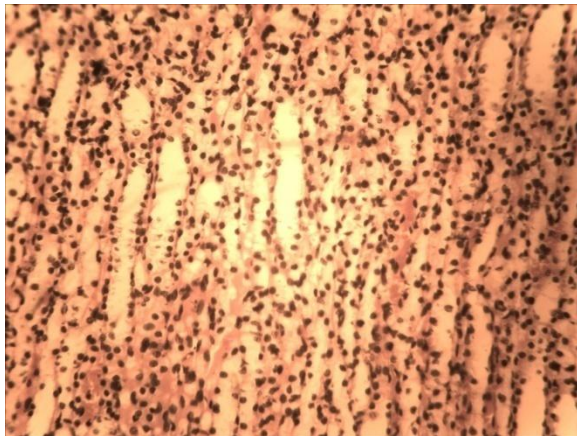


Figure 1(b): Showing photomicrograph of normal histological architecture of the medulla of kidney from group A. Note the loop of Henle. (H/E x 250).

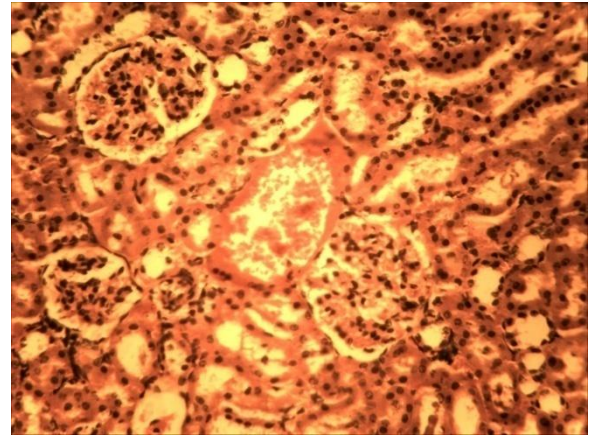


Figure 2 (a): Showing photomicrograph of cortex of the kidney from group B. Note the necrosed glomeruli. (H/E x 250).

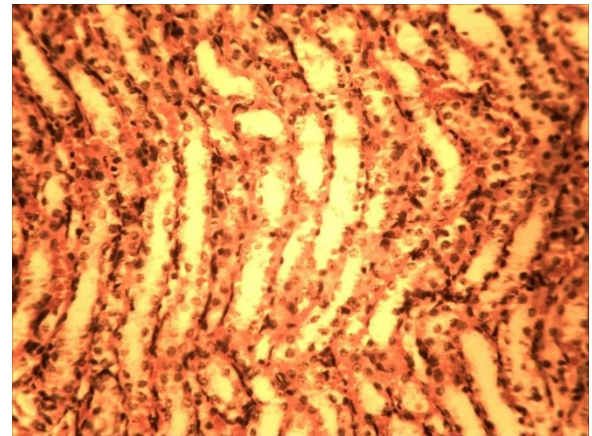


Figure 2(b): Showing photomicrograph of medulla from group B. Note: Inflammatory cellular infiltration with Tubular necrosis. (H/E x 250)

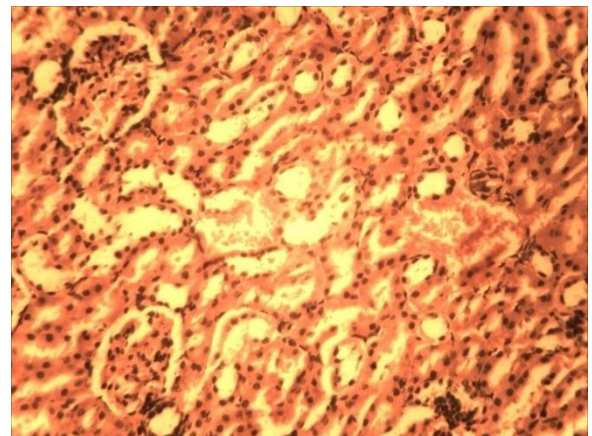
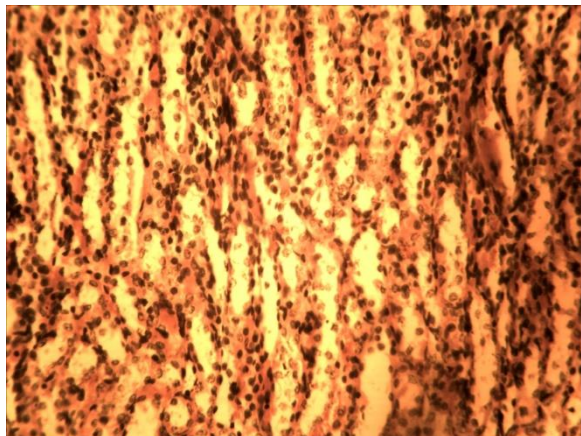
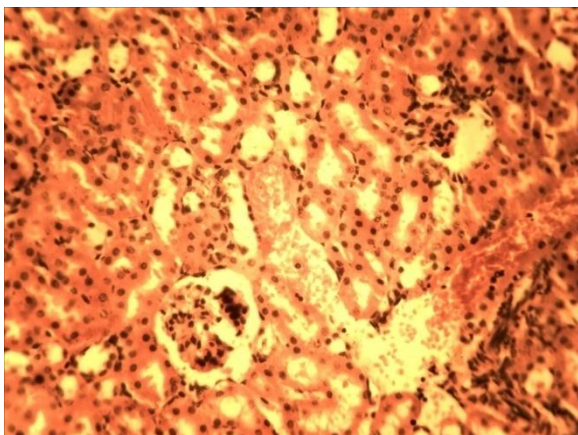


Figure 3 (a): Showing photomicrograph of cortex of kidney from group C. Note: Focal inflammatory cellular infiltration and Tubular degeneration. (H/E x 250).

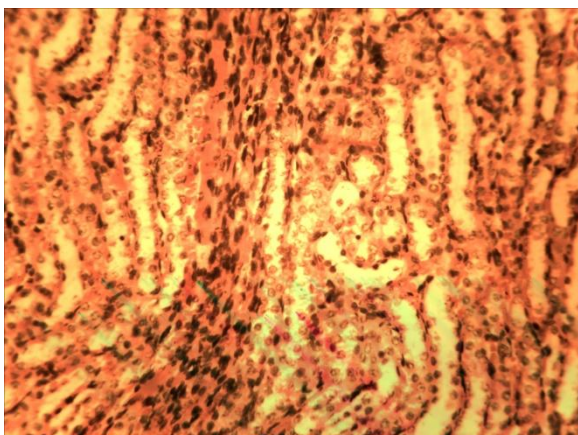




**Figure 3 (b):** Showing photomicrograph of medulla from group C. Note: Severe cellular infiltration predominantly lymphocyte with few plasma cells. (H/E x 250).



**Figure 4 (a):** Showing photomicrograph of cortex of kidney from group D. Note: Tubular thickening, degeneration and necrosis. (H/E x 250).



**Figure 4 (b):** Showing photomicrograph of medulla of kidney from group D. Note: Severe tubular degeneration, Necrosis and inflammatory cellular infiltration.

Administration of 500mg/kg bw of the extract to animals in group B resulted in focal area of necrosed glomerulus and mononuclear cellular infiltration as seen in the photomicrograph of the cortex -Figure 2(a). This observed cellular infiltration may not be unassociated with interstitial infiltrations seen in variety of disease conditions [21] meanwhile, in the medulla; there were no significant histopathologic findings but moderate inflammatory cellular infiltration (M) with tubular necrosis (TN)

Moreover, following administration of 1000 mg/kg bw of neem methanolic extract to animals in group C, we observed focal inflammatory cellular infiltration and tubular degeneration (TD) as seen in the photomicrograph of the cortex -Figure 3(a). On the other hand, figure 3 (b) shows a photomicrograph of medulla indicating severe cellular infiltration by predominantly lymphocytes with few plasma cells.

Animals in group D which received 2000mg/kg bw of neem extract showed a photomicrograph of cortex of kidney -Figure 4(a) with Tubular thickening (Ttk), degeneration (TD) and necrosis (TN) when compared to the photomicrograph of animals in group C. These observations agree with the dose dependent effect of neem extract as reported by Katsyal et al. [14,22] In the medulla, as shown in Figure 4(b) severe tubular degeneration and necrosis were noted.

Following administration of methanolic extract of neem leaf at doses of 1000 and 2000mg/kg in kidney of wistar rats, Katsyal et al. [22] observed different forms of histopathological changes ranging from vascular congestion in the glomerulus, cellular inflammation, presence of hyaline globules in collecting tubules, infiltration of kidney with lymphocytes. [22] These revelations are in line with our findings of glomerular and tubular necrosis,

degeneration as well as inflammatory cellular infiltration reported in this study.

Our findings however, does not agree with Ghimerah AK et al [23] who reported that at 0.6 - 2.0g/kg bw *A. indica* leaf extract did not cause any lethal effect on histological parameters of experimental animals.

All the histopathological features observed in the present study as seen on the photomicrographs of the kidney of the wistar rats could be due to the presence of some bioactive compounds of neem such as nimbolide and nimbic acid which has been reported to cause death in most animals by dysfunctioning the kidneys, small intestines, liver as well as marked drop of arterial blood pressure. [24] Damage to tubular epithelia membrane by toxins or ischemia can cause renal tubular disorder and chronic renal failure can occur because of the disorders of the blood vessels and glomeruli. Decrease in functional renal nephron, damage or loss of glomeruli and overall nephron could result to progressive decrease in renal blood flow. [25]

## CONCLUSION

In conclusion, it can be deduced that oral administration of methanolic extract of neem root bark has nephrotoxic effect at doses of 500, 1000, 2000mg/kg body weight. Consequently, the methanolic extract of *Azadirachta indica* root bark at these doses may not be completely safe when consumed orally for its medicinal value. Hence, it should be taken with caution

## REFERENCES

1. Tripathi L, Tripathi JN. Role of biotechnology in medicinal plants. *Tropical journal of Pharmaceutical Research*, 2003; 2(2):243-253.
2. Isaac AB, George IN, Olamide TA, James DH. A bioactive flavonoid from

3. Available on [www.neemfoundation.org](http://www.neemfoundation.org). Accessed on December 2014.
4. Kirtikar KR and Basu BD. In *Indian Medicinal Plants*, Lalitha Mohan Basu, Allahabad, (2<sup>nd</sup> edition), 1935; 536.
5. Mahabub-Uz-Zaman M, Ahmed NU, Akter R, Ahmed K, Aziz MSI, Ahmed MS. Studies on anti-inflammatory, antinociceptive, and antipyretic activities of ethanol extract of *Azadirachta indica* leaves. *Bangladesh J Sci Ind Res*. 2009; 44:199-206.
6. Sithisarn P, Roongtawan S, Gritsanapan W, antioxidant activity of Siamese neem tree (VP1209) *J ethnopharmacol*. 2005; 99:109-112.
7. Gupta S, Katari M, Gupta PK, Murganandan S, Yashroy RC., Protective role of extracts of Neem seeds in diabetes caused by Streptozocin In rats. *J ethnopharmacol* 2004;90: 185-189 (pubmed).
8. Vinithini G, Manikandan P, Anandan R, Nagini S. Chemoprevention of rat mammary carcinogenesis by *A. indica* leaf fractions: Modulation of hormone status, xenobiotics, metabiizing enzymes, oxidative stress, cell proliferation and apoptosis. *Food chem Toxicol*. 2009; 47:1852-1863. (Pubmed)
9. Balasenthil S, Arivazhagan S, Ramachandran CR, Nagini S. *Journal of Ethno pharmacology*, 1999; 67:189-195.
10. Upadhyay SN, Kaushic C, Talwar GP. *Proc. Royal Society of London B*, 1990; 242:175-179.
11. Kaushic C and Upadhyay S. *Proc. Royal Society of London*, 1995; 51:203-207.
12. Despande VY, Mendulkar KN, Sadre NL. *Journal of Postgraduate Medicine*, (Bombay), 1980; 26:167-170.
13. Bhanwra S, Singh J, Khosla P. *Indian journal of physiology and pharmacology*, 2000; 44:64-68.
14. Mbaya AW, Ibrahim UI, Thank God O, Ladi S. Toxicity and potential anti-trypanosomal activity of ethanolic

- extract of *Azadirachta indica* (Maliaceae) stem bark: An in vivo and in vitro approach using trypanosome brucei. *J Ethnopharmacol.*2010; 128: 495-500.
15. Nwachukwu N, Igwenyi I. Influence of extraction method on the hepatotoxicity of *A. indica* root. *J Res Biosci.* 2006; 2:10-23
  16. Sofowora JI. *Medicinal Plants and Traditional Medicine in Africa* (2<sup>nd</sup> Edn). Spectrum Books Limited, 1993; 5:174-183.
  17. Klaassen CD, Eaton DL. Principles Of Toxicology. In :Klaassen CD, Editor Cassaret and Doull's toxicology: the basic science of poison. New York: pergamon press; 1991; 32.
  18. Afolayan AJ, Yakubu MT. Effect of *Bulbine Natalensis* Baker stem extract on the functional indices and histology of the liver and kidney of male wister rats. *J med food.* 2009; 12:814-820.
  19. Oyedemi SO, Yakubu MT, Afolayan AJ. Effect of aqueous extract of *leonotis leonorus* (L.) R.BR. Leaves in male wister rats. *Hum. EXP.Toxicol.*2010; 29:377-384.
  20. Yakubu MT, Bukoye BB, Oladiji AT, Akanji MA. Toxicological implications of aqueous extract of *Bambusa Vulgaris* leaves in peggant Dutche rabbits. *Hum Exp Toxicol.* 2009; 28 591-598.
  21. Young B. Heath JW. *Wheater's Functional Histology – Test and Colour Atlas* (4th ed.). Churchill Livingstone, Edinburgh, 2000; 30.
  22. Katsayal, UA, Nadabo YA, Isiorho VJ. Effects Of Methanol Extract Of *Azadirachta Indica* Leaves On The Histology Of Liver And Kidney Of Wister Rats, Nig. *Journ. Pharm. Sci.*2008; 7 (1): 9 – 14
  23. Ghimerah AK, Jin C, Ghimire BK, Cho DH. Antioxidant activity and quantitative estimation of *Azadirachtin* and *nimin* in *Azadirachta indica* A. Juss grown in foothills of Nepal. *Afri J of Bio.* 2009; 8:3084-3091
  24. Cohen E, Quistad GB, Casida JE. *Life Science.* 1996; 58:1075-1081.
  25. Ganong WF. *Review of Medical Physiology* (22<sup>nd</sup> Edn.), McGraw Hill, India, 2005; 517-533.

How to cite this article: Onimisi BO, Nadabo YA, Musa SA et. al. Nephrotoxic effects of methanolic extract of *azadirachta indica* (neem) root bark on the histology of adult wistar rats. *Int J Health Sci Res.* 2015; 5(4):116-121.

\*\*\*\*\*