



Case Report

## Cryptococcal Lymphadenitis- A Case Report

Namrata Rao<sup>1</sup>, Ramya B.S<sup>2</sup>, M. Natarajan<sup>3</sup>, A. R. Raghupathi<sup>4</sup>

<sup>1</sup>Junior Resident, <sup>2</sup>Assistant Professor, <sup>3</sup>Professor, <sup>4</sup>Professor and Head,  
Department of Pathology, Bangalore Medical College and Research Institute, Bangalore, Karnataka, India.

Corresponding Author: Namrata Rao

Received: 17/01/2015

Revised: 14/02/2015

Accepted: 19/02/2015

### ABSTRACT

**Background:** Cryptococcosis is an opportunistic infection caused by *Cryptococcus neoformans*. It is a common opportunistic infection in patients with HIV. However lymph node involvement is rare.

**Case Report:** We present a case of a 51 year old retropositive patient who presented with fever and altered sensorium. Fine needle aspiration from the enlarged posterior cervical lymph node showed multiple yeast forms of a fungus having a prominent capsule. Diagnosis of *Cryptococcus* was confirmed by negative staining with India Ink.

**Conclusion:** Fine needle aspiration is a simple and economical procedure that provides a quick diagnosis of cryptococcal infection.

**Key Words:** *Cryptococcus*; lymph node; FNA; India ink; HIV

### INTRODUCTION

Cryptococcosis is a chronic opportunistic infection caused by the encapsulated yeast *Cryptococcus neoformans*.<sup>(1)</sup> Cryptococcal infection is the second most common life-threatening, opportunistic infection in human immunodeficiency virus (HIV)-infected individuals after *Mycobacterium tuberculosis*.<sup>(2)</sup> Primary infection is usually through the respiratory system but dissemination to central nervous system (CNS), skin, bone, lymph node, kidney and other viscera may occur.<sup>(3)</sup> Lymph node involvement is rarely found in cryptococcal infection in either HIV-infected or HIV-negative individuals.<sup>(4,5)</sup> Fine needle aspiration is an economical procedure that

provides a quick diagnosis of cryptococcal lymphadenitis.

### CASE REPORT

A 51 year old male patient presented with history of fever since 4 months, passing blood in stools since 5 days and history of altered sensorium since 1 day. The patient was detected to be retro positive two years back. Despite counseling the patient was not on anti retroviral therapy. On examination his vitals were stable. The patient was aphasic and was unresponsive to commands. Multiple posterior cervical lymph nodes were enlarged, largest measuring 2x2cms. The lymph nodes were discrete, firm and mobile. Routine investigations were done. The peripheral smear showed microcytic

hypochromic anemia with neutrophilic leukocytosis. His CD 4 counts were 180 cells/mm<sup>3</sup>.

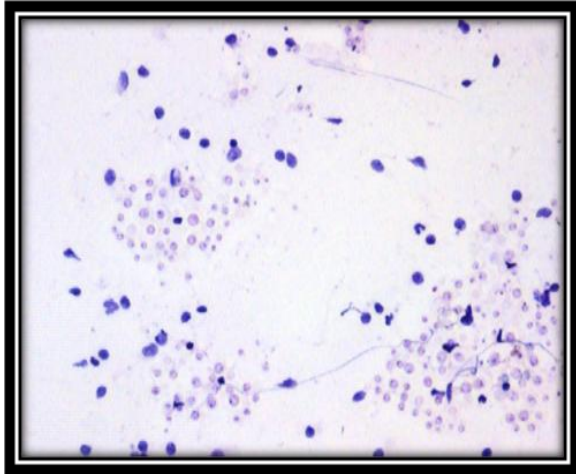


Figure 1: Cryptococci in lymph node aspirate (H&E-10 x)

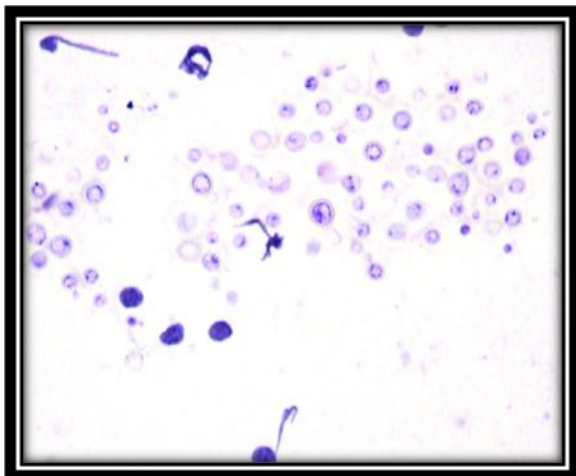


Figure 2: Cryptococci in lymph node aspirate (H&E-20 x)

Fine needle aspiration was done from the largest lymph node. The aspirate was grey white material. On examination, Slides stained with hematoxylin and eosin revealed multiple yeast forms of a fungus in clusters and scattered individually against a background of polymorphous population of lymphoid cells and histiocytes. The fungal organisms had a prominent capsule. Areas of necrosis were also observed. (Figure 1 & 2). On India ink preparations, the unstained capsules of the fungus were distinctly seen against a black background. (Figure 3).

Diagnosis of CRYPTOCOCCAL LYMPHADENITIS was given.

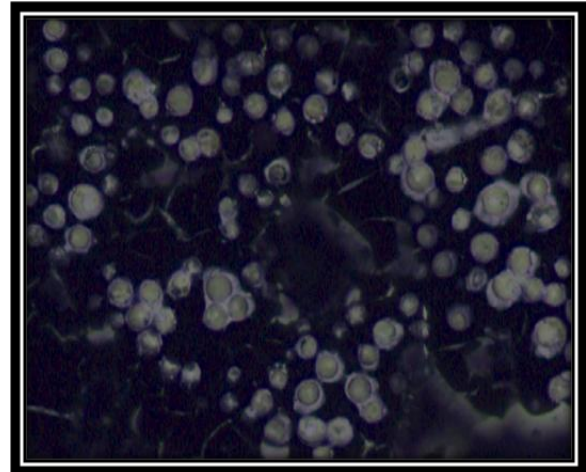


Figure 3: Cryptococci in lymph node aspirate (India Ink- 40 x)

## DISCUSSION

Cryptococcosis is gaining importance due to the rapid surge in the incidence of HIV. Cryptococcal lymphadenitis is an uncommon form of extrapulmonary cryptococcosis, which is one of the AIDS defining criteria according to the Centre for Disease Control and prevention guidelines.<sup>(6)</sup> Cryptococcus has been reported from cytological specimens of CSF, sputum, bronchial washing and FNAC smears of the lymph nodes, thyroid, spleen, adrenal gland, bones and the lung. The organism is surrounded by a mucopolysaccharide capsule and measures 5–15  $\mu\text{m}$  in diameter. It is single, narrow-based, budding yeast. Special stains (Gomori's methenamine silver (GMS), PAS, and mucicarmine) facilitate the identification of this organism. In our case too, budding yeast forms were identified in clusters and singles which exhibited negative staining with India ink. There are few reports of correlations of cryptococcal lymphadenitis in HIV patients with their CD4 T lymphocyte count, where authors have found that correlations of lesions with CD4 T lymphocyte count provides

information about immune status and stage of the HIV disease. They have concluded that cryptococcosis shows least CD4 count values as compared to other lesions in HIV. In our case also, CD4 count was as low as 180cells/ $\mu$ l reflecting advanced disease state. (4,7)

## CONCLUSION

Fine needle aspiration is a very simple and efficient procedure in the diagnosis of fungal infections. The procedure enables rapid diagnosis and prompt initiation of treatment. Negative staining with India ink aids in a quick confirmation of the diagnosis.

## REFERENCES

1. Das BP, Panda PL, Mallik RN. Das B. Cryptococcal lymphadenitis and meningitis in human immunodeficiency virus infection: A case report. Indian Journal of Pathology Microbiology, 2002; 45(3): 349- 351
2. Suchitha, S., Sheeladevi, C. S., Sunila, R. & Manjunath, G. V. Fine needle aspiration diagnosis of cryptococcal lymphadenitis: a window of opportunity. J Cytol2008; 25: 147–149
3. Andola SK, Ahuja M, Shaik I. Cryptococcal lymphadenitis on Fine Needle Aspiration Cytology: A report of 2 cases. People's J Scientific Research 2012; 5(2):33-35
4. Kumarguru BN, Kulkarni MH, Kamakeri NS. FNAC of peripheral lymph nodes in HIV positive patients. Sci Med 2009; 19(2):4-12
5. Srinivasan, R., Gupta, N., Shifa, R., Malhotra, P., Rajwanshi, A. & Chakrabarti, A. Cryptococcal lymphadenitis diagnosed by fine needle aspiration cytology: a review of 15 cases. ActaCytologica 2010; 54: 1–4
6. Scheider E, Whitmore S, Glynn MK, Dominguez K, Mitsch A, McKenna MT. Revised surveillance case definitions for HIV infection among adults, adolescents and children aged <18 months and for HIV infection and AIDS among children aged 18 months to <13 years- United States, 2008 MMWR Recommendation & Reports, 2008; 57(10):1-8
7. Jayaram G, Chew MT. Fine needle aspiration cytology of lymph nodes in HIV infected individuals. Actacytol 2000; 44:960-966.

How to cite this article: Rao N, Ramya BS, Natarajan M et. al. Cryptococcal lymphadenitis- a case report. Int J Health Sci Res. 2015; 5(3):430-432.

\*\*\*\*\*