



Case Report

Double Meckel's with Heterotopic Pancreas: A Unique Case & Its Embryo-Genetic Correlation

Ambekar Swapna Ashok¹, Kulkarni Anjali Sanjay², Kulkarni Sanjay Shyam³, Phulgirkar Pragati Prabhakar²

¹Associate Professor, Department of Anatomy, JIIU'S Indian Institute of Medical Sciences, Warudi, Badnapur, District- Jalna Maharashtra, India

²Assistant Professor, Department of Pathology, Government Medical College, Aurangabad, Maharashtra, India

³Consulting Anesthesiologist, Padmawati Hospital and Critical Care, Aurangabad, Maharashtra, India

Corresponding Author: Kulkarni Anjali Sanjay

Received: 25/01/2015

Revised: 14/02/2015

Accepted: 18/02/2015

ABSTRACT

Meckel's diverticulum (MD) is a vestigial remnant of vitellointestinal duct. Pluripotent cells line vitellointestinal (VID) duct, thus it may contain ectopic mucosa. The diverticulum may or may not be attached to the umbilicus with a fibrous cord. Pancreatic tissue present outside boundaries of the normal pancreas is termed as heterotopic pancreas. It is frequently associated with gastrointestinal tract but may also be seen in Meckel's diverticulum. We report a three-year old boy with signs of acute intestinal obstruction. On exploration it was discovered to be with two Meckel's diverticulae and total heterotopic pancreatic tissue at terminal part of proximal MD. A fibrous band extended from ileum to retroperitoneal tissue below umbilicus with dilated bowel loop above the band near distal MD. MD can lead to various complications including intestinal obstruction and should always be considered for differential diagnosis of acute abdominal pain or bleeding. Heterotopic pancreas is usually asymptomatic but may present with bleeding, pain or ulceration.

Two Meckel's diverticulae with heterotopic pancreas as seen in this case is not yet reported in literature.

Key words: Vitellointestinal duct, intestinal duplication, Meckel's diverticulae, heterotopic pancreas, medical emergency, expression of genes.

INTRODUCTION

MD has all 3 coats of the small intestine. Generally, it follows rule of 2 that is 2% incidence, 2 feet away from ileocecal valve and 2 inches long. ^[1] It frequently contains heterotopic tissue; where gastric mucosa accounts for 50%. Pluripotent cells line VID, thus it may contain gastric, colonic, duodenal or pancreatic mucosa. It might remain completely asymptomatic or may lead to life threatening complications.

In diverticulae, incidence of pancreatic tissue is 5 to 16%. ^[2] Heterotopic pancreas is regarded as aberrant pancreas or an accessory pancreatic tissue that has no anatomical, vascular or neuronal connection with the main pancreas. Such anomalies can become apparent at any age. They occur with slight male predominance.

Aim of this study is to discuss clinical importance of Meckel's diverticulum and heterotopic pancreas and to discuss

embryological and genetic basis of development of such a rare condition.

CASE REPORT

A 3 years old boy was admitted to Government Medical College, Aurangabad with the complaints of pain and distension of abdomen with vomiting since 2 days. On admission, physical examination and vital signs of the patient were normal. Laboratory tests revealed normal liver enzymes, liver function tests. Patient was diagnosed as a case of acute intestinal obstruction.

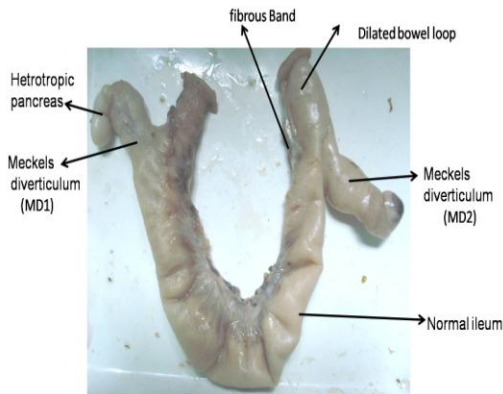


Image 1 – Specimen showing resected loop of ileum
 Note - two diverticulæ MD1 & MD2
 pancreatic tissue at terminal portion of MD1
 Note the fibrous band below the dilated bowel loop of ileum proximal to MD2.

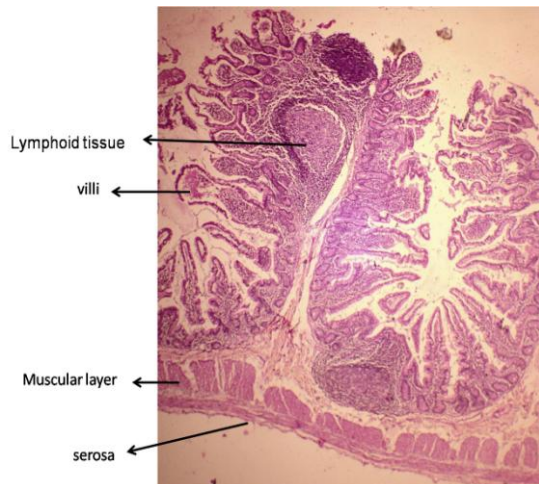


Image 2 showing Histology of meckels diaverticulum by routine H/E stain
 Note the histology of both meckels diverticulæ resembled normal ileum

Exploratory laparotomy was done and the affected ileal loop was resected. Postoperative period was uneventful and patient was discharged successfully.

Resected loop (image1) had two Meckel's diverticulæ situated about six inches apart. First Meckel's diverticulum (MD1) showed presence of ectopic tissue at its terminal part. Also a fibrous band was noted two inches proximal to second diverticulum (MD2) with dilated bowel loops above the band. It was extending from ileum to retroperitoneum. The surgical specimen was fixed in 10% formalin, routinely processed, and embedded in paraffin. Three-micrometer thick sections were cut from MD1, MD2 and ectopic tissue; slides were stained with hematoxylin-eosin stain. Histology of both the Meckel's diverticulum resembled ileum (image2). Examination the terminal portion of MD1 revealed total heterotopic pancreatic tissue (image3).

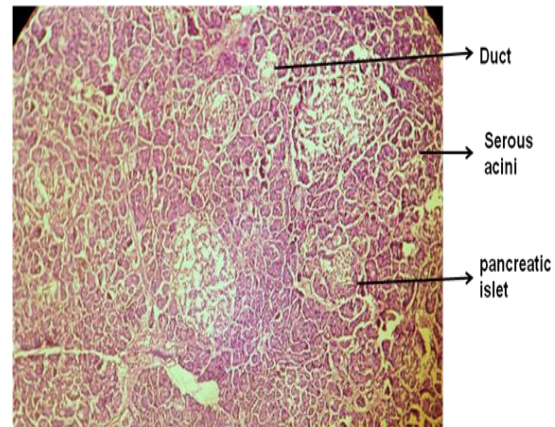


Image 3 showing histology of heterotopic pancreatic tissue
 note- exocrine part with duct and endocrine part

DISCUSSION

During early fetal development, midgut gets its nutrition from the yolk sac via VID. As development proceeds, the duct normally becomes occluded and disappears entirely by 8-10 weeks of gestation. Failure of the most proximal part of this duct to obliterate, results in the formation of a

Meckel's diverticulum. The yolk sac contains all the layers of the intestinal wall; therefore the diverticulum arising from it has all layers of the intestinal wall. Anomalies caused by persistence of such duct include Meckel's diverticulum, vitelline cord, enteric cyst, umbilical sinus, enteric fistula or hemorrhagic umbilical mass. ^[1]

Though MD was first described by Fabricius Hildanus in 1598, it is named after the German anatomist, Johann Friedrich Meckel, who described its embryological origin in 1809.

The term intestinal duplication was introduced by Fitz in 1844 when he suggested that alimentary tract duplications arose from persistent VID remnants. ^[2] The etiology of alimentary tract duplications is unknown. It may arise as remnant of embryonic diverticulae during development of the alimentary tract or due to intrauterine vascular accidents, and recanalization and fusion of embryologic longitudinal folds. Abortive twinning may also be the possible causative factor of duplications of colon. However, all theories implicate influence of an environmental stress that affects the development of early fetus. ^[3]

Albu et al in 1992 reported a case of double MD, Leo Tauro has also reported a case of double MD in 2010. ^[4]

Yang Ji-Gang et al has reported medical emergency due to double meckel's diverticulum in 2008. ^[5]

Emre et al conducted a literature review of studies, published in the English where they reported only five cases of double Meckel's diverticulum till 2013. ^[6]

We also have done extensive online search of literature. We found few cases of double MD listed above.

Few cases of intestinal duplication are reported worldwide even reported in India ^[7] but we didn't get even a single reference of case having two MD with heterotopic

pancreatic tissue at its terminal, so far; hence it's the unique case report.

Clinically, though MD usually is asymptomatic; about 2–4% of patients are symptomatic, with complications such as bleeding, perforation, small bowel obstruction, inflammation, intussusception and neoplastic changes. Presence of fibrous band often complicates symptoms of MD and is mostly responsible for obstruction. ^[4,2,8,9]

Diverticulitis is a result of ulceration secondary to acid secretion from ectopic mucosa and leads to bleeding. Cases of Neoplasms arising from Meckel's diverticulum are also reported. Sometimes MD may mimic some disorders like Crohn's disease, Appendicitis and peptic ulcer diseases. ^[8] Gastrointestinal bleeding is the most common complication in children with MD, whereas small bowel obstruction and diverticulitis are the most common complications in adults ^[9] but we reported acute intestinal obstruction in child.

Heterotopic pancreas was first described by Shultz in 1727. The incidence of Heterotopic pancreas during surgical exploration of the upper part of the abdomen is less than 0.5% of abdominal laparotomies, and 1-2% of autopsies. ^[10]

Embryological explanation of development of above variant can be given as follows: The pancreas arises from endoderm as a dorsal and a ventral bud which fuse together at the sixth week of gestation to form the single organ. If one or more evaginations develop in the wall of the bowel, it may be carried longitudinally either proximally or distally from the remainder of the gland by the growing gastrointestinal tract to produce heterotopic pancreas. ^[11,12]

The pathogenesis of these lesions is unknown; they might arise during rotation of the foregut by "misplacement theory" or

migration of pancreatic metaplasia during embryonic life. ^[13]

Histologically, heterotopic pancreas is of 4 types: those comprising (i) ducts only (canalicular heterotopia), (ii) acinar cells only (exocrine heterotopia), and (iii) islet cells only (endocrine heterotopia) iv) all cell types (total heterotopia), ^[11]

In our case, it's predominantly exocrine with duct system and few discrete endocrine foci (image 3) hence labeled as total heterotopia.

Hoey C Koh ^[2] described pancreatic adenocarcinoma arising from ectopic pancreatic tissue in Meckel's diverticulum. The tumour was so aggressive that the patient expired within 5 months of symptom onset.

The vast majority of patients are asymptomatic. Though gastric pain is most commonly reported, other associated complaints are bleeding, nausea, ulceration, vomiting, and chest pain. The etiology for the production of symptoms is unknown. Armstrong et al suggested that there is a correlation between the symptoms, size of the lesion (greater than 1.5 pcm), and extent of mucosal involvement. ^[11]

Development of heterotopic pancreas at the terminal portion of MD1 could be explained genetically by expression of particular genes at particular site. Various genes are responsible for differentiation of particular cell either as intestinal cell or pancreatic, that to either as exocrine or endocrine and this in turn depends on signaling molecules. Many researchers have explained it in details as follows –

1-Larson ^[1] -Regionalization of the gut plays important role in demarcating site of organ formation. Regional specification of endoderm and its interaction with mesoderm, neural crest and ectoderm are important in development. Regionalization depends on signaling molecules derived from primitive streak and organizers.

Genes responsible for development of endodermal tube are Cdx1, Cdx2, Cdx3, Shh, Fgfs, Pdx1, Pax and various Hox genes.

2 - Slack J. ^[14] For development of pancreatic bud, uniform expression of the homeobox gene *IPF-1* (also known as *IDX-1*, *STF-1* or *PDX*), is must inactivity of these gene leads to total absence of the organ. The occurrence of heterotopic pancreas in the embryo and the metaplasia displayed by a regenerating pancreas in the adult suggest that only few gene products distinguish pancreatic cell state from that of the surrounding tissues of intestine.

3- Jane Jensen ^[15] The genes involved in establishing an endodermal fate are *Sox*, *Mix* genes. Certain genes are positioned in a "core endodermal program," which includes several HNF-type genes (e.g., *Hnf1β* [*tcf2*], *HNF1α* [*tcf1*], *Hnf4*, *Hnf3β* [*Foxa2*], *Hnf6* [*Onecut1*]). One of these, *Foxa2*, is positively autoregulated, suggesting an intrinsic stability of particular state. Many of these genes play role in tissue-specific gene regulation in adult cells, including pancreas, liver, lung, and intestinal gene expression. These factors appear to cooperate with more tissue-specific regulators, such as *Pdx1* (*ipf1*; pancreas), *gata4* (intestine, liver). Pancreatic determination involves the activation of *Pdx1* and *HB9*, immediately followed by activation of other genes (e.g., *Nkx2.2*, *Nkx6.1*). In comparison, intestinal development relies on the activation of *Cdx1* and *Cdx2*, which helps secure intestine-specific gene expression pattern. In endocrine pancreas, activation of neurogenin3 (*atoh5*) *Pax6*, *Isl1*, *NeuroD* is needed. Analogously, exocrine development relies on the continued activation of the *Ptf1a* gene, followed by *Mist1*. Combination of a gene set is determining tissue specificity and not the single action of a highly specific master regulator.

From this genetic discussion, we can simply conclude that many factors are responsible for development of one organ at specific region and its relation to the surrounding structures. Any change in expression of gene or its signaling leads to anomalies or variations.

CONCLUSION

Meckel's diverticulum is rarely suspected due to its low incidence. It mimics other intestinal diseases and so, may be misdiagnosed. Proper knowledge of double Meckel's diverticulum is helpful for clinicians, radiologist and surgeons. It will also stimulate embryologist and geneticist for further study of such variant.

Conflict Of Interest

The authors have no potential conflicts of interest.

Author's Contributions

Dr. Swapna Ashok Ambekar is responsible for design, drafting and interpretation of case.

Dr. Kulkarni Anjali Sanjay done critical revision of the article for intellectual content.

Dr. Sanjay Kulkarni and Dr Pragati Phulgirkar has done the final approval of the version to be published.

REFERENCES

1. Schoenwolf G.C, Bleyl S.B, Brauer P.R, Larson's Human Embryology 4th ed. 2009 pg 442-54
2. Koh H C, Page B, Black C, Brown I, Ballantyne S and Galloway D. J; Ectopic pancreatic-type malignancy presenting in a Meckel's diverticulum: a case report and review of the literature *World Journal of Surgical Oncology* 2009, 7:54 doi:10.1186/1477-7819-7-54 <http://www.wjso.com/content/7/1/54>
3. Suzanne T, Ildstad M.D ,David J, Tollerud, M.D., Richard etal: Duplications of the Alimentary Tract: *Ann. Surg.*1988 Aug;208(2):184-9
4. Tauro L,George C, Rao B, John J etal. Asymptomatic Meckel's Diverticulum

- in Adults: Is Diverticulectomy Indicated? *Saudi J Gastroenterol.* 2010 July; 16(3): 198–202.
5. Yang, Ji-Gang ; Ma, Da-Qing ,Hao, Rui-Rui, Detection of Double Meckel Diverticulum by Meckel Scan *Clinical Nuclear Medicine: October 2008;33(10) 729-30*
 6. Emre A, Akbulut S, Yilmaz M, Kanlioz M, Aydin BE. Double Meckel's diverticulum presenting as acute appendicitis: a case report and literature review. *J Emerg Med.* 2013 Apr;44(4):321-4.
 7. Jacob S, Mani A, Singh V, Bhatti W; Long segment ileal duplication with extensive gastric heterotopia. *Indian J. of pathol. and microbiol.*2009: 52(3):397-9
 8. Madhyastha S; P Rabhu, V. L.; Saralaya V; Prakash; Meckel's diverticulum. A case report. *Int. J. Morphol.*,25(3):519-522, 2007.
 9. Sengul I., Sengul D, Avcu S and Parlak O. Gangrenous meckel's diverticulum in a strangulated umbilical hernia in a 42 years old woman: A case report: *Cases Journal* 2010,3:10 doi: 10.1186/1757-1626-3-10 <http://www.casesjournal.com/content/3/1/10>
 10. Inoue Y, Hayashi M, Arisaka Y etal Adenocarcinoma arising in a heterotopic pancreas (Heinrich type III): A case report *Journal of Medical Case Reports* 2010, 4:39 doi:10.1186/1752-1947-4-39 : <http://www.jmedicalcasereports.com/content/4/1/39>
 11. Hammock L. & Jorda M, Gastric Endocrine Pancreatic Heterotopia. *Arch Pathol Lab Med:* 2002;126:464-7
 12. Christodoulidis G, Zacharoulis D, Barbanis D etal Heterotopic pancreas in the stomach: A case report and literature review *World J Gastroenterol* 2007 December 7; 13(45): 6098-100
 13. Erkan N., Vardar E, Vardar R. Heterotopic Pancreas: Report of Two

- Cases: JOP Pancreas (Online) 2007; 8(5):588-591.
14. Slack J. M, Developmental biology of the pancreas, Development. 1995 Jun; 121 (6):1569-80.
15. Jensen, J: Gene regulatory factors in pancreatic development. Dev. Dyn,2004:229: 176–200

How to cite this article: Ashok AS, Sanjay KA, Shyam KS et. al. Double Meckel's with heterotopic pancreas: a unique case & its embryo-genetic correlation . Int J Health Sci Res. 2015; 5(3):388-393.

International Journal of Health Sciences & Research (IJHSR)

Publish your work in this journal

The International Journal of Health Sciences & Research is a multidisciplinary indexed open access double-blind peer-reviewed international journal that publishes original research articles from all areas of health sciences and allied branches. This monthly journal is characterised by rapid publication of reviews, original research and case reports across all the fields of health sciences. The details of journal are available on its official website (www.ijhsr.org).

Submit your manuscript by email: editor.ijhsr@gmail.com OR editor.ijhsr@yahoo.com