

*Case Report*

## **Florid Granulomatous Response Masking Diagnosis of Hodgkin's disease in FNA Cytology: a Diagnostic Challenge**

Kanthilatha Pai<sup>1</sup>, Swati Sharma<sup>2</sup>, Padmapriya J<sup>2</sup><sup>1</sup>Professor, <sup>2</sup>Associate Professor,  
Department of Pathology, Kasturba Medical College, Manipal University, Manipal, Karnataka, INDIA

Corresponding Author: Swati Sharma

*Received: 09/01/2015**Revised: 22/01/2015**Accepted: 27/01/2015*

### **ABSTRACT**

Granulomatous lymphadenitis is a common diagnosis in fine needle aspiration cytology reports. But sometimes, florid granulomatous inflammation may be found in association with malignancy, which may mask the malignant component. We describe a case of Hodgkin's lymphoma that was associated with florid granulomatous reaction and was misdiagnosed and treated as tuberculosis for 6 months. This case highlights and emphasizes the importance of a careful microscopic evaluation of the lymph nodes with granulomatous reaction to look for any underlying malignant cells.

**Key words** - Granulomatous, lymphoma, Reed Sternberg cell

### **INTRODUCTION**

Granulomatous lymphadenitis is a frequent diagnosis on cytology material. Granulomas in lymph node can occur in a wide variety of conditions ranging from inflammation to malignancy. Rarely, a granulomatous response may be seen in association with lymphoma. When the malignant features are overt, this may not pose a problem. But in some cases, the granulomatous response may be florid and pose a diagnostic challenge.

### **CASE REPORT**

A 60-year-old man presented with cervical lymphadenopathy and low-grade fever since 6 months. Fine needle aspiration cytology done elsewhere was reported as granulomatous lymphadenitis suggestive of

tuberculosis. Patient received anti-tuberculosis treatment for 3 months, with no improvement. He presented to our institution 6 months after the initial diagnosis, and a repeat FNA was performed which showed granulomatous inflammation with lymphoid cells, plasma cells, histiocytes and aggregates of epithelioid cells. (Fig 1) No caseous necrosis or acid fast bacilli were seen. Few Reed-Sternberg cells with polylobated nuclei and prominent eosinophilic nucleoli were seen between the granulomas which were obscured by the granulomas. (Fig 2) A diagnosis of Hodgkin's lymphoma with florid granulomatous response was suggested and biopsy was requested for confirmation. A subsequent biopsy revealed lymphocyte predominant type of Classical Hodgkin's

lymphoma with exuberant granulomatous reaction. The Reed Sternberg cells stained positive with CD15 and CD30, confirming the diagnosis.

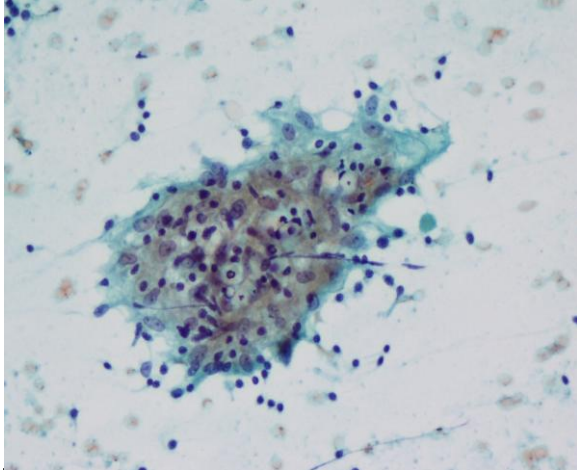


Fig 1- Shows non-caseating granuloma composed of epithelioid cells and lymphocytes PAP stain, 100X

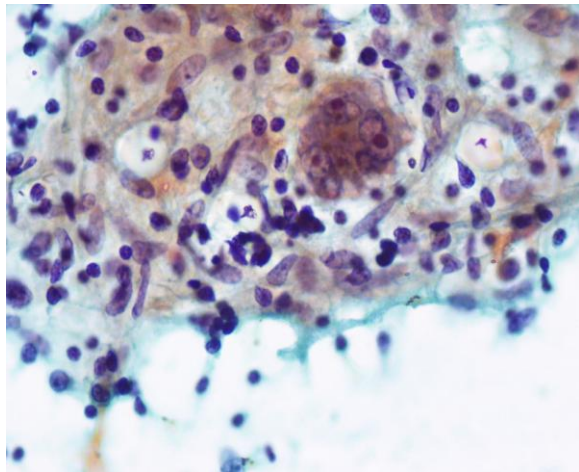


Fig 2- Shows occasional polylobated Reed Sternberg cells with prominent eosinophilic nucleoli among epithelioid granulomas PAP stain, 200X

## DISCUSSION

FNA cytology is a widely utilized diagnostic tool in the evaluation of lymphadenopathy. Granulomatous lymphadenitis is a frequent diagnosis in cytology samples. Granulomas can occur in a wide variety of infections and malignancies. Granulomatous lymphadenitis

can be necrotizing and non-necrotizing. Necrotising type of granulomatous lymphadenitis is most often seen in tuberculosis, but could also be seen with Cat scratch disease, Kikuchi lymphadenitis and Toxoplasmosis. Differential diagnosis for non-necrotising granulomatous lymphadenitis includes tuberculosis, sarcoidosis etc. Granulomas have been found in the lymph node in association with Hodgkins lymphoma, Non Hodgkins lymphoma, metastatic carcinomas, sarcomas and seminoma. [1-3] The diagnosis of a lymphoma may sometimes be obscured by the presence of extensive granulomatous inflammation which is well documented in the literature. This can be seen during initial presentation or following treatment or even during relapse. [4] Presence of florid granulomatous reaction can pose a diagnostic challenge particularly on cytologic materials. Hodgkin's disease in association with sarcoid like non-caseating granulomas has been described in literature. [5] Granulomas occur due to response to necrotic material or due to T-cell mediated hypersensitivity reaction to cell antigen. A prognostic significance of the granulomatous reaction in Hodgkin's lymphoma is not understood yet. Our patient presented with cervical lymphadenopathy was initially diagnosed as tuberculous lymphadenitis and failed to respond to anti-tuberculous treatment. On repeat fine needle aspiration cytology, a diagnosis of Hodgkin's lymphoma associated with exuberant granulomatous reaction was given. This case highlights the importance of a careful evaluation of the lymph nodes with non-necrotizing granuloma and to look for any large atypical cells that may suggest hidden malignancy that can be easily overlooked. Although, tuberculosis most commonly causes caseating granulomatous inflammation, it may also present with non-caseating granulomatous inflammation.

Patients not responding to anti-tuberculous treatment, a review of the pathological material searching for a possible hidden malignancy are recommended. A biopsy with immunohistochemical study may be required in some cases to confirm the diagnosis.

## REFERENCES

1. Brinker H: Sarcoid reactions in malignant tumours. *Cancer Treat Rev* 1986;13:147-56
2. Llombart A, Escudero JM. The incidence and significance of epithelioid and sarcoid-like cellular reaction in the stromata of malignant tumours. A morphological and experimental study. *Eur J Cancer* 1970;6:545-51
3. Khurana KK, Stanley MW, Powers CN, Pitman MB. Aspiration cytology of malignant neoplasms associated with granulomas and granuloma-like features: diagnostic dilemmas. *Cancer* 1998;84:84-91
4. de Hemricourt E, De Boeck K, Hilde F, Abib A, Kockx M, Vandevivere J, et al. Sarcoidosis and sarcoid-like reaction following Hodgkin's disease. Report of two cases. *Mol Imaging Biol* 2003;5:15-9
5. Paydas S, Yavuz S, Disel U, Zeren H, Hasturk S, Hanta I, et al. Granulomatous reaction after chemotherapy for Hodgkin's disease. *Leuk Res* 2002;26:967-70

How to cite this article: Pai K, Sharma S, Padmapriya J. Florid granulomatous response masking diagnosis of Hodgkin's disease in FNA cytology: a diagnostic challenge. *Int J Health Sci Res.* 2015; 5(2):468-470.

\*\*\*\*\*

### International Journal of Health Sciences & Research (IJHSR)

#### Publish your work in this journal

The International Journal of Health Sciences & Research is a multidisciplinary indexed open access double-blind peer-reviewed international journal that publishes original research articles from all areas of health sciences and allied branches. This monthly journal is characterised by rapid publication of reviews, original research and case reports across all the fields of health sciences. The details of journal are available on its official website ([www.ijhsr.org](http://www.ijhsr.org)).

Submit your manuscript by email: [editor.ijhsr@gmail.com](mailto:editor.ijhsr@gmail.com) OR [editor.ijhsr@yahoo.com](mailto:editor.ijhsr@yahoo.com)