



Case Report

## Quadrifurcation of Coeliac Trunk- A Case Report

Jaishree H<sup>1</sup>, Ashwini H<sup>2</sup>

<sup>1</sup>Tutor, Dept of Anatomy, ESIC Medical College, Gulbarga, Karnataka

<sup>2</sup>Assistant Professor, Dept of Anatomy, GIMS, Gulbarga, Karnataka, India.

Corresponding Author: Jaishree H

Received: 19/12/2014

Revised: 08/01/2015

Accepted: 14/01/2015

### ABSTRACT

An unusual variation showing quadrifurcation of coeliac trunk is seen in a male cadaver. Apart from 3 normal branches of coeliac trunk i.e. left gastric artery, common hepatic artery, splenic artery, the left inferior phrenic artery was also arising from coeliac trunk. The variation was observed during routine dissection of under graduate students in department of Anatomy, Bidar Institute of Medical Sciences, Bidar. Anatomical variations in the branching pattern of the coeliac trunk are of considerable importance in performing liver transplants, laparoscopic surgery, radiological abdominal interventions and penetrating injuries to the abdomen.

**Keywords:** Coeliac trunk; Left inferior phrenic artery; Left gastric artery; Splenic artery; Common hepatic artery.

### INTRODUCTION

The coeliac trunk is a short wide vessel about 1.25cm long and arises from aorta immediately below the aortic opening of diaphragm, opposite lower border of the twelfth thoracic vertebrae. The trunk of artery proceeds forwards and somewhat to the right and divides into three branches-common hepatic, splenic and left gastric artery. [1] The inferior phrenic arteries are paired vessels and are considered as first lateral branches from the abdominal aorta and supply the diaphragm. Both inferior phrenic arteries give superior suprarenal branches to corresponding suprarenal gland. [1]

Knowledge of vascular anomalies of coeliac trunk is important in handling patients

undergoing diagnostic angiography for gastrointestinal bleeding, coeliac axis compression syndrome and also prior to an operative procedure or transcatheter therapy, as vascular anomalies are usually asymptomatic. [2]

### CASE REPORT

During the routine dissection of undergraduate students in department of anatomy, Bidar institute of medical sciences, Bidar, we found a variation in branching pattern of coeliac trunk in a male cadaver. The coeliac trunk was arising from the ventral surface of the abdominal aorta at the level of the intervertebral disc between T12 and L1 vertebrae, 1 cm from the origin coeliac trunk showed quadrifurcation, it

gave 4 branches i.e. left gastric artery, common hepatic artery, splenic artery and an anomalous origin of left inferior phrenic artery from coeliac trunk. The left inferior phrenic artery passed upwards, laterally towards the left and supplied the diaphragm of left side. The course of other branches of coeliac trunk is normal. There was no variation in the origin of right inferior phrenic artery. The right inferior phrenic artery was arising from abdominal aorta.

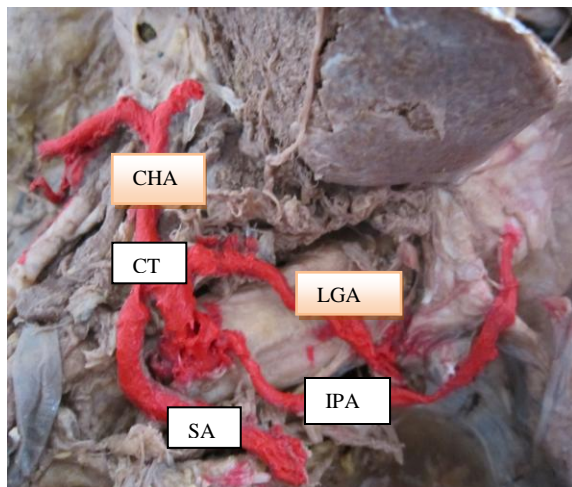


Figure 1 showing Quadrifurcation of celiac trunk. CT-coeliac trunk, LGA-left gastric artery, IPA- inferior phrenic artery, CHA-common hepatic artery.

## DISCUSSION

Previous studies on variations on arteries of the abdomen showed that 87.7% of the coeliac trunk exhibited the classical trifurcation and bifurcation accounted for 5.8–24.1%. Besides these variations, the coeliac trunk itself may be absent. The coeliac trunk may arise directly from the aorta. [3]

Peterella S et al reported that the left inferior phrenic artery was arising from the coeliac trunk in 21.35% cases. [4] The branching pattern of celiac trunk may vary from classical trifurcation to abnormal trifurcation, bifurcation, quadrifurcation or pentafurcation. [5] Gurushanthaiah et al reported that coeliac trunk gave rise to

common inferior phrenic artery that divided in to right inferior phrenic and left inferior phrenic artery. [6]

## CONCLUSION

In the present case the celiac trunk showed quadrifurcation. The branches are left gastric artery, common hepatic artery, splenic artery and left inferior phrenic artery. The knowledge of variation in the origin of inferior phrenic artery is important for the surgeons performing kidney transplants and surgeries involving suprarenal gland. [7]

Knowledge of anatomic variation of the branching pattern of coeliac trunk is essential while performing surgical, oncological, or interventional procedures including lymphadenectomy around hepato-spleno-mesenteric trunk, aortic replacement with reimplantation of the trunk, or chemoembolization of liver malignancies, which can cause significant morbidity because of the large visceral territory supplied by a single vessel. [8]

## REFERENCES

1. A.K.Dutta, Essentials of Anatomy, Thorax and Abdomen. 9<sup>th</sup> Edition 2010; p 154-159.
2. Piano DX, Ohtsuka A, Murakami T. Typology of abdominal arteries, with special references to inferior phrenic arteries and their esophageal branches. Acta Med Okayama 1988: 189-96.
3. Morettin LB, Baldwin-Price HK, Schreiber MH. Congenital absence of the celiac axis trunk. Am. J. Roentgenol. Radium Ther.Nucl. Med. 1965; 95: 727–730.
4. Peterella S, Rodriguez CFS et al. Origin of inferior phrenic arteries in the coeliac trunk. Int. J. Morphol 2006; 24 (2):275-278.
5. Chitra R. The clinically relevant variations of the celiac trunk. Singapore Med J 2010; 51(3): 216-9

6. Gurushanthaiah. M, K. Satheesh Naik et al. A Study on variation of Coeliac Trunk Branches in South Indian Population. Journal of Biomedical and Pharmaceutical Research 2013; 2(4): 62-65.
7. K. Krishna Chaitanya, HR. Sharada and D. Suseelamma. Pentafurcation of the Celiac Trunk.2012; Anat Physiol S7:001.
8. Losanoff JE, Millis JM, Harland RC, Testa G. Hepato-spleno-mesenteric trunk. J. Am. Coll. Surg. 2007; 204: 511.

How to cite this article: Jaishree H, Ashwini H. Quadrifurcation of coeliac trunk- a case report. Int J Health Sci Res. 2015; 5(2):407-409.

\*\*\*\*\*

**International Journal of Health Sciences & Research (IJHSR)**

**Publish your work in this journal**

The International Journal of Health Sciences & Research is a multidisciplinary indexed open access double-blind peer-reviewed international journal that publishes original research articles from all areas of health sciences and allied branches. This monthly journal is characterised by rapid publication of reviews, original research and case reports across all the fields of health sciences. The details of journal are available on its official website ([www.ijhsr.org](http://www.ijhsr.org)).

Submit your manuscript by email: [editor.ijhsr@gmail.com](mailto:editor.ijhsr@gmail.com) OR [editor.ijhsr@yahoo.com](mailto:editor.ijhsr@yahoo.com)